
The effects of growth hormone supplementation on left ventricular function with the development of congestive heart failure

Francis G. Spinale

Division of Cardiothoracic Surgery, Medical University of South Carolina, Charleston, SC, USA

(Ital Heart J 2000; 1 (Suppl 3): S34-S36)

Supported in part by NIH grant HL-45024 (FGS), and a Basic Grant from Pfizer (FGS). Dr. M. Murray from Pfizer is acknowledged for advice regarding the GH dosing protocol.

Address:

Francis G. Spinale,
MD, PhD

*Division of
Cardiothoracic Surgery
Room 625 Strom Thurmond
Research Building
Medical University of
South Carolina
114 Doughty Street
Charleston, SC 29425
USA*

Introduction

While the etiologies of congestive heart failure (CHF) are diverse, a common event in the progression of this disease process is left ventricular dilation and subsequent pump dysfunction. Past clinical and experimental studies have demonstrated that growth hormone (GH) can directly influence left ventricular myocardial structure and function. For example, GH supplementation in patients with cardiomyopathic disease resulted in an improvement in left ventricular pump function. GH supplementation may produce two potentially independent effects with developing CHF. First, GH treatment may induce a myocardial growth response which will alter left ventricular geometry and wall thickness, and consequently reduces left ventricular wall stress. The reduction in left ventricular wall stress, which may be induced by GH treatment with CHF, would be expected to yield a favorable effect on left ventricular pump function. Second, GH supplementation with developing CHF could potentially provide a direct beneficial effect on left ventricular myocyte contractile performance, which would be independent of changes in left ventricular geometry and loading conditions. The overall goal of the present study was to measure left ventricular function and geometry, as well as left ventricular myocyte contractile function following GH supplementation with developing CHF.

Methods

Instrumentation and experimental design. Twenty-eight Yorkshire pigs (25 kg, male, Hambone Farms, Orangeburg, SC, USA) were chronically instrumented with an aortic catheter (Model GPV, 9F, Access Technologies, Skokie, IL, USA) and a modified atrial pacemaker (8329, Medtronic, Inc., Minneapolis, MN, USA), as described previously¹⁻³. Pigs were randomly assigned to the following treatment groups: 1) chronic rapid pacing at 240 b/min for 3 weeks with no GH treatment (n = 10); 2) chronic rapid pacing and GH supplementation (n = 10); and 3) sham controls (n = 8). GH treatment by daily subcutaneous injection of 200 µg/kg recombinant porcine GH was started 3 days prior to the activation of the pacemaker and continued throughout the 21 day pacing protocol. The full description of methods has been published³. All animals were treated and cared for in accordance with the National Institutes of Health Guide for the Care and Use of Laboratory Animals (National Research Council, Washington, 1996).

Results

Left ventricular function and neurohormonal profiles with rapid pacing; effects of GH supplementation. Weekly indices of left ventricular function obtained with each week of chronic rapid pacing, with and without GH supplementation, are summarized in figure 1. Left ventricular end-dias-

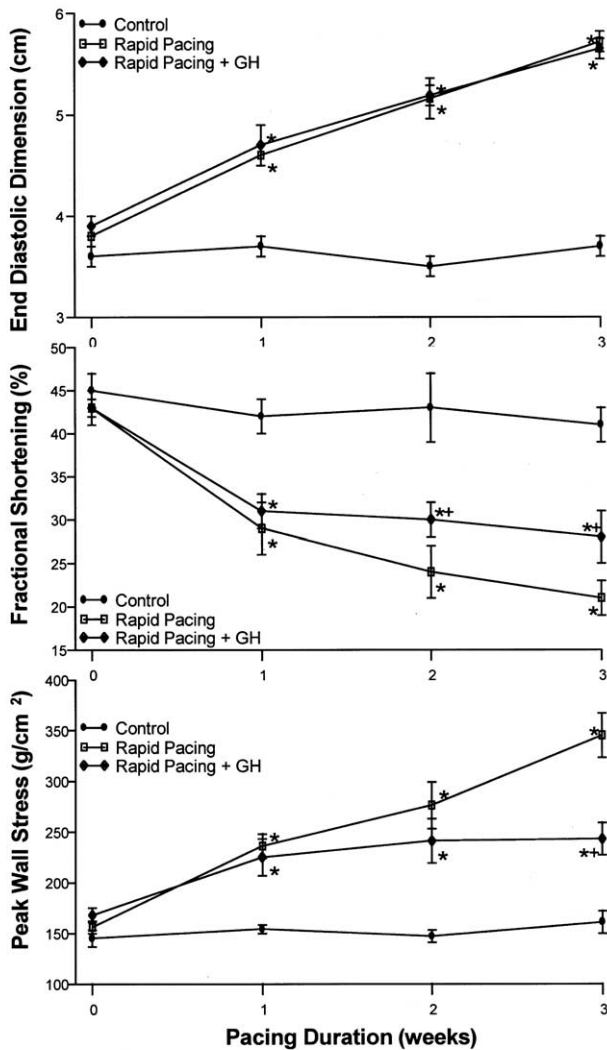


Figure 1. Left ventricular size and function was serially measured with each week of rapid pacing; with and without concomitant growth hormone treatment (rapid pacing + GH). All measurements were performed with the pacemaker deactivated and in the conscious state. Upper panel: after 1 week of rapid pacing, left ventricular end-diastolic dimension increased from baseline values in both rapid pacing groups. In the rapid pacing groups, left ventricular end-diastolic volume increased in a time dependent manner and was significantly increased with each week of pacing ($p < 0.05$). The degree of left ventricular dilation was similar in the untreated rapid pacing group and the rapid pacing and GH treated group. Middle panel: fractional shortening fell in a time dependent manner in the rapid pacing only group and the GH treated group. However, after 2 and 3 weeks of rapid pacing, left ventricular fractional shortening was higher in the GH treated group when compared to rapid pacing only values. Lower panel: after 1 week of rapid pacing, left ventricular peak wall stress increased from baseline values in the untreated and GH treated pigs ($p < 0.05$) and increased from this value after 3 weeks of rapid pacing ($p < 0.05$). After 1 and 2 weeks of rapid pacing and GH treatment, left ventricular peak wall stress was similar to untreated rapid pacing values. However, after 3 weeks of rapid pacing and GH treatment, left ventricular peak wall stress was reduced from untreated pacing values. * $p < 0.05$ vs control values; + $p < 0.05$ vs respective rapid pacing only values.

tolic dimension and peak wall stress increased, and left ventricular fractional shortening decreased in a time dependent manner in the untreated pacing group. Following 2 and 3 weeks of GH treatment, left ventricular fractional shortening was significantly higher than untreated rapid pacing values. After 3 weeks of rapid pacing, left ventricular peak wall stress was 35% lower in

the GH treated group when compared to the untreated group.

In the GH treated rapid pacing group, left ventricular end-diastolic wall thickness was similar to controls and was associated with a 36% increase in the left ventricular mass/body weight ratio. The body weight in the GH treated group was increased by 33% when compared to time matched control pigs.

Left ventricular myocardial structure and composition. Left ventricular myocyte cross-sectional area decreased from control values in the rapid pacing group (201 ± 3 vs $180 \pm 3 \mu\text{m}^2$, $p < 0.05$, respectively). In the GH treated rapid pacing group, myocyte cross-sectional area was significantly increased from control and rapid pacing only values ($267 \pm 4 \mu\text{m}^2$, $p < 0.05$).

Left ventricular membrane preparations with identical protein concentrations were analyzed from each treatment group, and the relative abundance of sarcoplasmic reticulum (SR) Ca^{2+} -ATPase was determined with respect to the control signal (Fig. 2). In the rapid pacing group, the relative abundance of SR Ca^{2+} -ATPase was reduced from control levels, but was normalized in the GH treated rapid pacing group.

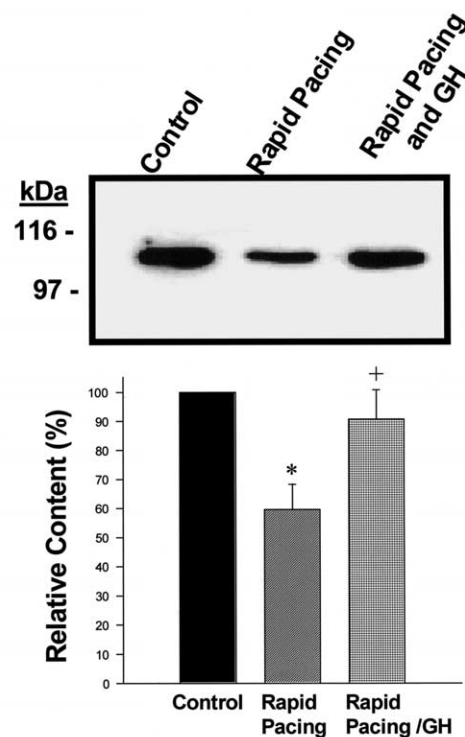


Figure 2. Representative immunoblot for sarcoplasmic reticulum (SR) Ca^{2+} -ATPase in control left ventricular myocardial membrane preparations (5 μg), following chronic rapid pacing, and rapid pacing with concomitant growth hormone (GH) treatment. The positive signal for SR Ca^{2+} -ATPase was consistent for this protein and anti-sera. The signal was digitized and quantitated with respect to controls and this analysis is shown in the lower portion of the figure. The relative abundance of SR Ca^{2+} -ATPase was reduced to $72 \pm 3\%$ of control levels with pacing-induced congestive heart failure ($p < 0.05$) but was normalized with concomitant GH treatment. * $p < 0.05$ vs control; + $p < 0.05$ vs rapid pacing.

Discussion

While a clinical study as well as experimental reports suggest that GH supplementation may be beneficial during the development of CHF, contributory mechanisms for these effects are unclear. Accordingly, the present study examined the direct effects of short-term GH supplementation on left ventricular myocyte contractile performance and myocardial structure in an animal model of pacing-induced CHF. The important findings of the present study are based upon the underlying mechanisms for improved left ventricular function with GH treatment. First, GH treatment with pacing CHF increased left ventricular wall thickness, which in turn reduced left ventricular peak wall stress. This favorable effect on left ventricular wall stress patterns was further demonstrated by an increased left ventricular mass/volume ratio with GH treatment. Second, GH supplementation with CHF improved the capacity of the left ventricular myocyte to respond to an inotropic stimulus. Third, the structural basis for the effects of GH supplementation included increased left ventricular myocyte volumes, protection from left ventricular myocyte loss, increased capillary density, and a normalization of SR Ca²⁺-ATPase. Thus, the improved left ventricular pump function which occurred with GH supplementation in this model of CHF was likely due to favorable effects on left ventricular myocardial remodeling and contractile processes.

Left ventricular function and contractility with growth hormone supplementation. To our knowledge, this is the first study which has examined the effects of GH supplementation on left ventricular structure and function in a large animal model of CHF. In the present study, GH supplementation with chronic rapid pacing resulted in improved left ventricular pump function, which was accompanied by increased left ventricular end-diastolic wall thickness, and therefore, reduced left ventricular wall stress. GH supplementation instituted during the progression of pacing CHF increased myocardial capillary density, which may have improved oxygen delivery/consumption with pacing CHF³.

GH treatment with pacing CHF was not accompanied by a significant improvement in steady-state myocyte contractility. However, with GH supplementation, myocyte contractile function was significantly improved

from CHF values in the presence of the α -receptor agonist, isoproterenol³. In studies of human myocardium with end-stage CHF, abnormalities in Ca²⁺ homeostatic mechanisms have been identified. The present study demonstrated that the relative abundance of SR Ca²⁺-ATPase was reduced with the development of pacing-induced CHF. These changes in SR Ca²⁺-ATPase with pacing CHF likely contributed to the reduction in myocyte function and inotropic response. GH supplementation with chronic rapid pacing normalized SR Ca²⁺-ATPase and is a potential contributory mechanism for the improved left ventricular myocyte inotropic capacity with GH supplementation.

While the majority of studies have demonstrated that GH supplementation influences left ventricular pump function, there have been past reports which have demonstrated that this treatment modality has neutral effects. In the present study, recombinant porcine GH was used in pigs during chronic rapid pacing and resulted in a significant myocardial hypertrophic response. Conditions of chronic GH excess, such as acromegaly, are associated with severe left ventricular hypertrophy and the development of pump dysfunction. The present study instituted GH supplementation for a 3 week period, and therefore the long-term effects of chronic GH supplementation in the setting of CHF remain to be established. Nevertheless, short-term GH supplementation in a model of developing CHF, at a dose which significantly increased basal levels of insulin-like growth factor-I, increased left ventricular pump function and improved myocyte inotropic responsiveness. These results suggest that GH supplementation may be a useful adjunctive therapy in the setting of developing CHF.

References

1. Spinale FG, Holzgrefe HH, Mukherjee R, et al. Angiotensin converting enzyme inhibition and the progression of congestive cardiomyopathy: effects on left ventricular and myocyte structure and function. *Circulation* 1995; 92: 562-8.
2. Tomita M, Spinale FG, Crawford FA, Zile MR. Changes in left ventricular volume, mass and function during development and regression of supraventricular tachycardia induced cardiomyopathy: disparity between recovery of systolic vs diastolic function. *Circulation* 1991; 83: 635-44.
3. Houck WV, Pan LC, Kribbs SB, et al. The effects of growth hormone supplementation on left ventricular and myocyte function with the development of congestive heart failure. *Circulation* 1999; 100: 2003-9.