

# Atlas of Electrocardiography

Z.F

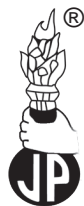# Atlas of Electrocardiography

K. Wang MD, FACC

Clinical Professor of Medicine  
Cardiovascular Division  
Department of Medicine  
University of Minnesota  
Minneapolis, Minnesota, USA

Foreword

(Late) Henry J.L. Marriott MD, FACP, FACC

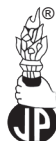

---

**JAYPEE BROTHERS MEDICAL PUBLISHERS (P) LTD**

New Delhi • Panama City • London • Philadelphia (USA)





**Jaypee Brothers Medical Publishers (P) Ltd.**

#### **Headquarters**

Jaypee Brothers Medical Publishers (P) Ltd  
4838/24, Ansari Road, Daryaganj  
New Delhi 110 002, India  
Phone: +91-11-43574357  
Fax: +91-11-43574314  
**Email: jaypee@jaypeebrothers.com**

#### **Overseas Offices**

J.P. Medical Ltd.,  
83 Victoria Street, London  
SW1H 0HW (UK)  
Phone: +44-2031708910  
Fax: +02-03-0086180  
**Email: info@jpmedpub.com**

Jaypee-Highlights Medical Publishers Inc.  
City of Knowledge, Bld. 237, Clayton  
Panama City, Panama  
Phone: +507-301-0496  
Fax: +507- 301-0499  
**Email: cservice@jphmedical.com**

Jaypee Brothers Medical Publishers (P) Ltd  
17/1-B Babar Road, Block-B, Shaymali  
Mohammadpur, Dhaka-1207  
Bangladesh  
Mobile: +08801912003485  
**Email: jaypeedhaka@gmail.com**

Jaypee Brothers Medical Publishers (P) Ltd  
Shorakhute, Kathmandu  
Nepal  
Phone: +00977-9841528578  
**Email: jaypee.nepal@gmail.com**

Website: [www.jaypeebrothers.com](http://www.jaypeebrothers.com)  
Website: [www.jaypeedigital.com](http://www.jaypeedigital.com)

© 2013, Jaypee Brothers Medical Publishers

All rights reserved. No part of this book may be reproduced in any form or by any means without the prior permission of the publisher.

**Inquiries for bulk sales may be solicited at:** [jaypee@jaypeebrothers.com](mailto:jaypee@jaypeebrothers.com)

This book has been published in good faith that the contents provided by the author contained herein are original, and is intended for educational purposes only. While every effort is made to ensure accuracy of information, the publisher and the author specifically disclaim any damage, liability, or loss incurred, directly or indirectly, from the use or application of any of the contents of this work. If not specifically stated, all figures and tables are courtesy of the author. Where appropriate, the readers should consult with a specialist or contact the manufacturer of the drug or device.

*Atlas of Electrocardiography*

*First Edition: 2013*

ISBN: 978-93-5090-209-7

*Printed in India*

# FOREWORD

---

Everything seems to go through phases, and the popularity of electrocardiography is no exception. Half a century ago, the ECG was arguably the most useful and most often employed single test in cardiology. When lecturers were graduating from  $3.25 \times 4$  inch glass lantern slides to the slicker 35 mm transparencies, electrocardiography still held sway. But then computers took their toll by introducing "computerized interpretation" which, with all its sound and fury, seemed a gigantic forward leap—as though the responsibility for interpretation could be handed over to the wonder-machinery of computers! Probably the only tangible result of this partial surrender, however, is a widespread loss of interpretative skills on the part of young cardiologists. Now the pendulum is swinging back and the urge to replace computers with thoughtful and more accurate human interpretations is surfacing.

This therefore seems an ideal time to present a new, informative text on the subject. While not pretending to be a textbook, this work covers all of the entities that are likely to be encountered in a clinical practice and presents them in highly readable form with clear and copious illustrations; and nowhere is the tenet that a picture is worth a thousand words more applicable than in electrocardiography.

The text is sparse, but, reader-friendly and the illustrations are of exceptional quality. More an atlas than a textbook, it nevertheless offers a remarkably comprehensive overview of the subject; and I believe that beginners and veterans alike will have an enjoyable and profitable journey through its pages.

**(Late) Henry J.L. Marriott** MD, FACP, FACC

*Former* Director of Clinical Research and Education, Rogers Heart Foundation, St. Petersburg, Florida, USA  
Clinical Professor of Medicine (Cardiology), University of South Florida College of Medicine, Tampa, Florida, USA  
Clinical Professor of Pediatrics (Cardiology), University of Florida College of Medicine, Gainesville, Florida, USA  
Clinical Professor of Medicine (Cardiology), Emory University College of Medicine, Atlanta, Georgia, USA

# PREFACE

---

Welcome to the world of electrocardiography!

It is rather remarkable that when the cardiac muscle undergoes depolarization and repolarization, these electrical events can be recorded from the body surface; hence the birth of electrocardiography. And this ECG amazingly provides a wealth of clinically useful information as exhibited in this atlas.

Thus, ECG is a valuable diagnostic tool that we use in daily clinical practice. Therefore, for quality patient care, it is important that we become proficient in its interpretation.

In this atlas, after brief presentations on the basic aspects of ECG, I have compiled typical examples of nearly all ECG entities that we commonly encounter. The primary intent is to help you with pattern recognition, point out salient features, and to help you understand the logic behind the ECG manifestations.

I hope you find this atlas to be a useful resource. I am grateful to (Late) Dr. Henry J. L. Marriott and to my daughter, Leah, for their editorial assistance. I also deeply appreciate the secretarial work of Rosie Robinson, Jennifer Walker, Michelle Pagel, Ester Almeida and Marissa Weatherhead, who graciously put up with my endless revisions.

**K. Wang**

# ACKNOWLEDGMENTS

---

I am grateful to (Late) Dr. Henry J. L. Marriott and my daughter, Leah, for their editorial assistance and Dr. Marriott's foreword to the book (He subsequently passed away. We lost a one-of-a-kind, true giant in the field of electrocardiography). I also deeply appreciate Jaypee Brothers Medical Publishers (P) Ltd. New Delhi, India, for undertaking the difficult task of publishing this atlas so that the knowledge of electrocardiography will be propagated as widely as possible, which will certainly translate into better patient care.

# CONTENTS

---

1. The Mechanics of Recording the ECG	1
2. Vectorial Concept of the QRS	2
3. Orientation of the ECG Leads	3
4. Systematic Approach to the Interpretation of ECG (with normal values in parenthesis)	4
5. ECG Waves, Intervals and Segments	4
6. Guide for Heart Rate Estimation	5
7. Proper Labeling of the Component Waves of the Ventricular Depolarization	6
8. QRS Axis (Mean axis of the QRS projected on the frontal plane)	7
9. Glossary of Cardiac Rhythms	8
10. A Normal Tracing	18
11. P Wave Abnormalities	20
12. Ventricular Hypertrophy, Left, Right and Biventricular	21
13. Intraventricular Conduction Defect	
• <i>Bundle Branch Block</i>	30
• <i>Fascicular Block</i>	33
14. AV Block	37
15. Myocardial Infarction	50
16. Simple Electrophysiologic Characteristics of the Conduction Systems	92
17. P-QRS Relationships in Arrhythmias	
• <i>Reciprocal (Echo) Beats</i>	99
• <i>Ventricular Capture Beats</i>	101
• <i>Fusion Beats</i>	101
• <i>AV Dissociation</i>	102
• <i>Ventriculophasic Sinus Arrhythmia</i>	109
• <i>Retrograde Conduction to Atria</i>	111
18. Atrial Premature Beats	112
19. Atrial Tachycardia	116
20. Role of the A-V Node in Various Supraventricular Arrhythmias and Its Implication in Their Treatment	118
21. Effects of Adenosine in Various Supraventricular Tachyarrhythmias	119
22. Supraventricular Tachycardia (SVT)	120

23. Atrial Fibrillation	123
24. Atrial Flutter	129
25. Multifocal Atrial Tachycardia	146
26. Ventricular Premature Beats (VPBs or PVCs)	150
27. Usefulness of Ventricular Premature Beats	154
28. Aberrant Conduction	161
29. Ventricular Tachycardia with	166
30. Electrolyte Problems	171
31. Sinus Node Dysfunction	186
32. Electronic Pacemaker	190
33. Stress Electrocardiography	196
34. Atrial Repolarization (Ta) Wave	197
35. Preexcitation (WPW) Syndrome	200
36. Concealed Conduction	214
37. ST-Segment Elevation in Conditions Other than Myocardial Infarction	
• <i>Normal ST-Segment Elevation in Right Precordial Leads</i>	222
• <i>Early Repolarization Pattern as a Normal Variant</i>	225
• <i>ST Elevation of "The Other" Normal Variant</i>	226
• <i>Left Ventricular Hypertrophy</i>	23
• <i>Left Bundle Branch Block</i>	81
• <i>Pericarditis</i>	227
• <i>Prinzmetal's Angina</i>	228
• <i>Brugada Syndrome</i>	229
• <i>Pulmonary Embolism</i>	230
• <i>Stress Cardiomyopathy</i>	231
• <i>Cardioversion</i>	232
• <i>Hyperkalemia</i>	177
• <i>'Metabolic' ST Elevation</i>	233
38. Miscellaneous:	
• <i>Accelerated AV Conduction</i>	234
• <i>Acute Cor Pulmonale</i>	235
• <i>Atrial Septal Defect, Primum and Secundum</i>	237
• <i>Bidirectional Tachycardia</i>	239
• <i>Brugada Syndrome</i>	229
• <i>Cardioinhibitory Response</i>	240
• <i>Dextrocardia</i>	241
• <i>Digitalis Effect on the ST-Segment</i>	242
• <i>Duchenne Muscular Dystrophy</i>	243

• <i>Early Transition</i>	244
• <i>Ebstein's Anomaly</i>	245
• <i>Electrical Alternans</i>	246
• <i>Hypertrophic Cardiomyopathy</i>	250
• <i>Hypothermia</i>	251
• <i>Late Transition</i>	253
• <i>Long QT Interval</i>	254
• <i>Low QRS Voltage</i>	255
• <i>Memory T-Wave</i>	256
• <i>Mitral Stenosis</i>	257
• <i>Nonspecific ST-T Changes</i>	258
• <i>Poor R-Wave Progression</i>	259
• <i>Stress Cardiomyopathy</i>	260
• <i>Swan-Ganz Catheterization Causing High Grade AV Block in a Patient with LBBB</i>	261
• <i>T-Wave Alternans</i>	262
• <i>Transplanted Heart</i>	263
• <i>Tricyclic Overdose</i>	264
• <i>U Waves</i>	265
• <i>U Waves Mimicking P Waves</i>	266
39. <i>Artifacts</i>	267
40. <i>Differential Diagnosis of:</i>	
• <i>Regular Narrow-QRS Tachycardia</i>	273
• <i>Regular Narrow-QRS Bradycardia</i>	282
• <i>Pauses</i>	284
• <i>Tall R Waves in the Right Precordial Lead</i>	285
• <i>Bigeminal Rhythm (Paired QRS Complexes)</i>	292
• <i>Changing QRS Axis or Morphology</i>	294
• <i>ST-Segment Elevation in V1-3</i>	296
41. <i>Addendum</i>	
• <i>How to Make an Interpretation of Arrhythmia Easy, Correct, Convincing and Clinically Relevant?</i>	298
• <i>A Little Rhythm Strip that Told the Whole Story</i>	300
<i>Index</i>	301

## The Mechanics of Recording the ECG

A standard electrocardiogram (ECG) consists of 12 leads (hence it is also called a 12 lead ECG). These 12 leads are made of 6 limb leads (leads are attached to the wrists and ankles) and 6 precordial leads ( $V_{1-6}$ ). Limb leads are bipolar (leads I, II and III) or unipolar (leads aVR, aVL, and aVF).

Lead I = VL minus VR	where	V = potential
Lead II = VF minus VR		R = right arm
Lead III = VF minus VL		L = left arm
		F = left leg

If leads from each of the three extremities are connected through equal resistance to a central terminal, the potential of the central terminal becomes almost zero. By pairing the central terminal with an exploring electrode placed on any part of the body, a lead is obtained which records the potential variations of the exploring electrode only. This type of lead is called a unipolar lead and is designated by the letter V.

Unipolar leads recorded from the right arm, left arm, and left leg are called unipolar limb leads (VR, VL and VF). The deflections recorded by the unipolar extremity leads are small. By breaking the connection between the central terminal and the extremity whose potential variations are to be recorded, the amplitude of the deflections can be augmented by 1 1/2 times, hence they are called augmented unipolar limb leads (aVR, aVL, and aVF).

All precordial leads are unipolar leads. They register potential differences between the central terminal and the exploring electrode from various positions on the chest wall.

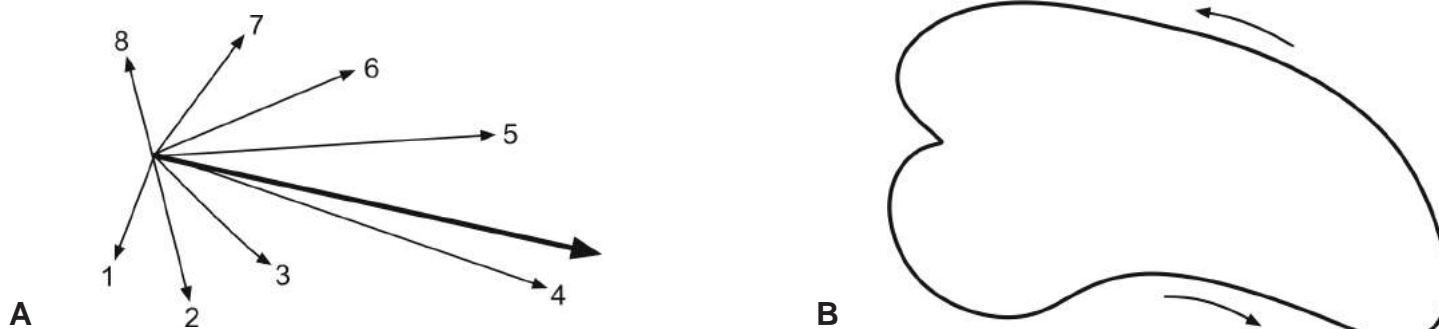
The ECG machine is so designed that an electrical force directed towards a unipolar lead or the positive pole of bipolar leads will register a positive deflection whereas an electrical force directed away from the lead will register a negative deflection.

A given electrical event will register different wave forms in different leads because each of these leads faces the heart from a different angle.

Customarily, the ECG is recorded with paper speed of 25 mm/sec (1 mm, one small box, is equivalent to 0.04 s; 5 mm, one big box, is equivalent to 0.2 s) and is calibrated at 10 mm/mV. A calibration mark is present at the end or the beginning of the tracing. The first half of the calibration mark is for the limb leads and the latter half is for the precordial leads. A normal, half or double standard calibration in either the limb or precordial leads will be reflected in this mark.

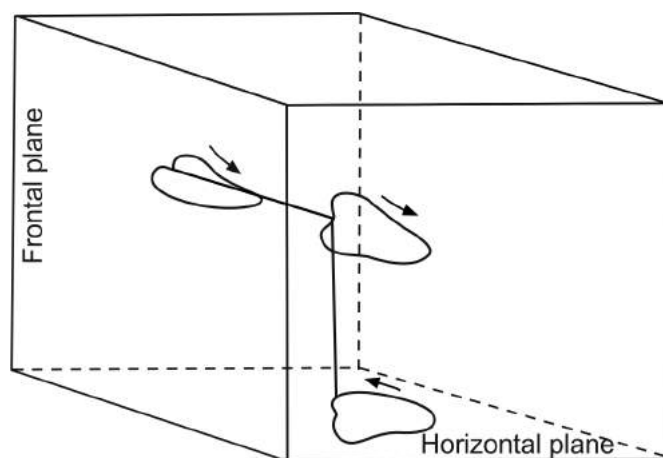


## Vectorial Concept of the QRS

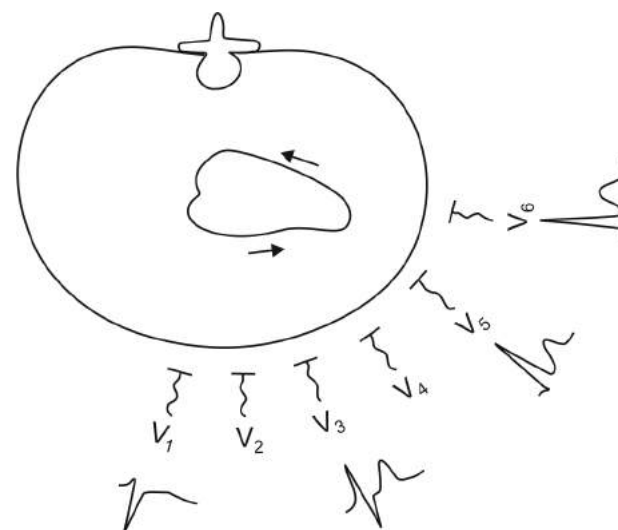


## Genesis of the Vector Loop

When the ventricular myocardium undergoes depolarization, it does not happen instantaneously, but normally takes 0.06–0.10 s. In the example shown in (A), the mean vector of the electrical forces during the first 0.01 s is represented by arrow 1, during the next 0.01s by arrow 2, and so on. The mean vector of the entire depolarization event is represented by the thick arrow. The “mean QRS axis” that we talk about when interpreting an ECG refers to the direction of this mean vector projected on the frontal plane. If the arrow heads are joined by a continuous line, a vector loop is formed (B). This vector loop is oriented three-dimensionally in space (spatial loop ).

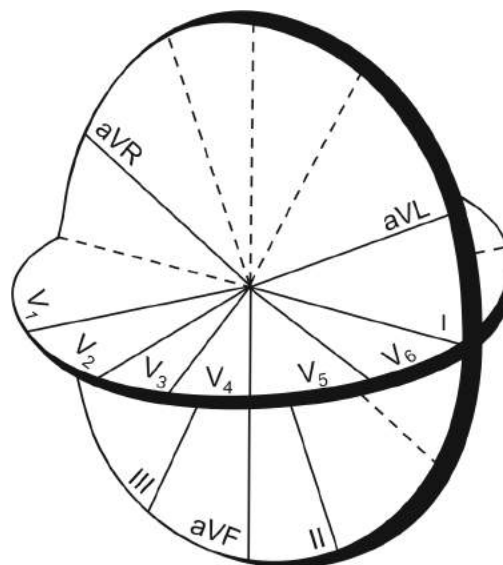


Diagrams showing the projection of the spatial vector loop on the frontal plane and horizontal plane. The limb leads only concern the vector loop projected on the frontal plane and the precordial leads only concern the vector loop projected on the horizontal plane.

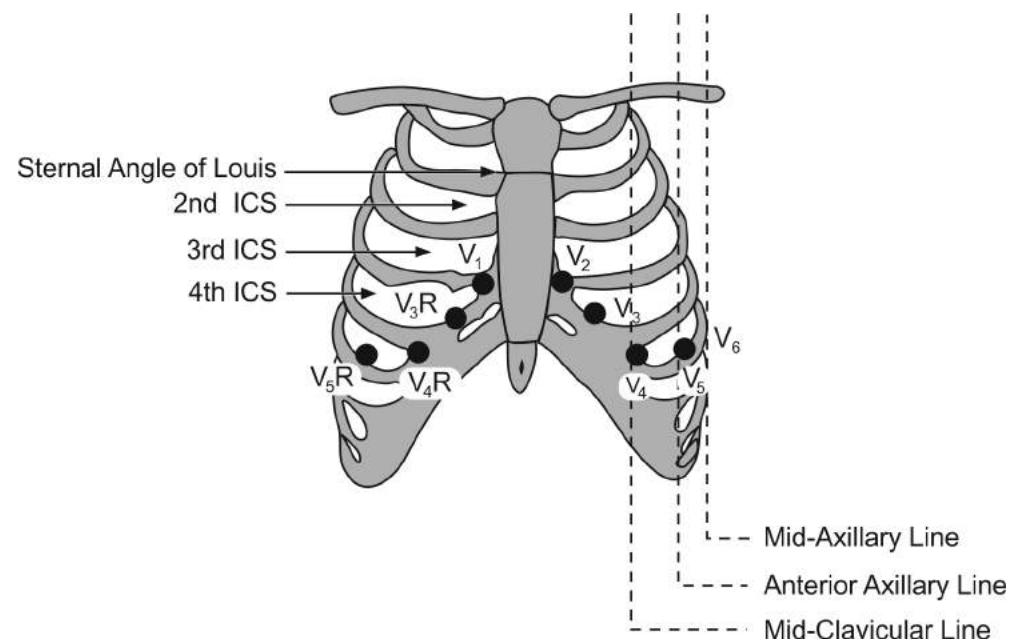
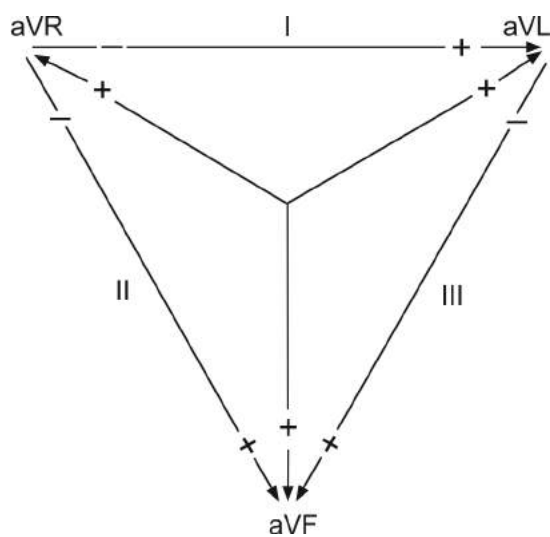


Schematic representation of the horizontal section of the chest. It shows the relationship between the precordial leads and the spatial vector loop projected on the horizontal plane. An electrical force directed towards a given lead registers a positive deflection and away from the lead registers a negative deflection. The waveform of the ventricular depolarization (QRS) in each of the precordial leads is different because each lead faces the loop from a different angle.

## Orientation of the ECG Leads



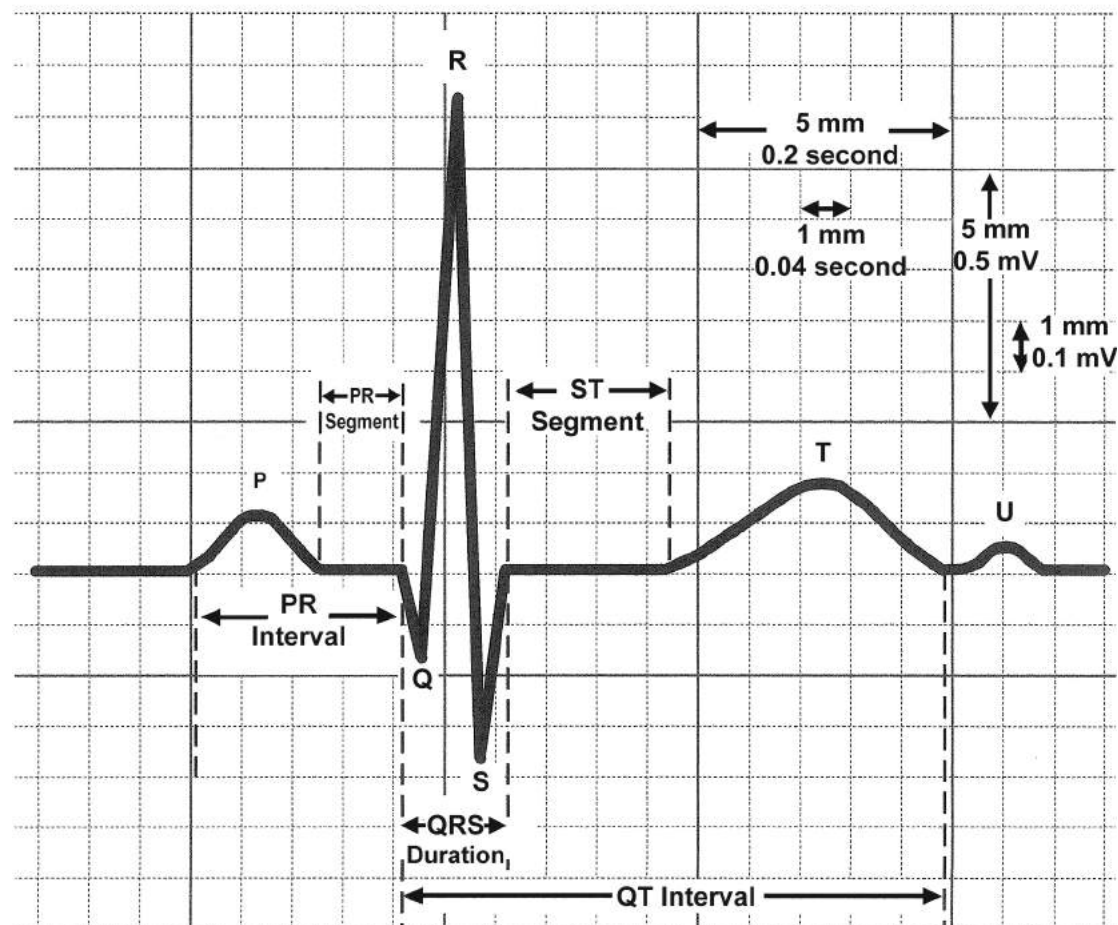
## Einthoven's Triangle



## Systematic Approach to the Interpretation of ECG (with normal values in parenthesis)

- **Rhythm**
  - Determine regularity
  - Identify atrial activities
  - Determine P - QRS relationship
- **Rate** (50-100/min)
- **P wave morphology**
- **P-R interval** (120-200 msec)
- **QRS**
  - Morphology
  - Duration < 100 msec)
  - Voltage
  - Axis ( $-30^{\circ}$  to  $90^{\circ}$ )
- **ST segment**
- **T wave**
- **U wave**
- **Q-T interval**

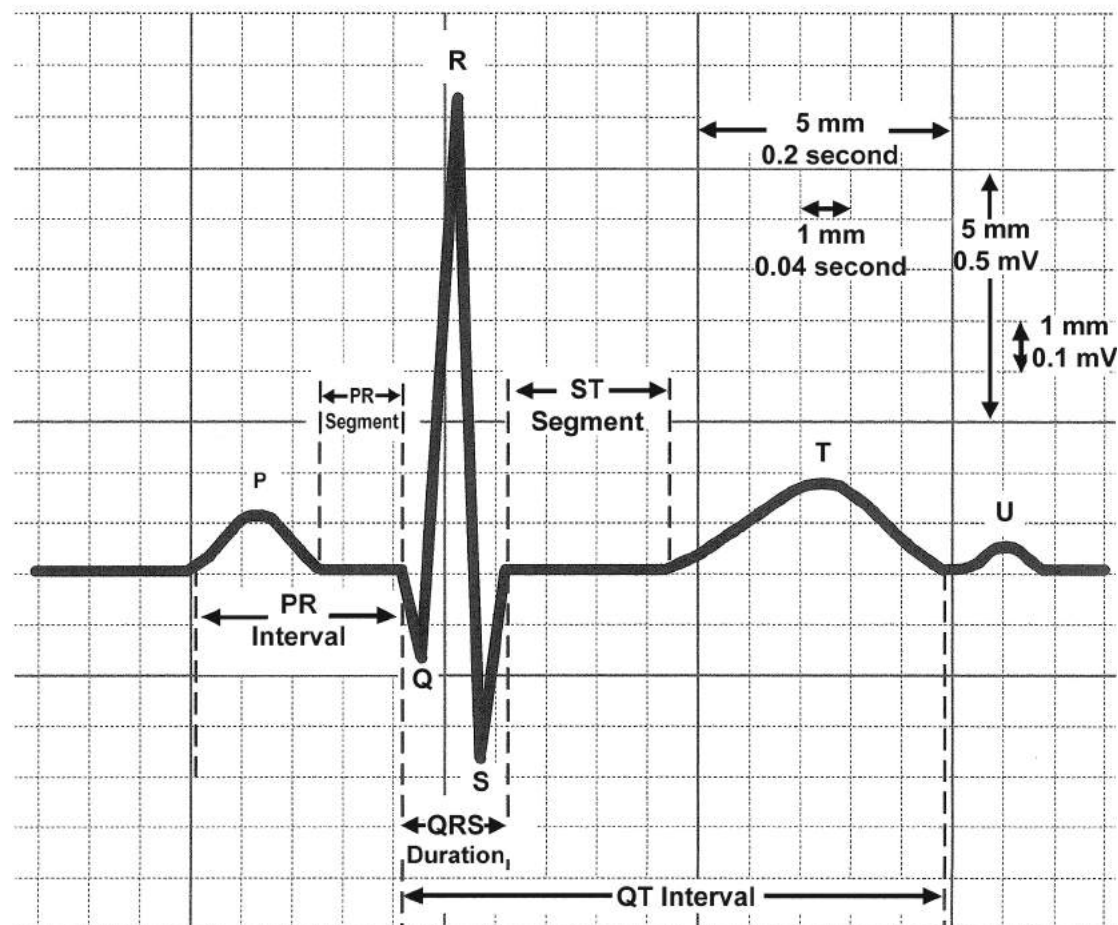
## ECG Waves, Intervals & Segments



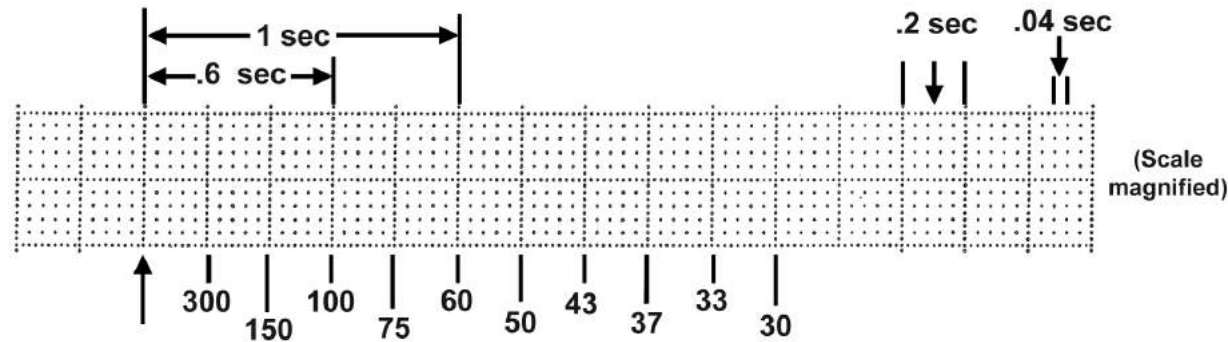
## Systematic Approach to the Interpretation of ECG (with normal values in parenthesis)

- **Rhythm**
  - Determine regularity
  - Identify atrial activities
  - Determine P - QRS relationship
- **Rate** (50-100/min)
- **P wave morphology**
- **P-R interval** (120-200 msec)
- **QRS**
  - Morphology
  - Duration < 100 msec)
  - Voltage
  - Axis ( $-30^{\circ}$  to  $90^{\circ}$ )
- **ST segment**
- **T wave**
- **U wave**
- **Q-T interval**

## ECG Waves, Intervals & Segments

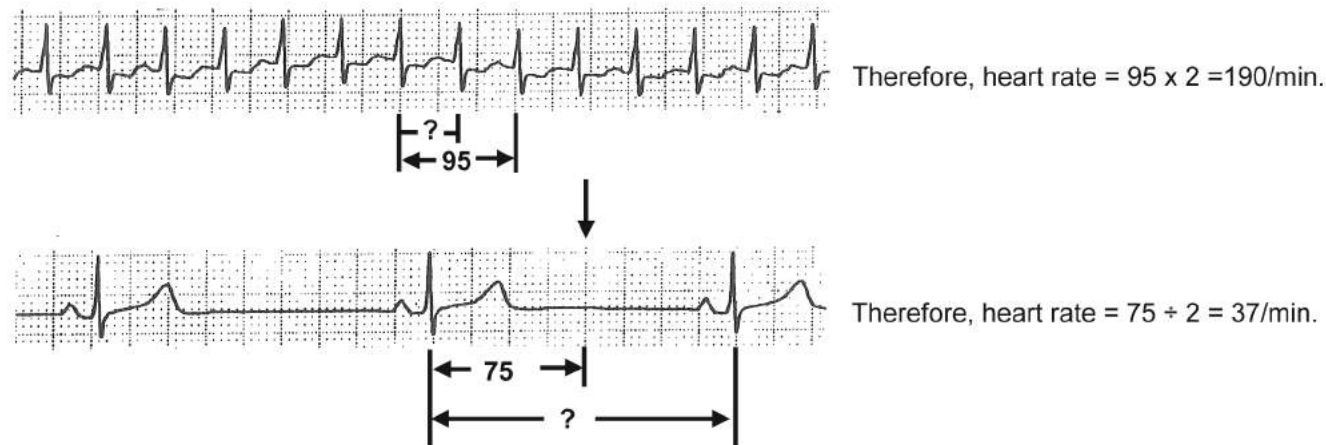


## Guide for Heart Rate Estimation



In a regular rhythm, find a QRS that occurs on a heavy line, (e.g.  $\uparrow$ ). The numbers in the above diagram indicate the heart rates if the next QRS occurs on the corresponding heavy lines. 300, 150, 100, 75, 60 and 50 are convenient numbers which are easy to remember. Or, the heart rate is  $300 \div$  number of large boxes between QRS complexes since one large box is 1/300 minute.

When the heart rate is fast and difficult to estimate, estimate the heart rate using two RR intervals as though the second QRS occurred at the end of the 2nd R-R interval. Then, double the number as illustrated below. In this way, a more accurate estimate can be achieved. If the heart rate is very slow and difficult to estimate, find the midpoint ( $\downarrow$ ) between the RR interval and estimate the heart rate as though the second QRS occurred at that point. Then, halve the number as illustrated below.





## Proper Labeling of the Component Waves of the Ventricular Depolarization

**Q:** The initial deflection, if it is negative.

**R:** The first positive deflection, whether or not it is preceded by a Q wave.

**S:** A negative deflection following an R wave.

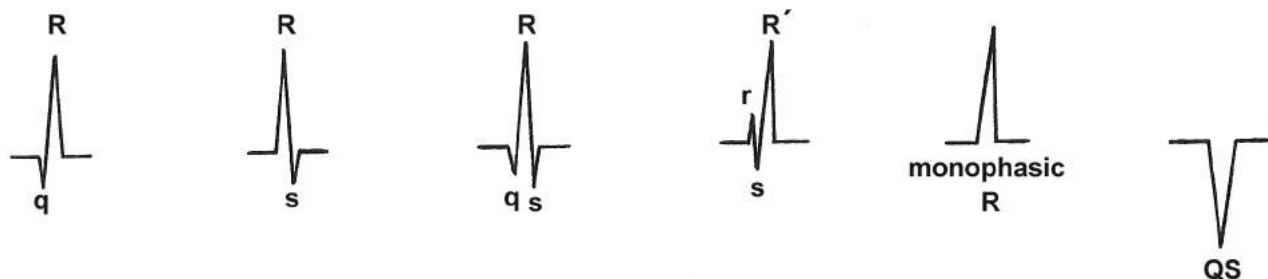
**R':** The second positive deflection.

**S':** A negative deflection after an S wave.

**QS:** When the complex consists of one negative wave only.

**Monophasic R wave:** When the complex consists of one R wave only.

Capital or lower case letters are used to signify the relative size of the component waves, e.g. qR, Rs, rS, qRs, etc.

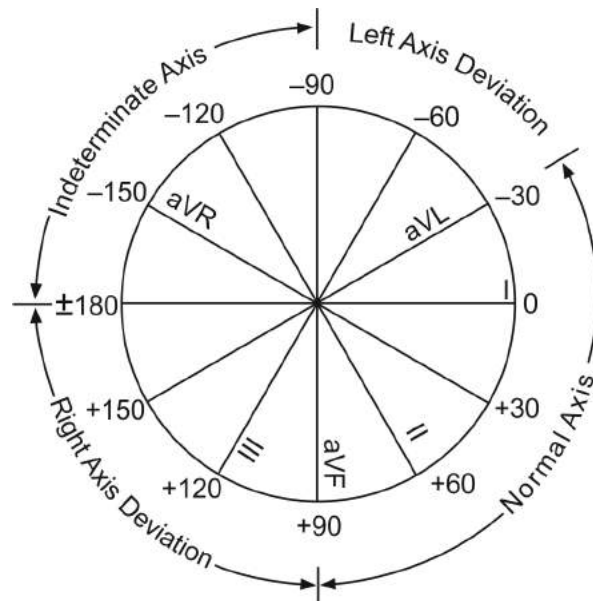


Even though only the third complex in the examples shown above is truly a QRS, this symbol is used to refer to the ventricular depolarization wave generically. So, when one asks "what did the QRS look like?" one is really asking, "What did the ventricular depolarization wave look like?"

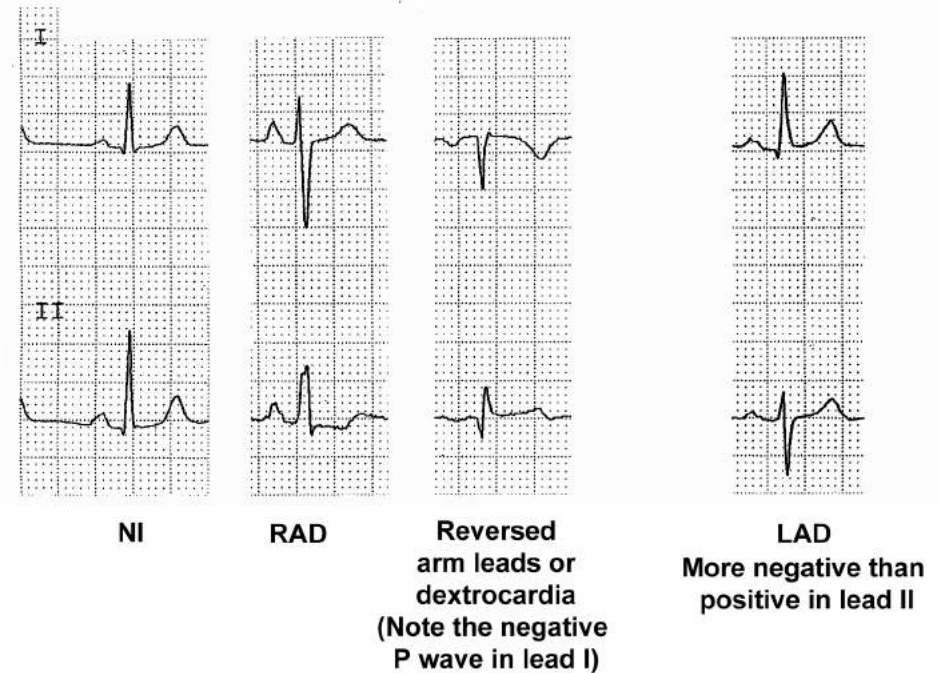
## QRS Axis

### (Mean axis of the QRS projected on the frontal plane)

The normal range for the mean QRS axis is from  $-30^{\circ}$  to  $90^{\circ}$ . Therefore when one wants to know whether the mean QRS axis is normal, deviated to the right, or deviated to the left, one only needs to look at leads I and II. If the QRS is more positive in both leads I and II, the axis is normal. If the QRS is more negative in lead I, it is right axis deviation. If the QRS is more negative in lead II while it is more positive in lead I, it is left axis deviation.



The frontal plane hexaxial reference system and the respective ranges of axis deviation.



- Right axis deviation (RAD) should make one first think of RVH and look for other features of RVH in the precordial leads. Other causes of RAD are lateral MI (Qr pattern,  $\nabla$ , while in RVH it is rS pattern,  $\nabla$ ), posterior fascicular block, etc.
- Left axis deviation made of rS in lead II is practically due to left anterior fascicular block.

## Glossary of Cardiac Rhythms

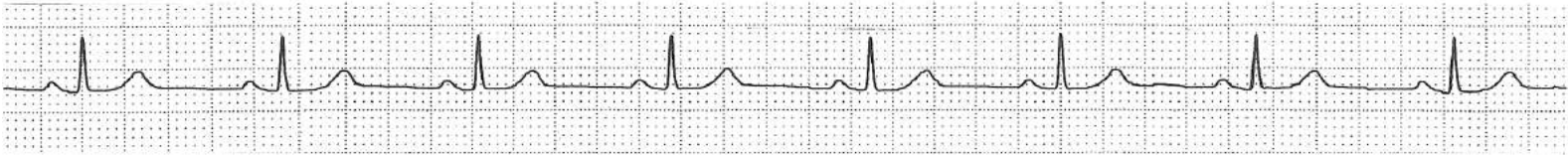
Cardiac rhythms are named after the locus of their origin. It is important to realize that while the atria are in one rhythm, the ventricles may be in another rhythm. AV block or physiologic refractoriness of the conduction system may cause this: e.g. while the atria are in normal sinus rhythm, atrial fibrillation or atrial flutter, the ventricles may be driven by an AV junctional escape rhythm during complete AV block.

### A. Rhythms originating from the sinus node:

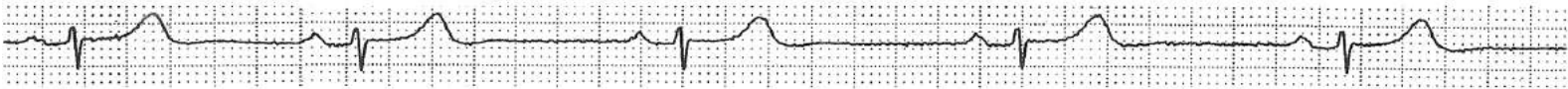
- a. **Normal sinus rhythm:** This rhythm originates from the sinus node and the rate ranges from 50 to 100/min. It is the most common and natural rhythm.
- b. **Sinus bradycardia:** This rhythm originates from the sinus node, but the rate is slower than 50/min. This rhythm is not unusual during sleep or whenever vagal tone is increased.
- c. **Sinus tachycardia:** This rhythm originates from the sinus node but the rate is faster than 100/min. The rhythm is often in response to a physiological demand mediated by an increased sympathetic tone, an excess amount of catecholamines or thyroid hormone. A key descriptor of this rhythm's behavior is gradual: the rate speeds up **gradually** and slows down **gradually**.
- d. **Sinus arrhythmia:** This rhythm originates from the sinus node. The heart rate fluctuates noticeably with the respiratory cycle. The heart rate speeds up during inspiration and slows during expiration. The heart rate fluctuates more markedly in infants and less in the elderly.
- e. **Sinus node reentrant tachycardia:** This rare rhythm is due to reentry within the sinus node. The heart rate abruptly jumps to a faster rate (120 to 180/min) and abruptly returns to the baseline without any change in the P wave morphology since the atria are depolarized through the same pathway during this rhythm as in normal sinus rhythm.



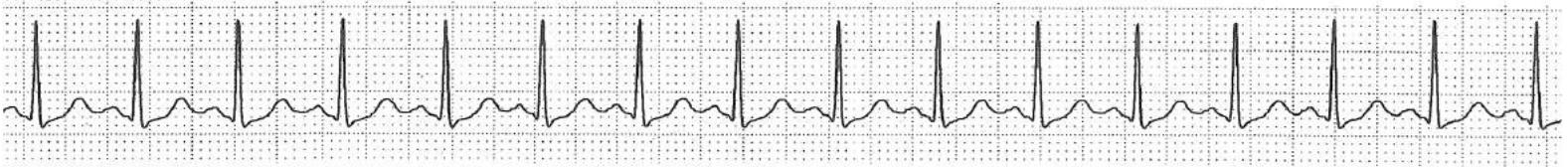
a. **Normal sinus rhythm.**



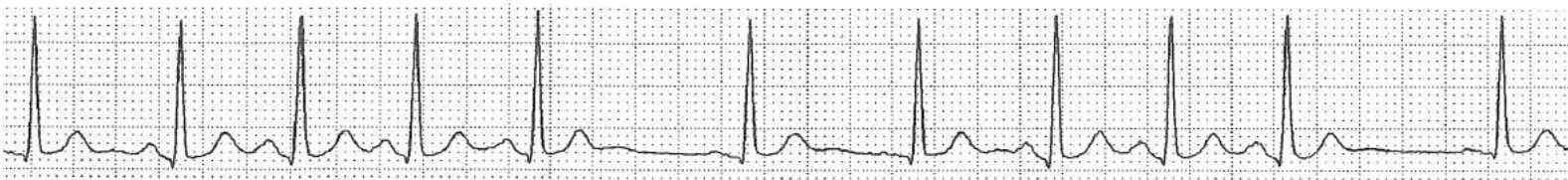b. **Sinus bradycardia.**



c. **Sinus tachycardia.**



d. **Sinus arrhythmia.**



e. **Sinus node reentrant tachycardia.**

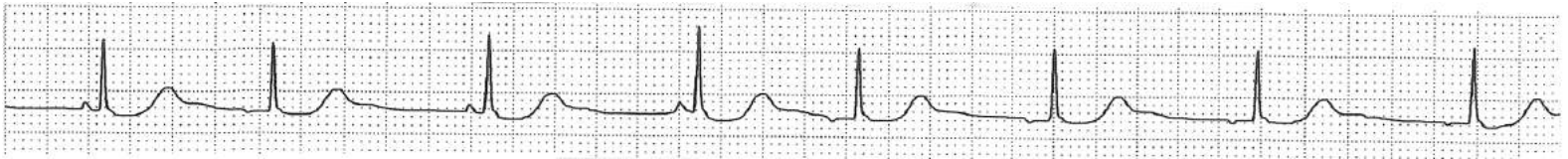


## B. Rhythms originating from the atrium:

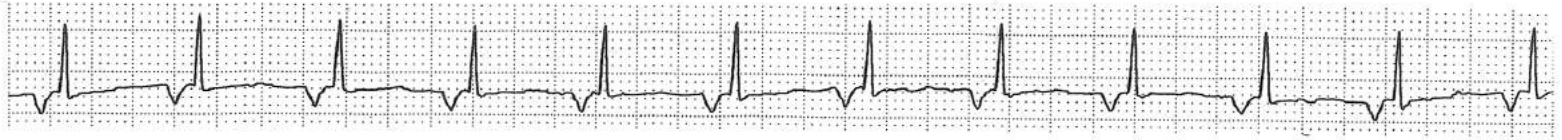- a. **Wandering atrial pacemaker:** The origin of the impulse shifts from one focus to another in the atrium, resulting in changing P wave morphology from beat to beat. The heart rate is usually within normal range.
- b. **Low atrial rhythm:** The rhythm originates from a focus low in the atrium or a region near the coronary sinus and the atria are depolarized retrogradely, resulting in a negative P wave in lead II. The rate and the PR interval are usually within normal range.
- c. **Atrial tachycardia:** One focus in the atrium discharges impulses regularly and rapidly (120 to 220/min). In some cases, intra-atrial reentry is responsible for this rhythm. The rhythm begins and ends abruptly. Besides, the P wave morphology is different from that of sinus rhythm.
- d. **Atrial fibrillation:** In this rhythm, there is no organized atrial depolarization. Rather, there are many wavelets of electrical fronts that collide with each other within the atria. Some of these impulses conduct to the AV node, then to the ventricles, resulting in an irregularly irregular ventricular rhythm. There is no effective mechanical contraction of the atria.
- e. **Atrial flutter:** In this rhythm, the atria are depolarized regularly at a rate ranging from about 250 to 320/min. A macro-reentry within the atrium is responsible for this rhythm. Continuous circus movement of the electrical wave front within the atrium results in the so-called “saw-tooth pattern” of flutter waves, which is best seen in the inferior leads. Most often, every other atrial impulse is conducted to the ventricles, resulting in a ventricular rate that is half the atrial rate.
- f. **Multifocal atrial tachycardia:** In this rhythm consider almost every beat is an atrial premature beat that originates from a different focus in the atria. Therefore, the P wave morphology changes from beat to beat and the PP interval, hence the RR interval, is irregularly irregular. The atrial and ventricular rates are faster than 100/min (commonly about 150/min)



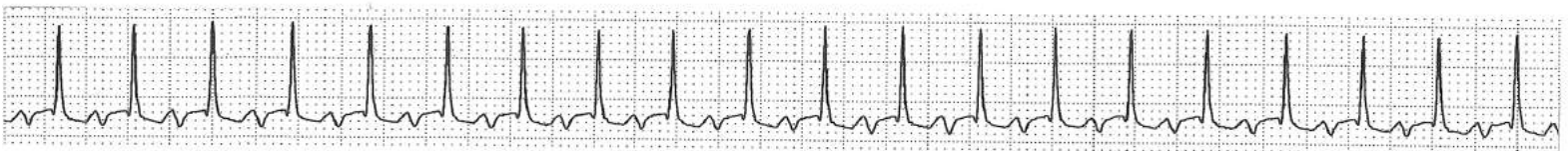**a. Wandering atrial pacemaker.**



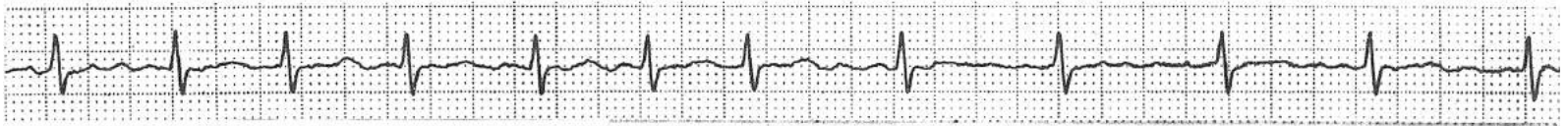**b. Low atrial rhythm.**



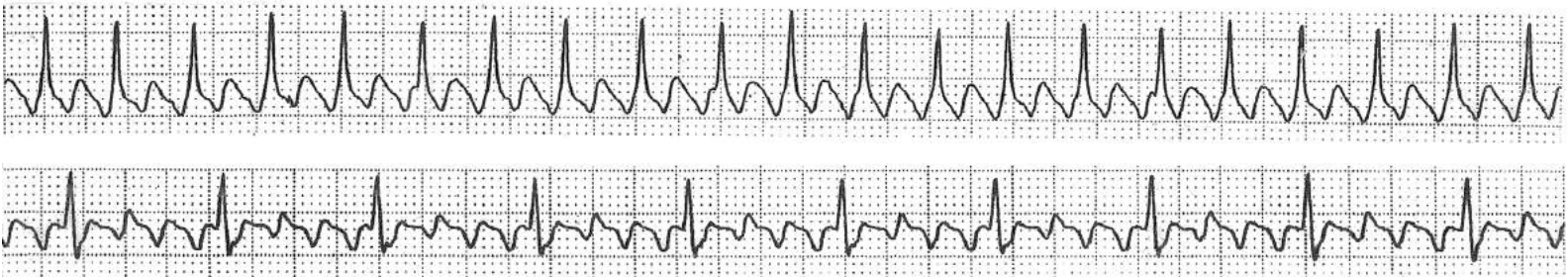
**c. Atrial tachycardia.**



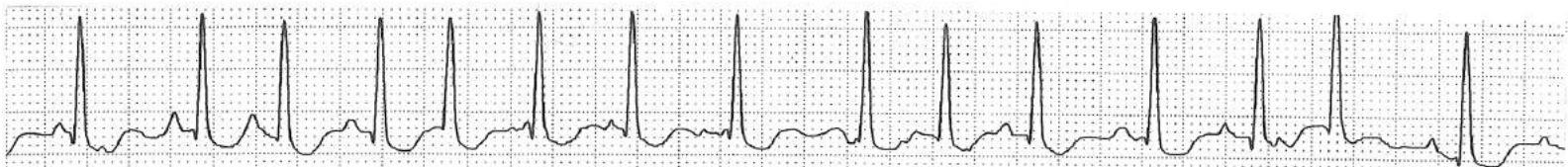**d. Atrial fibrillation.**



**e. Atrial flutter.**



**f. Multifocal atrial tachycardia.**

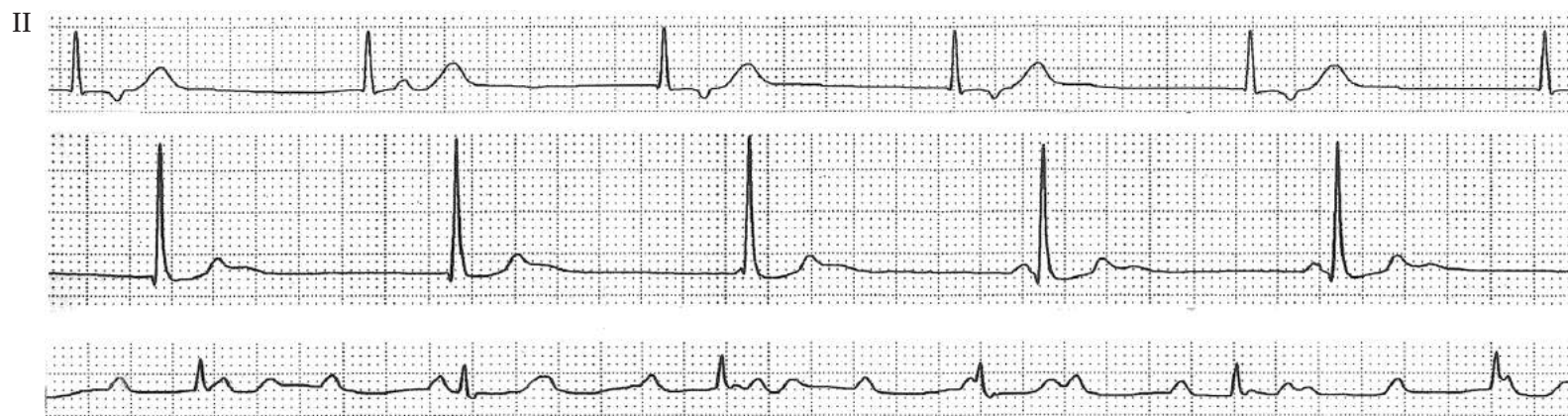

**C. Rhythms originating from the AV junction or in which the AV junction makes up the reentry circuit entirely or partially:**

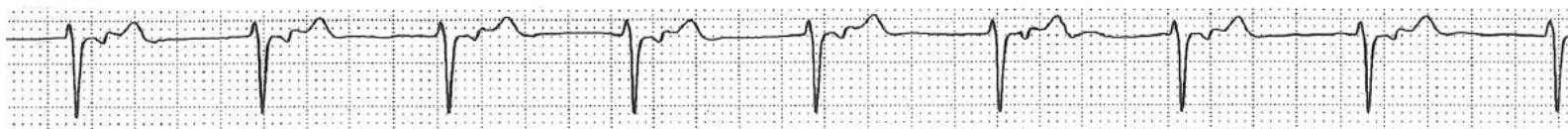
- a. **AV junctional escape rhythm:** This rhythm may emerge when the sinus rhythm is slower than the intrinsic AV junctional pacemaker rate (40 to 50/min) or during a block within the AV node.
- b. **Accelerated AV junctional rhythm:** This rhythm emerges when the AV junctional pacemaker accelerates and is faster than the sinus rhythm at the time. Because the rate is not greater than 130/min, it is not called junctional tachycardia.
- c. **AV junctional tachycardia:** In this rhythm, the AV junctional pacemaker discharges impulses regularly at a rate greater than 130/min. Most often, there is a 1:1 retrograde conduction to the atria, resulting in a negative P wave in front of, within, or after the QRS in the inferior leads.
- d. **AV junctional reentrant tachycardia (AVNRT):** Reentry within the AV junction causes this rhythm. The rate ranges from 120 to 220/min. This reentry circuit spins off impulses to the ventricles and retrogradely to the atria.
- e. **AV reentrant tachycardia (AVRT):** A reentry rhythm with anterograde conduction through the AV junction and retrograde conduction through an accessory pathway (orthodromic) or the reverse (antidromic). The surface ECG manifestation of this rhythm is similar to that of AV junctional reentrant tachycardia with a narrow QRS when it is orthodromic and the QRS is wide if it is antidromic.
- f. **Supraventricular tachycardia (SVT):** Rhythms Cc, Cd, Ce, and Bc are often indistinguishable from the surface ECG and, if so, they are generically called SVT. If the mechanism of the rhythm is known, which often requires intracardiac electrograms, the specific name of the rhythm should be used for clarity of communication and understanding of the problem. AV junctional reentrant tachycardia accounts for approximately 60% of SVTs and AV reentrant tachycardia about 30% of SVTs.



**a. AV junctional escape rhythm.**



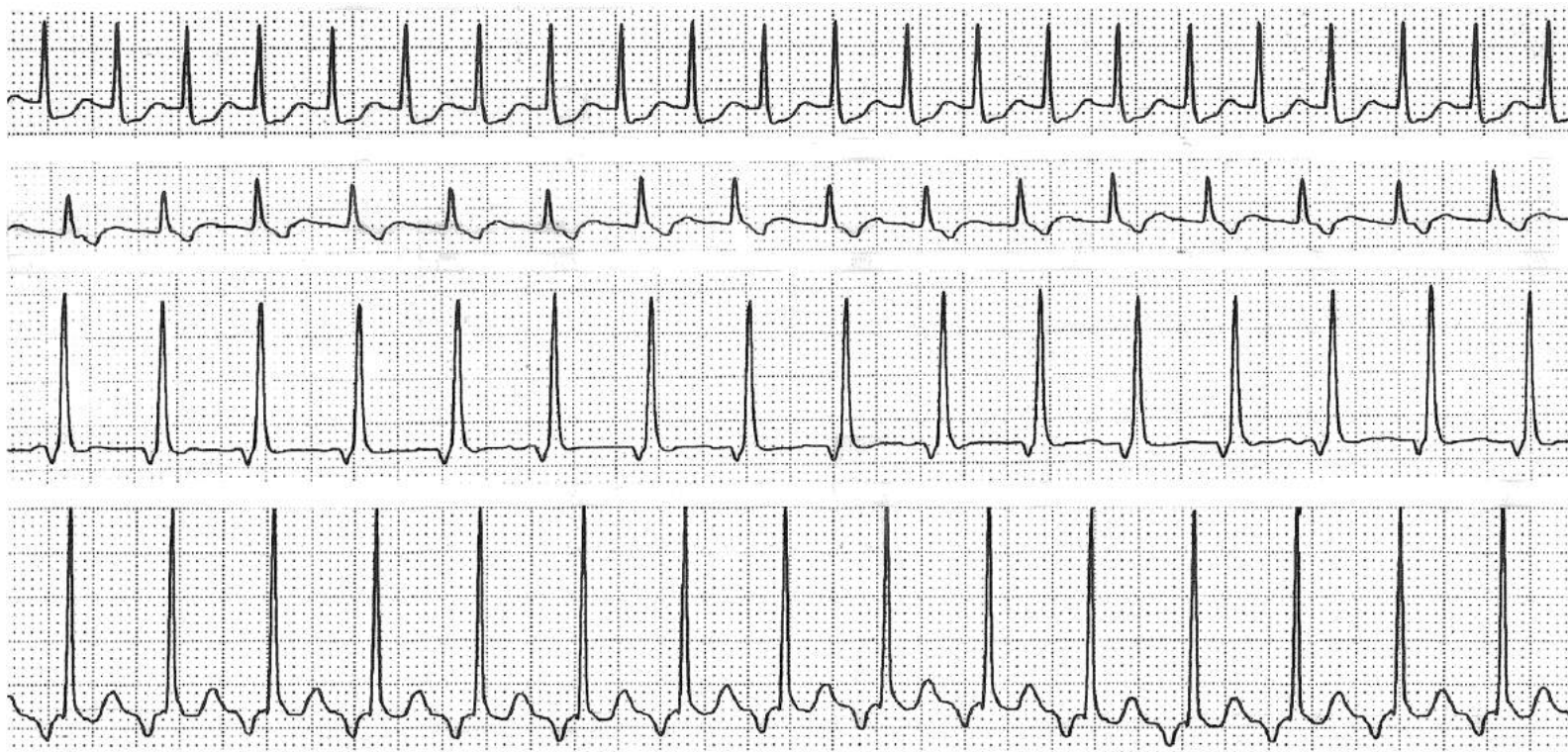
**b. Accelerated AV junctional rhythm.**



**c. AV junctional tachycardia.**

**d. AV junctional reentrant tachycardia.**

**e. AV reentrant tachycardia.**



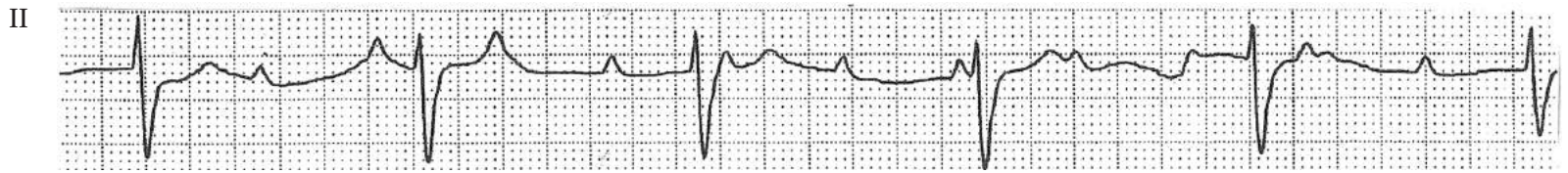
Rhythms c, d, and e can present as any one of the above 4 tracings. In these lead II rhythm strips, there is a retrograde (negative) P wave either within, after or in front of the QRS.

## D. Rhythms originating from the ventricle:

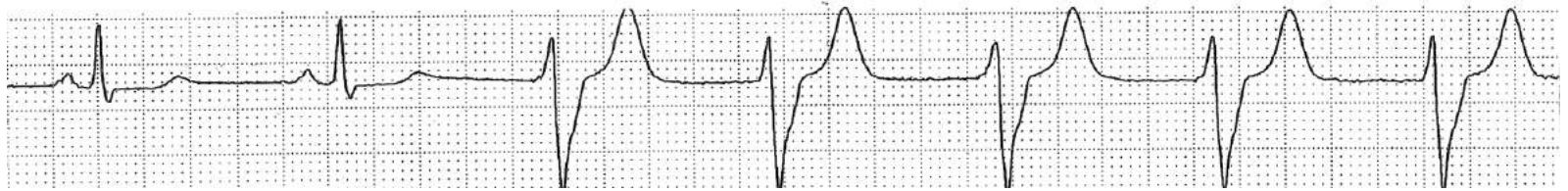
- a. **Ventricular escape rhythm:** AV block below the His bundle allows the pacemaker in the Purkinje system to escape at a rate of usually 25 to 30/min with a wide QRS.
- b. **Accelerated idioventricular rhythm:** This rhythm emerges when the pacemaker rate in the Purkinje system accelerates to 50 to 130/min and is faster than the existing basic rhythm. Since the rate is slower than conventional ventricular tachycardia, but faster than the intrinsic rate of the Purkinje system, this intermediate name is given.
- c. **Ventricular tachycardia:** A rhythm that originates from the ventricle usually at a rate between 130 and 220/min. It is caused by an ectopic focus in the ventricle discharging impulses regularly, or by reentry in the ventricle.
- d. **Torsade de pointes:** A peculiar kind of ventricular tachycardia in which the QRS complex changes its axis gradually, as if it were twisting around the baseline. The QRS rate is fast and usually ranges from 200 to 300/min. This rhythm is seen in patients with a long QT interval. When a rhythm like this occurs in the absence of prolongation of the QT interval, it is called polymorphic ventricular tachycardia.
- e. **Ventricular flutter:** A regular rhythm originating from the ventricle at a rate of 220 to 300/min. In contrast to ventricular tachycardia, it is difficult to determine the beginning and end of the QRS.
- f. **Ventricular fibrillation:** No organized ventricular depolarization is present and the baseline of the ECG fluctuates irregularly in a disorganized fashion. There is no effective cardiac pumping with this rhythm. It may be defibrillated to an effective rhythm with an electric shock to the precordium.
- g. **Asystole:** The electrocardiogram reveals a flat line without any electrical activity in the cardiac tissue. As with ventricular fibrillation, the patient will die if no effective rhythm takes over. An intracardiac injection of epinephrine may, on a rare occasion, cause ventricular fibrillation to emerge, which then may be defibrillated.



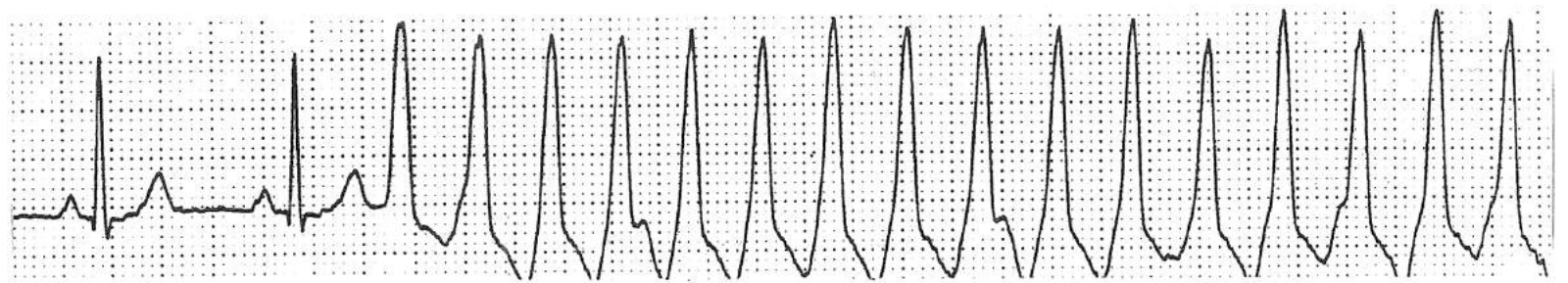
a **Ventricular escape rhythm.**



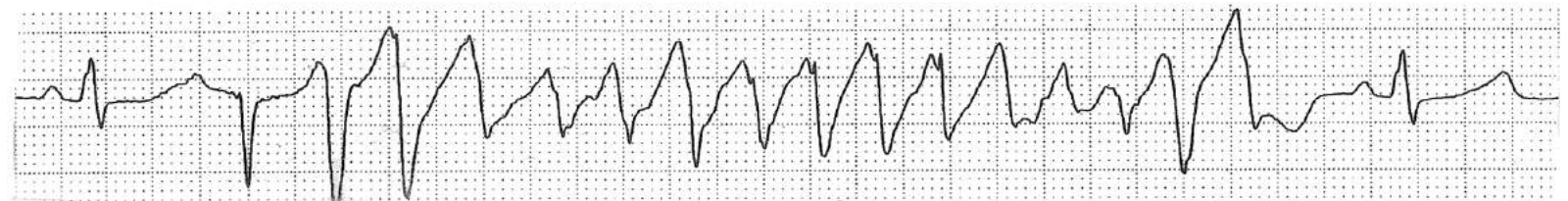
b. **Accelerated idioventricular rhythm.**



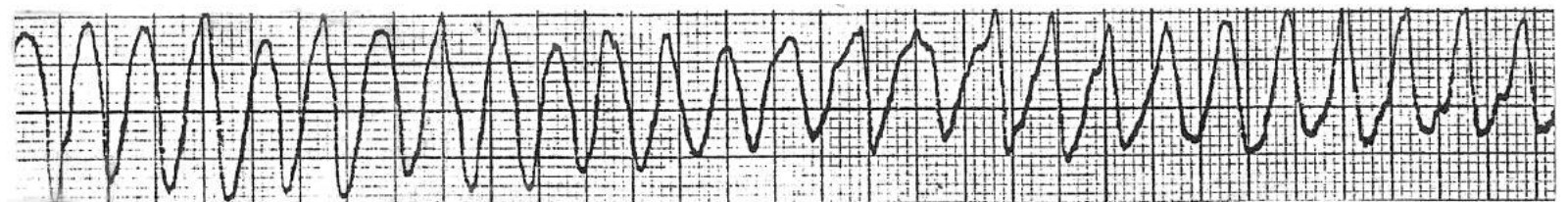
c. **Ventricular tachycardia.**



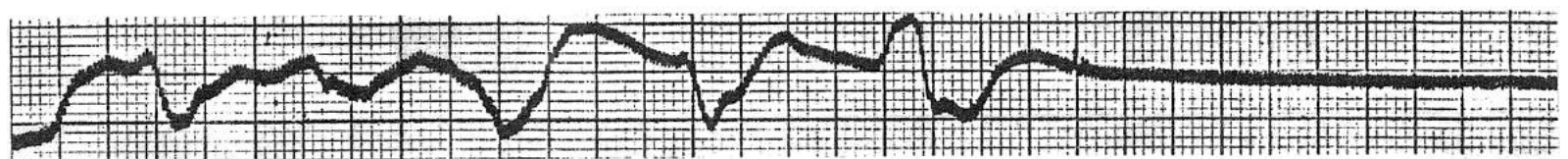
d. **Torsade de pointes.**



e. **Ventricular flutter.**



f and g. **Ventricular fibrillation followed by asystole.**

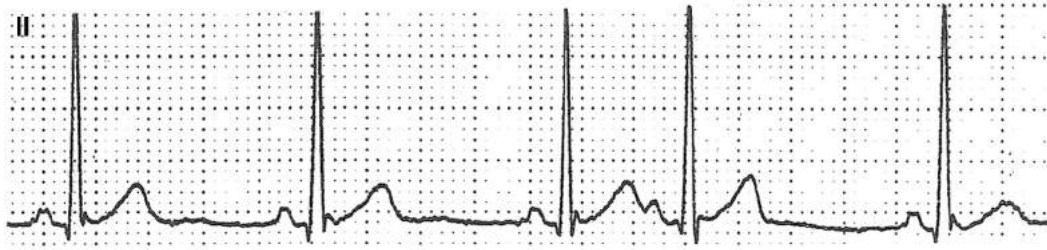


## **E. Premature beat (or contraction or complex):**

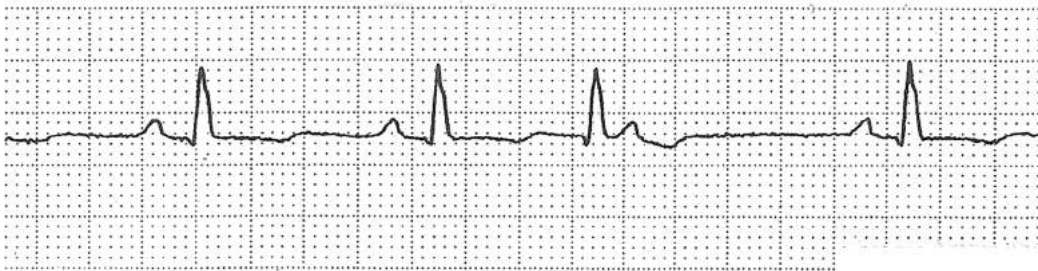A premature beat results when a baseline rhythm is in progress and an impulse from another focus in the heart is discharged earlier (prematurely) than the next expected beat of the baseline rhythm. These beats are designated according to the focus from which they originate, e.g., atrial premature beat (APB), junctional premature beat (JPB), or ventricular premature beat (VPB). The naming convention for these beats varies – e.g. PAC, APC, PVC, VPC etc. where C stands for either contraction or complex. When three or more VPBs occur in a row, it is called ventricular tachycardia.



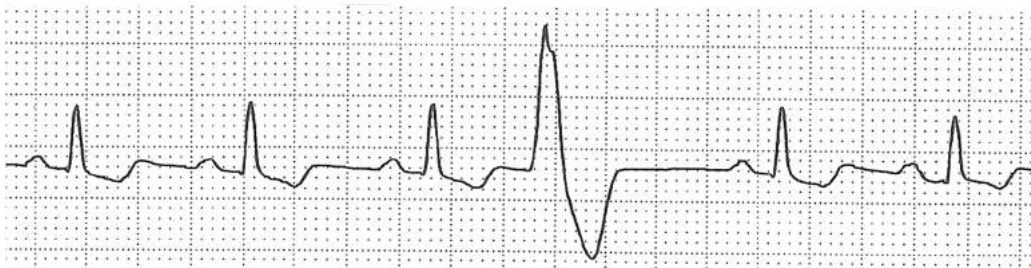
### Atrial premature beat



### AV junctional premature beat



### Ventricular premature beat

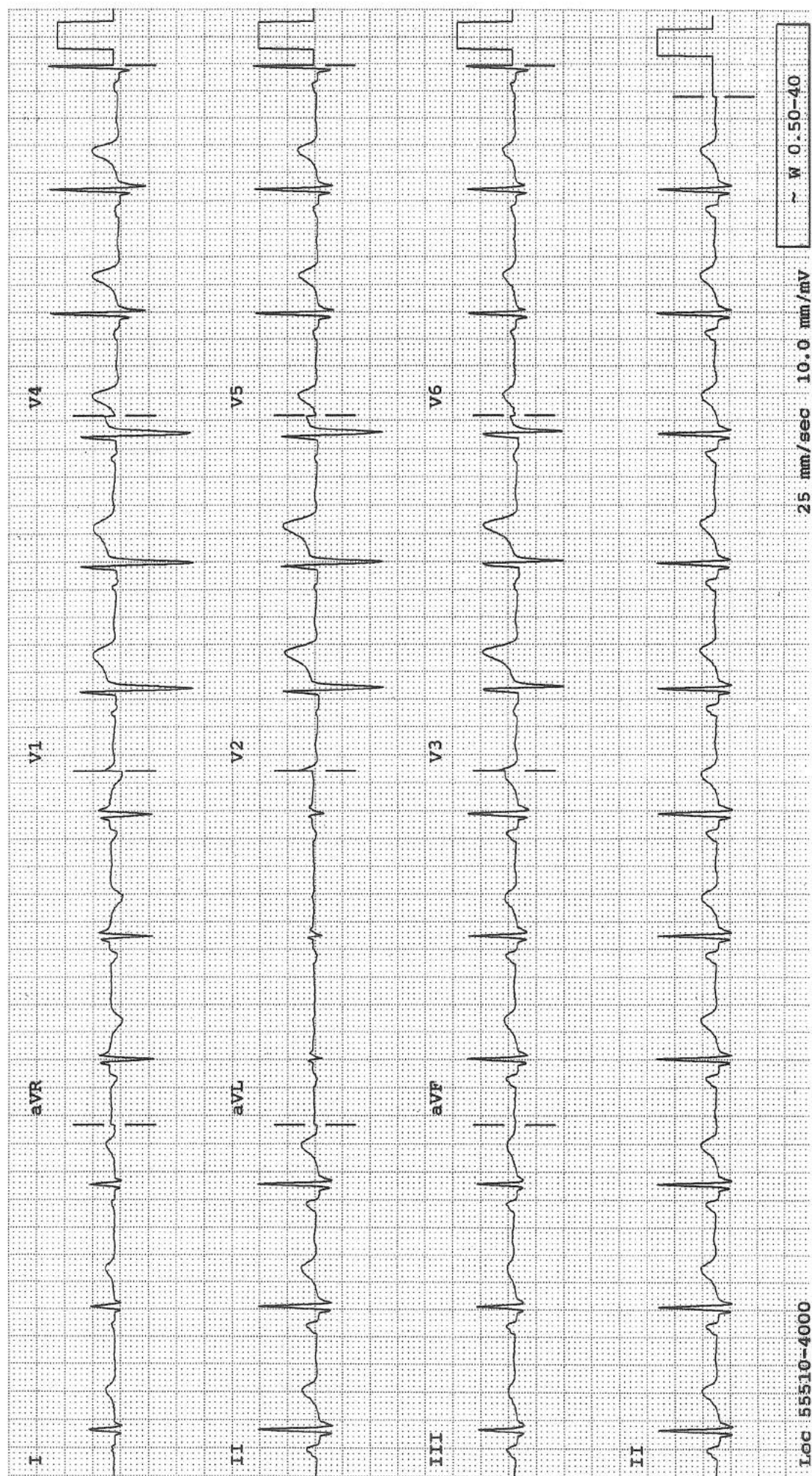


## A Normal ECG

Let's analyze the tracing on the opposite page systematically. One should quickly see the calibration mark at the end and note that the tracing was taken with the standard calibration both for the limb and precordial leads. A regular rhythm at a rate of 65/min is present. There is a positive P wave preceding each QRS with a fixed PR interval, indicating normal sinus rhythm. The PR interval of 0.16 s, the QRS duration of 0.1 s, the QRS voltage, the mean QRS axis, and the QT interval of 0.4 s are all within normal range. The R waves (or R/S ratio) progress normally in the precordial leads and the transition (the change from R/S ratio of  $< 1$  to  $> 1$ ) occurring between  $V_3$  and  $V_4$  is normal, i.e. neither early nor late transition. Small Q waves in leads I, II, III, aVF, and  $V_4$  through  $V_6$  are normal septal Q waves. For the Q wave to be abnormal in these leads, it must be wider than 0.04 s. The interventricular septum, which is the first part of the ventricular myocardium to be depolarized, is depolarized from left to right and often slightly cephalad, resulting in an initial negative deflection (Q wave) in these leads. In lead  $V_2$ , any Q wave is abnormal and needs explanation. The T waves are upright in all leads except in aVR. There is a 1 mm ST elevation in leads  $V_1$  thru  $V_3$ . However, this degree of ST elevation can be present normally in these leads.

**Conclusion:** Normal ECG



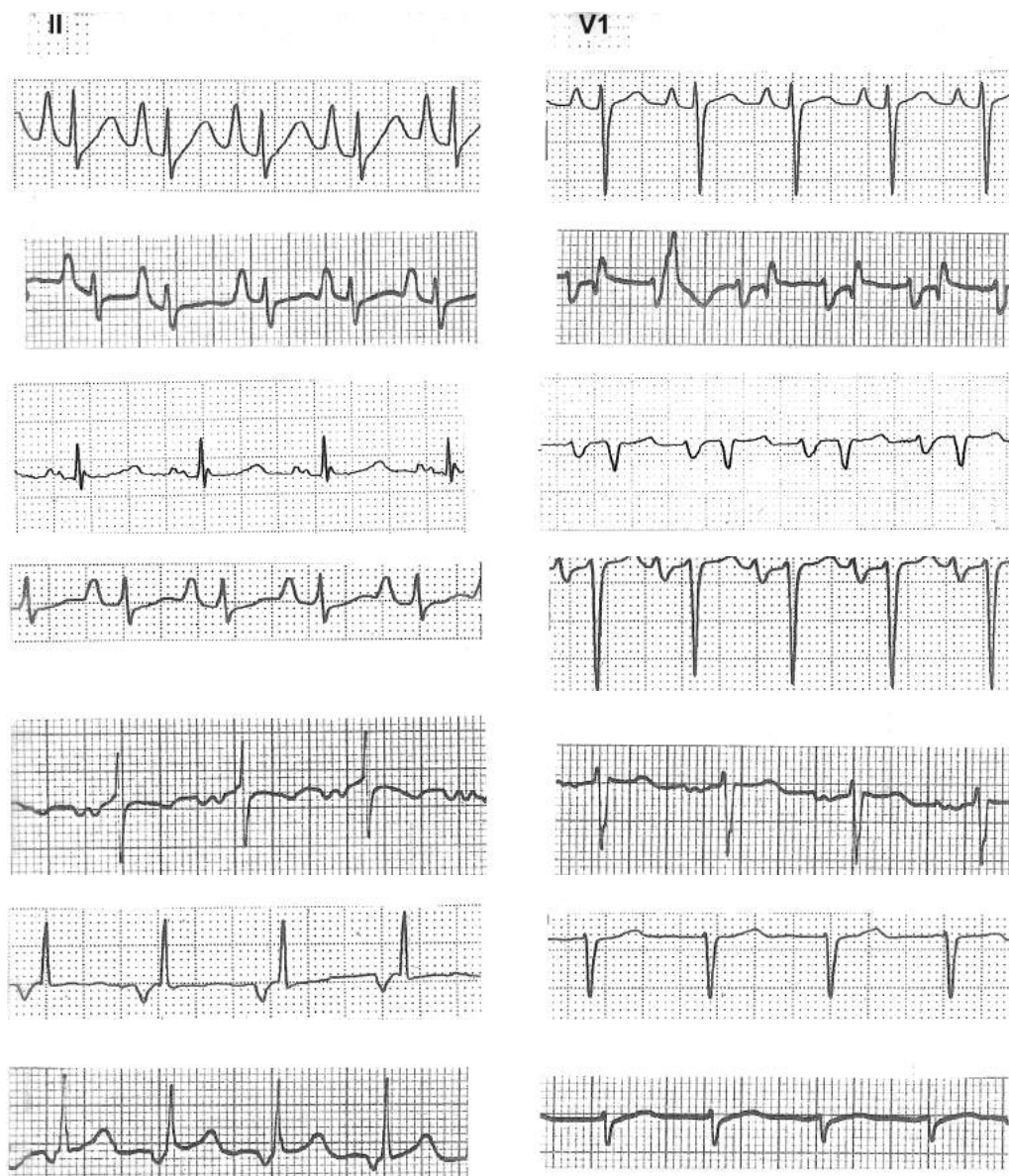




## P Wave Abnormalities

When one is looking for P waves, leads II or  $V_1$  are good leads to look at. Besides, since the axis of lead II is parallel to the direction of atrial depolarization, normal atrial depolarization will result in a positive P wave in this lead. If the P wave is negative in this lead, it means only one thing: the atria are depolarized retrogradely. This happens either because the impulse originates from somewhere low in the atrium, A-V junction, or ventricle. The P wave morphology in  $V_1$  is especially useful. During sinus rhythm, with or without left atrial enlargement, the P wave is most often biphasic (initially positive, then negative) in this lead. If the P wave is not biphasic and especially if it is small, one could be dealing with an ectopic atrial tachycardia rather than sinus rhythm. If the precordial leads are reversed, one can recognize it by paying attention to the P wave morphology: The lead with the most biphasic P wave is  $V_1$ .

- a. Right atrial enlargement. The P waves in lead II are taller than 2.5 mm
- b. Often, the P wave in  $V_1$  is diphasic in RAE. In that case, the transition from the positive to negative vector is abrupt, whereas in the case of LAE causing a diphasic P wave in  $V_1$ , the transition is slurred.
- c. Left atrial enlargement. The P wave in  $V_1$  is diphasic and the negative area is more than 1 mm deep and 1 mm wide. The P waves in the inferior leads may be broad and notched.
- d. Batrial enlargement.
- e. Intra-atrial conduction defect. The P waves are broad and notched in lead II but not characteristic of LAE in  $V_1$ .
- f. Negative P waves in lead II with a PR interval  $> 0.12s$  is consistent with a low atrial rhythm.
- g. Negative P waves in lead II with a short PR interval ( $< 0.12s$ ) is consistent with an A-V junctional rhythm.



## Ventricular Hypertrophy, Left, Right and Biventricular

### ECG Features of LVH

- Increased QRS voltage (thickened left ventricle generates more electrical force)
- Shift of QRS vector loop posteriorly and to the left (thickened left ventricle alters the geometry)
- Delayed onset of the intrinsicoid deflection (thickened left ventricle takes a longer time to be depolarized)
- Left atrial enlargement (the left atrium contracts forcefully against the non-compliant left ventricle)
- ST-T changes ("strain" pattern) (thickened left ventricle distorts repolarization wave)

#### Romhilt and Estes' point-score system

- Amplitude .....3 points  
Any of the following:
  - Largest R or S wave in the limb leads  $\geq 20$  mm
  - S wave in  $V_1$  or  $V_2 \geq 30$  mm
  - R wave in  $V_5$  or  $V_6 \geq 30$  mm
- ST-T—segment changes (typical pattern of left ventricular strain with the ST-T—segment vector shifted in direction opposite to the mean QRS vector)
  - Without digitalis ..... 3 points
  - With digitalis ..... 1 point
- Left atrial involvement ..... 3 points  
Terminal negativity of the P wave in  $V_1$  is 1 mm or more in depth with a duration of 0.04 second or more
- Left axis deviation  $-30^\circ$  or more ..... 2 points
- QRS duration  $\geq 0.09$  second ..... 1 point
- Intrinsicoid deflection in  $V_5$  and  $V_6 \geq 0.05$  second ..... 1 point

$\geq 5$  : LVH

4 : probable LVH

Sensitivity : 54%

False positive rate : 3%

#### Sensitivity and Specificity of the Frequently Used Criteria for the Diagnosis of Left Ventricular Hypertrophy\*

Criterion	Sensitivity (%)	False-positives (%)
$R + S > 45$ mm	45	7
$SV_1 + RV_5$ or $RV_6 > 35$ mm	43	5
OID $V_5$ or $V_6 = 0.05$ – $0.07$ second	29	1
$RV_5$ or $RV_6 > 26$ mm	25	2
$RaVL > 11$ mm	11	0
$R_1 + S_3 > 25$ mm	11	0
$SaVR > 14$ mm	7	0
$RaVF > 20$ mm	1	1

OID = onset of intrinsicoid deflection.

When the presence of any one of the above criteria is considered diagnostic of LVH:

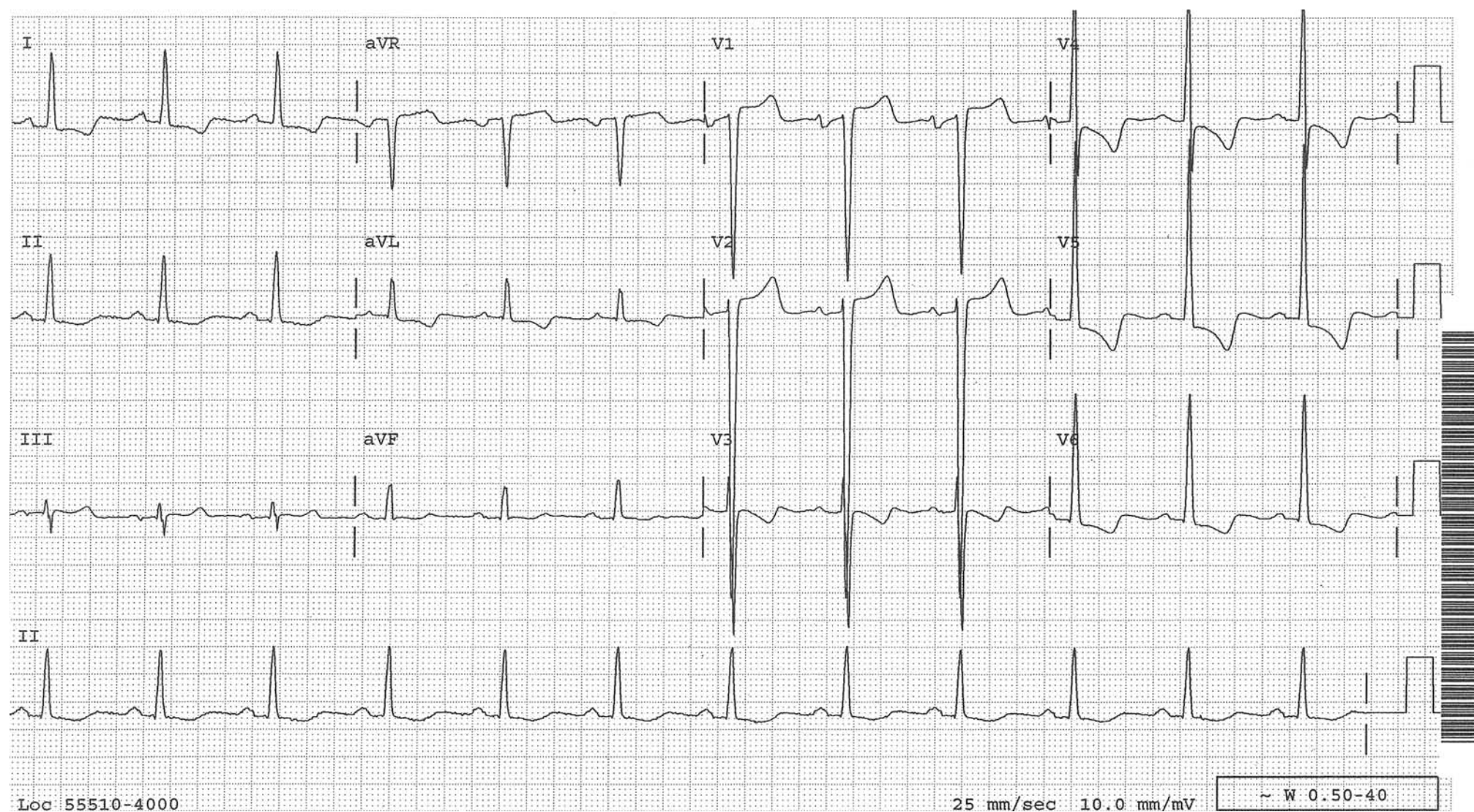- Sensitivity: 60–85%
- Positive predictive rate: 89%
- False positive rate: 11%

Chou: Electrocardiography in clinical practice. Fourth ed., 1996.



## LVH

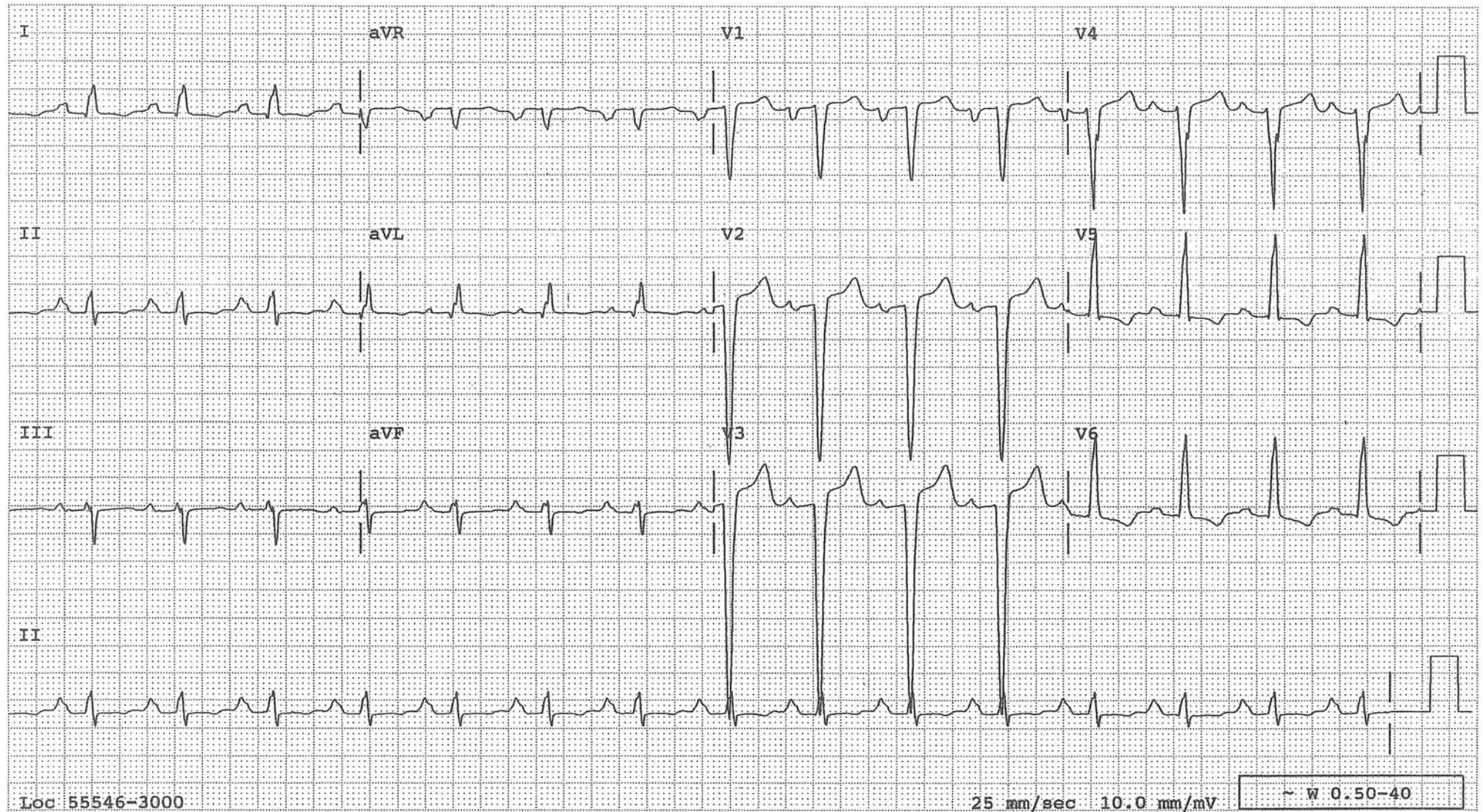
A typical example of LVH. The features are: deep S waves in V1-3, tall R waves in V4-6, STT changes in V5-6 called strain pattern and left atrial enlargement. Some degree of ST elevation in V1-3 is common. 90% of healthy young men have 1-3 mm ST elevation in V1-3. The deeper the S wave, the more the ST elevation. Note that the QRS axis is not deviated to the left. LAD is not part of LVH. In fact, if LAD is present, one has to call two diagnoses: LVH and left anterior fascicular block.

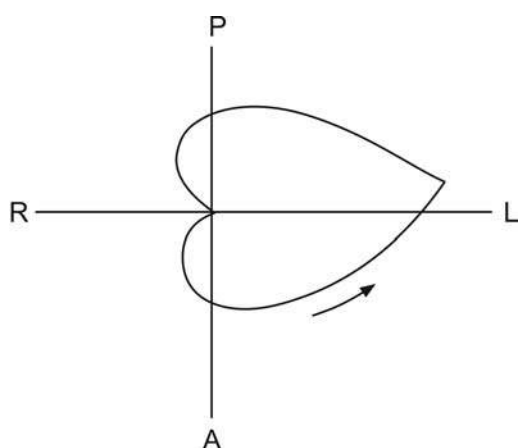
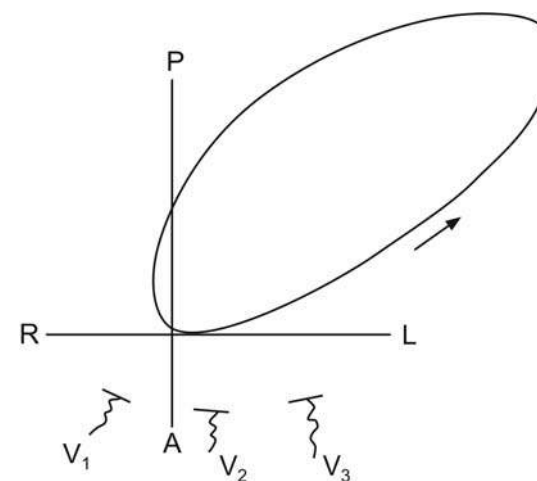




## LVH Simulating Acute Anteroseptal MI

QS pattern and ST elevation in V1-3 simulate acute anteroseptal MI. It is not unusual for LVH without acute MI to manifest this way. See the vectocardiographic explanation on the next page. Note the ST segment is concave. Acute MI more likely causes convex ST segment. LVH combined with old anteroseptal MI cannot be ruled out. An echocardiogram can be useful to sort them out.



**Normal****LVH**

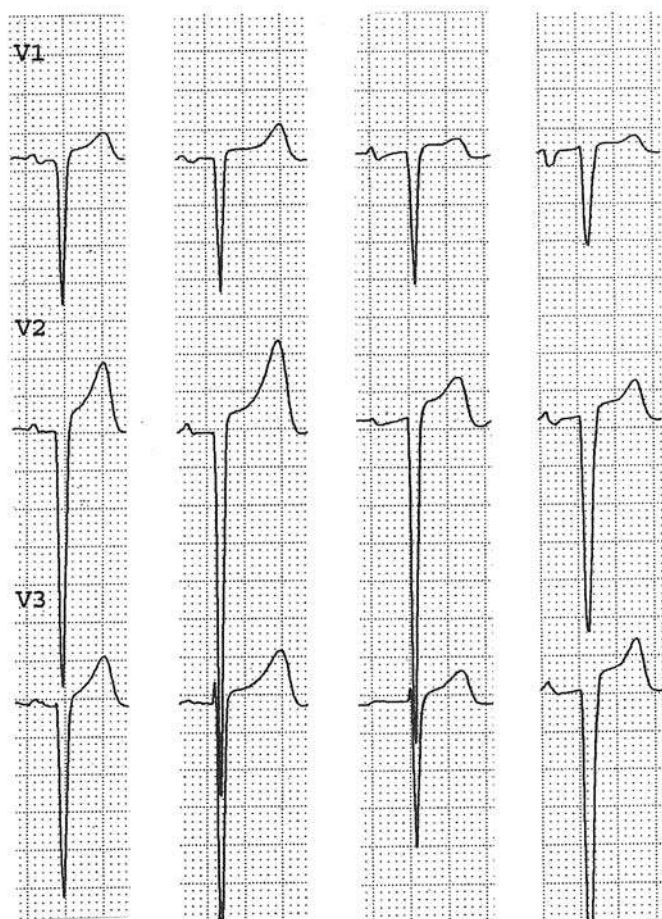
Examples of QRS vector loop projected on the horizontal plane in normal and LVH. With LVH, not only the loop is bigger but is swung posteriorly. Often, no vectors are directed anteriorly towards V1-3 and QS pattern results in these leads in the absence of myocardial infarction.



## LVH with and without Acute Anteroseptal MI

### LVH without acute ASMI

Note the QS pattern. The elevated ST segment is concave. T waves are not inverted.



Patient

1

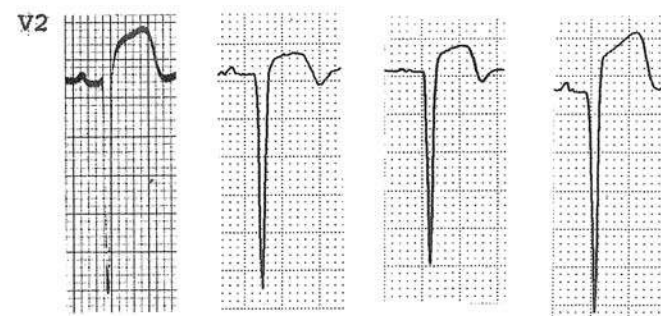
2

3

4

### LVH with acute ASMI

Note the QS pattern. The elevated ST segment is convex. If the T wave is terminally inverted, it is also a good sign of acute MI.



Patient

1

2

3

4

## RVH

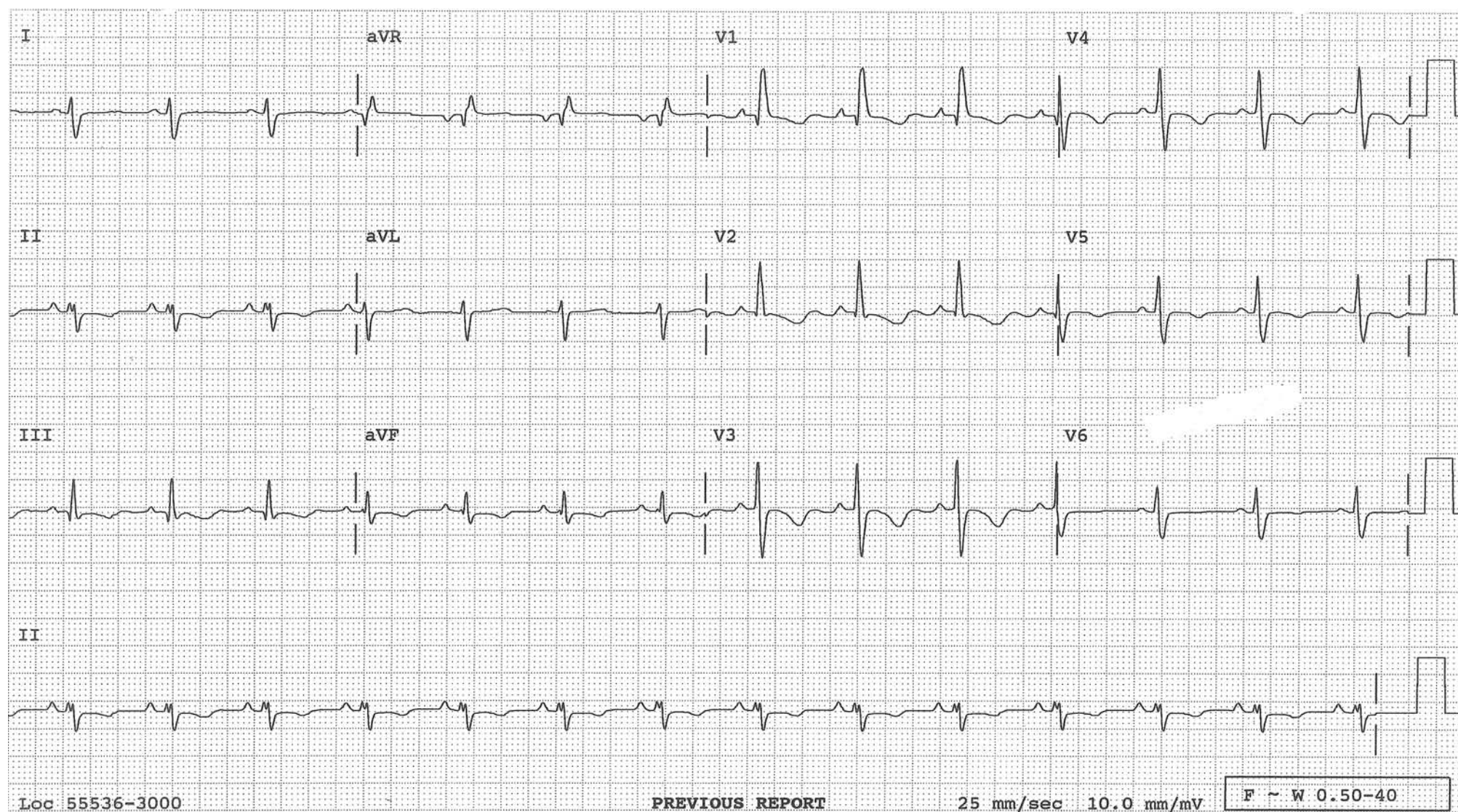
There are two types of RVH

	<i>Not due to COPD</i>	<i>Due to COPD</i>
QRS axis	RAD	RAD
STT $\Delta$ s in V <sub>1-3</sub>	+	+
S wave in V <sub>6</sub>	+	+
R waves in V <sub>1-3</sub>	tall	poor progression or QS pattern



## RVH not due to COPD

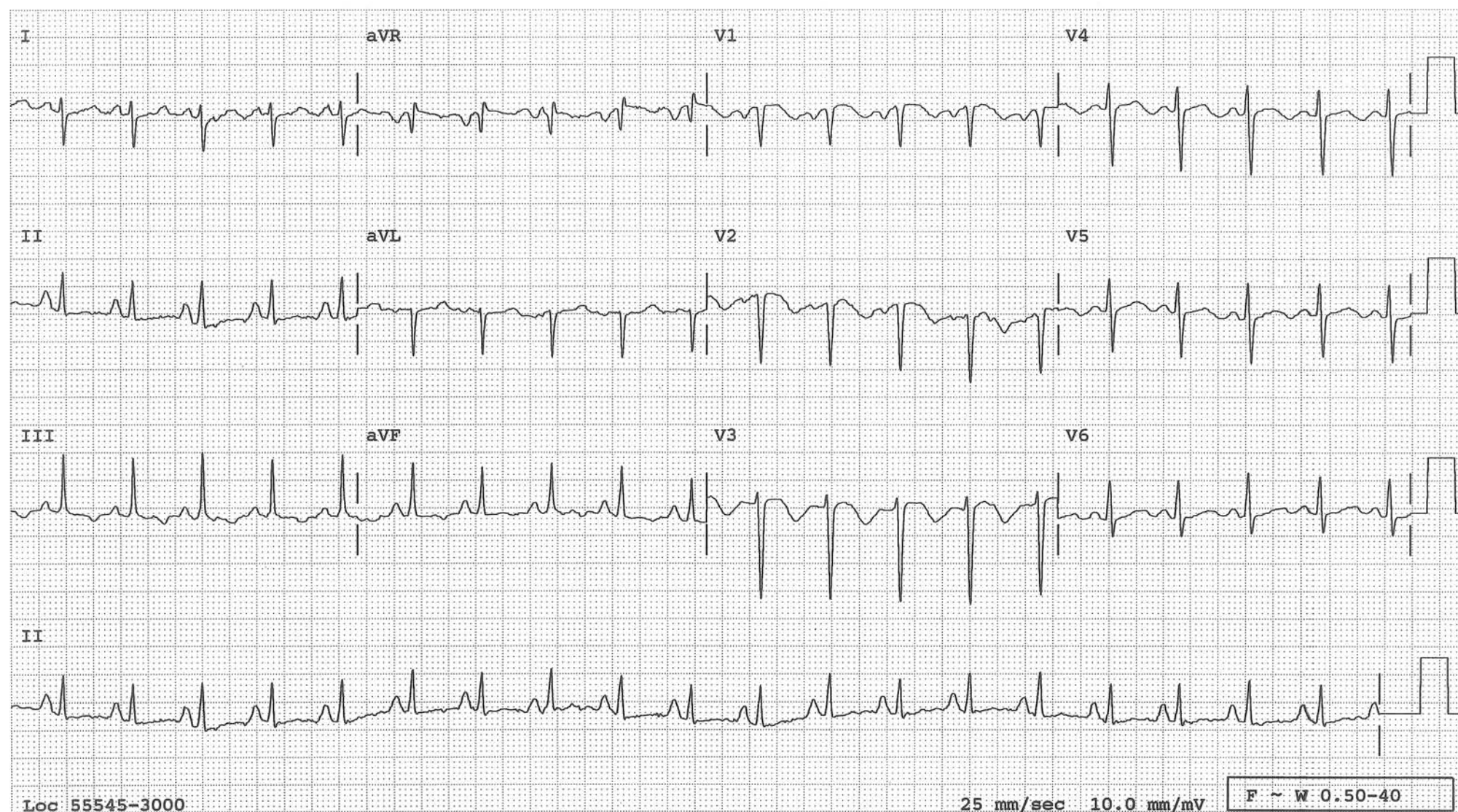
The mean QRS axis is deviated to the right. Right axis deviation should make one think first of RVH. After the right axis deviation, all other diagnostic features of RVH are found in the precordial leads and include tall R wave in V1, deep S wave in V6 and ST-T changes in V1-3. All of these features are present in this tracing.





## RVH 2° to COPD

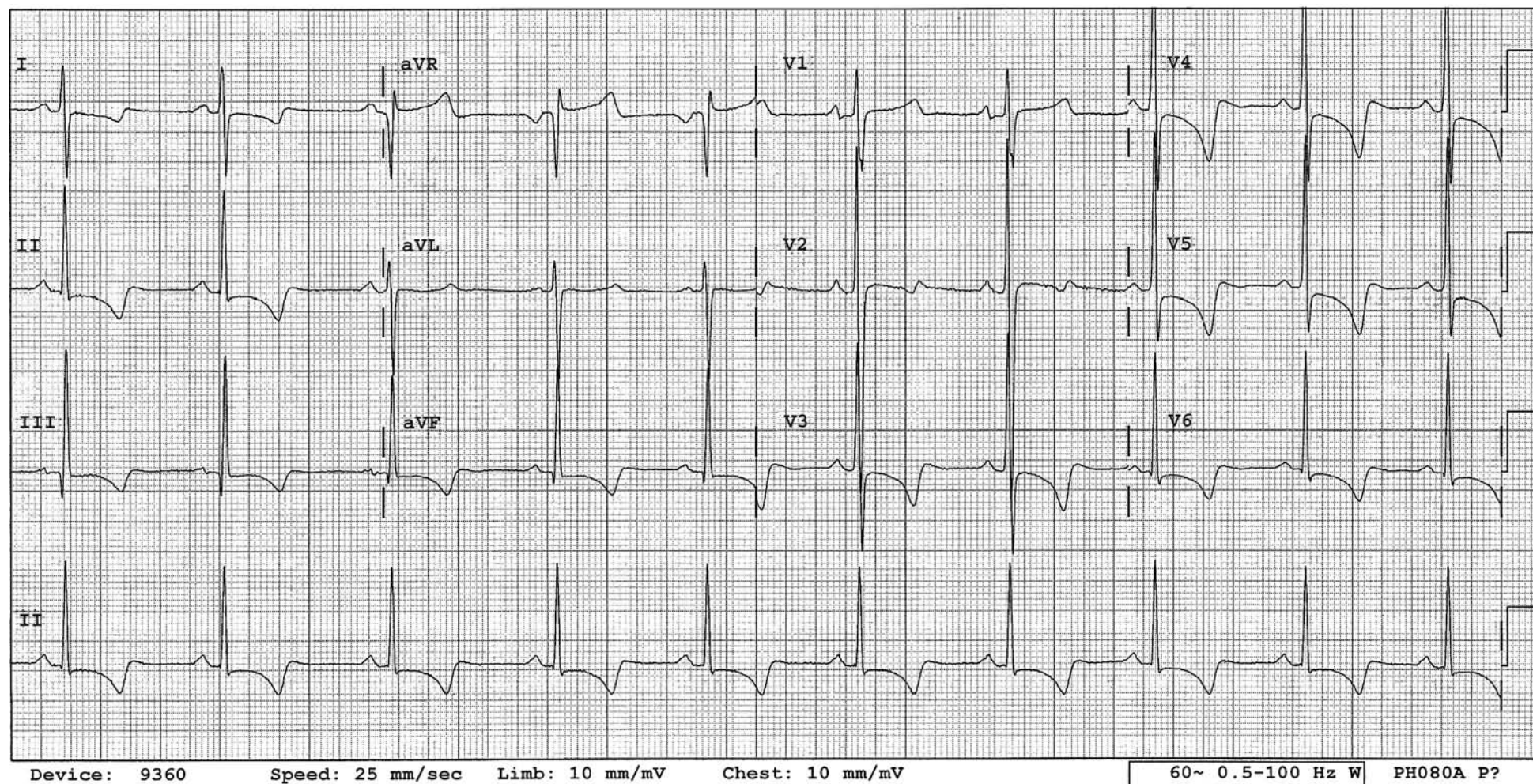
Right axis deviation, deep S wave in V6 and STT changes more in V1-3 than in V4-6 are just as in RVH not due to COPD. However, the R waves behave differently. Instead of tall R waves in V1-3, it is hardly present or even absent (QS pattern) in this condition.





## Biventricular Hypertrophy

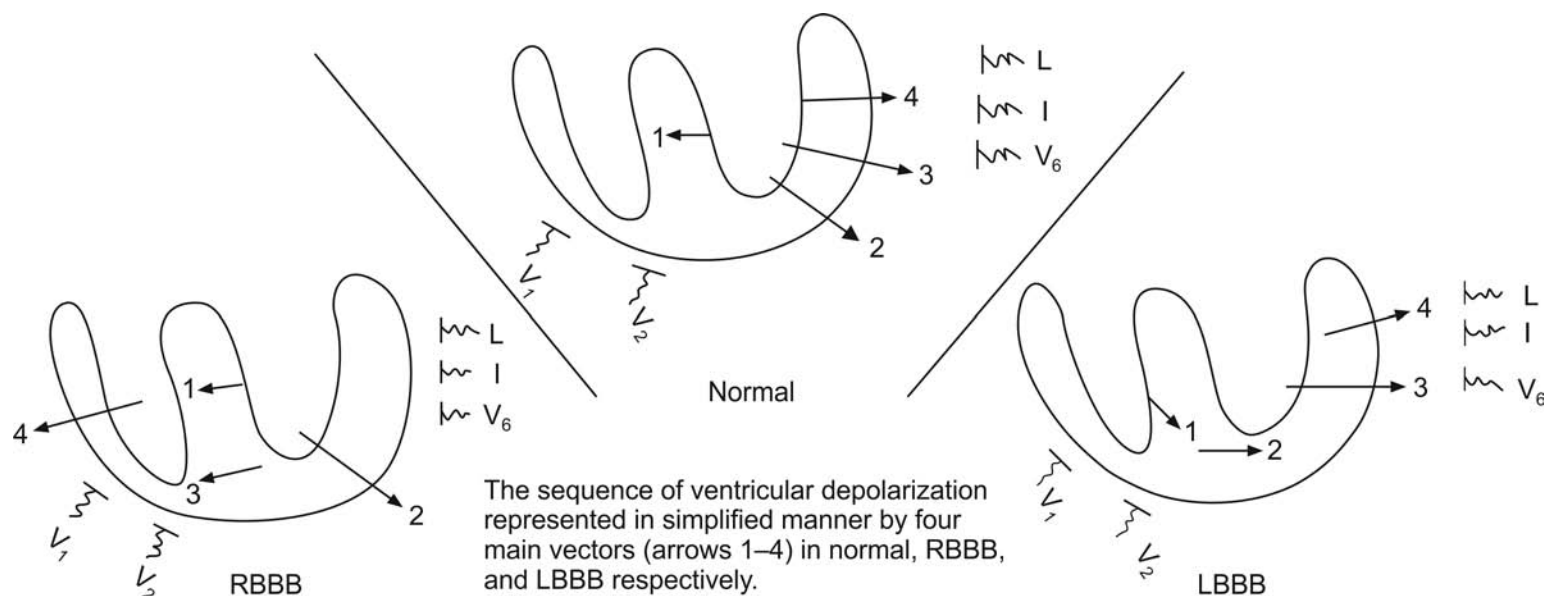
In V2, the markedly increased QRS voltage (almost 6 mV) is made of about equal-sized R wave and S wave and reflects biventricular hypertrophy (Katz-Wachtel criteria). Additionally, the mean QRS axis is shifted to the right reflecting right ventricular hypertrophy and ST-T changes of the right and left ventricular hypertrophy are present.



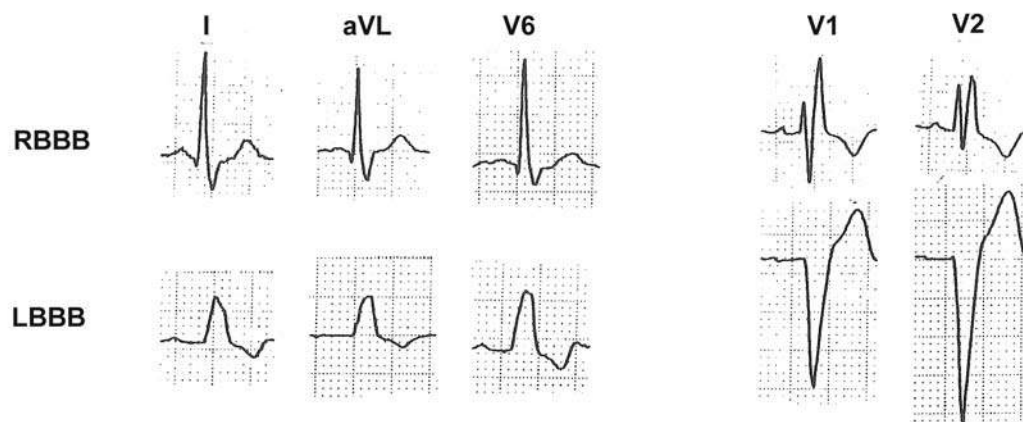


## Intraventricular Conduction Defect

### Bundle Branch Block



In RBBB, the initial ventricular depolarization is not affected and vectors 1 and 2 occur as in normal. Then, the right ventricle is depolarized delayed (vectors 3 and 4). To leads V1 and 2, vector 1 will register a positive deflection and vector 2, a negative deflection. Then, vectors 3 and 4 will again register a strong positive deflection (M-shaped QRS). Vectors 3 and 4 are directed away from leads aVL, I and V6 and will register a broad S wave in these leads (rSR' pattern in V1). In LBBB, the ventricular depolarization is altered from the beginning to the end and vectors 1 thru 4 are all directed away from leads V1 and 2 and will register a deep negative deflection in these leads. These vectors are directed toward leads aVL, I and V6, and will register monophasic R wave in these leads. In both RBBB and LBBB, ventricular depolarization takes longer than usual to complete and the QRS is wider than 0.12 s.

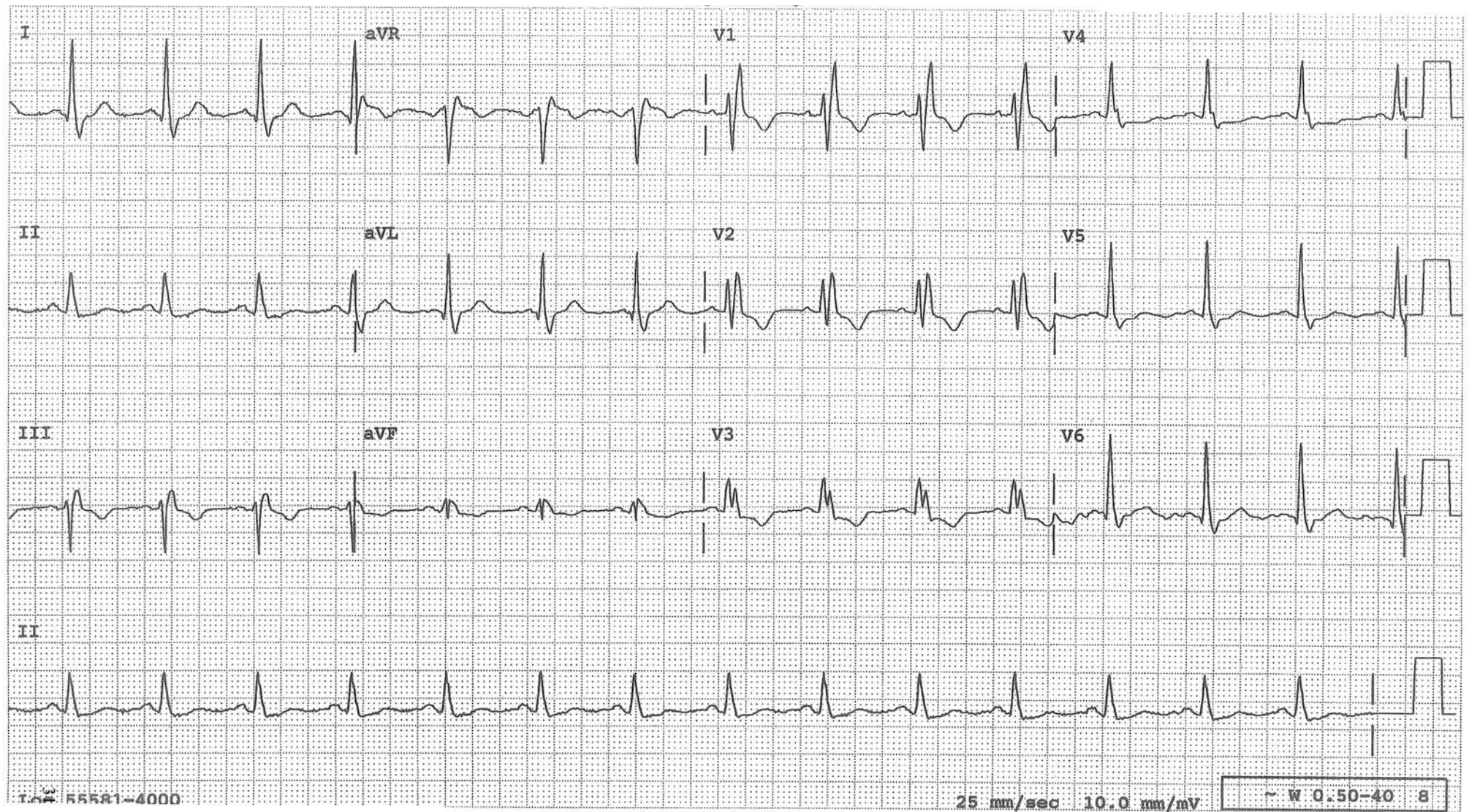




## Right Bundle Branch Block

### Diagnostic Features:

- QRS duration is  $>0.12$  s.
- rSR' pattern in  $V_{1-2}$
- Broad S waves in leads I, aVL and  $V_6$ .
- T wave inversion in  $V_{1-3}$  is secondary to conduction defect.
- If the QRS configuration for RBBB is present but the QRS width is less than 0.12 s, incomplete RBBB may be called, which is more often due to acute dilation of the right ventricle, as from pulmonary embolism.

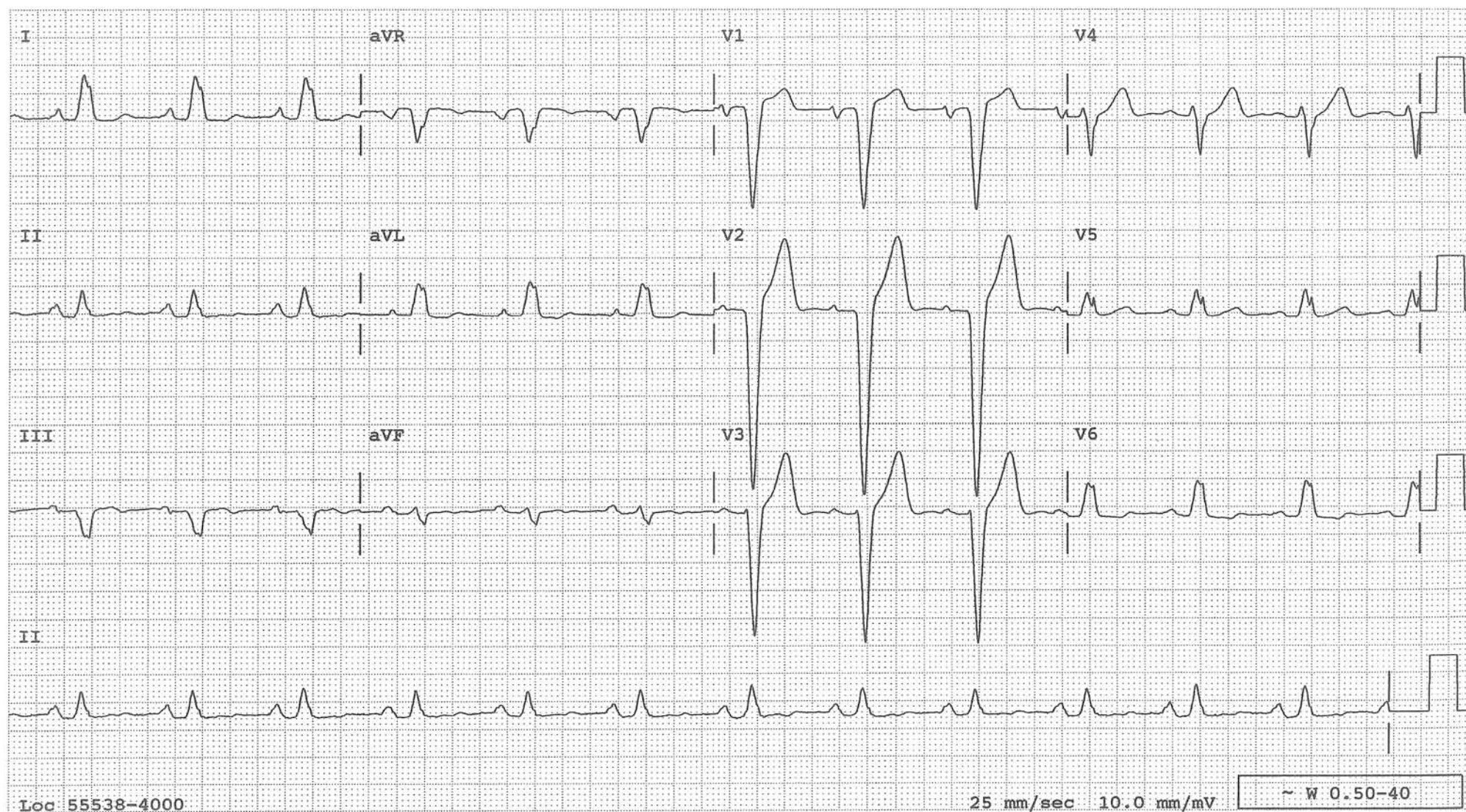




## Left Bundle Branch Block

**Diagnostic features:**

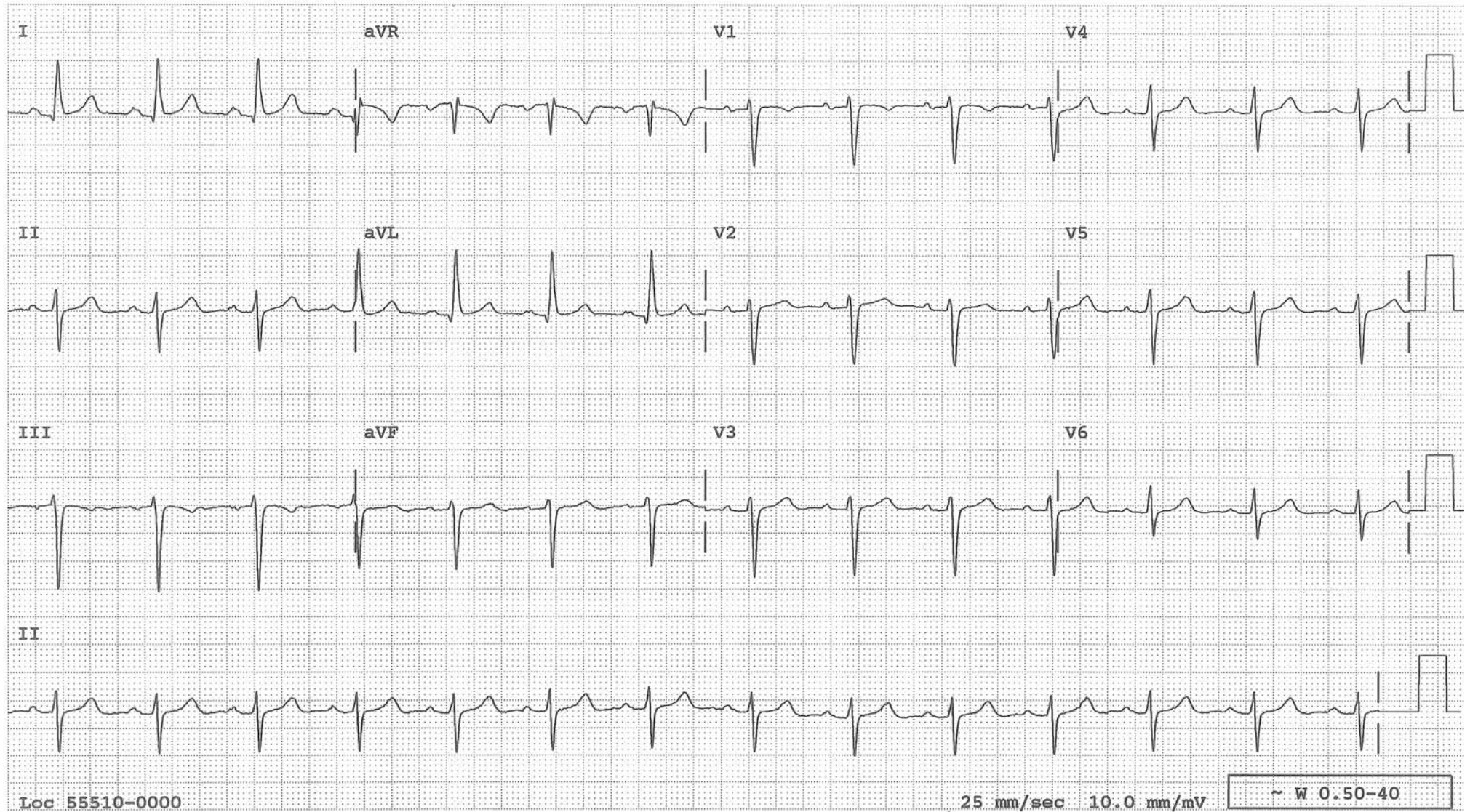
- QRS duration is  $>0.12$  s.
- Monophasic R waves in leads I, aVL and  $V_6$ .
- QRS is mostly negative in  $V_{1-3}$ .
- ST segment deviation in direction opposite to the main QRS component (ST-T changes secondary to conduction defect).
- ST segment is elevated in lead  $V_{1-3}$ . This degree of ST elevation secondary to LBBB is common.





## Left Anterior Fascicular Block (LAFB)

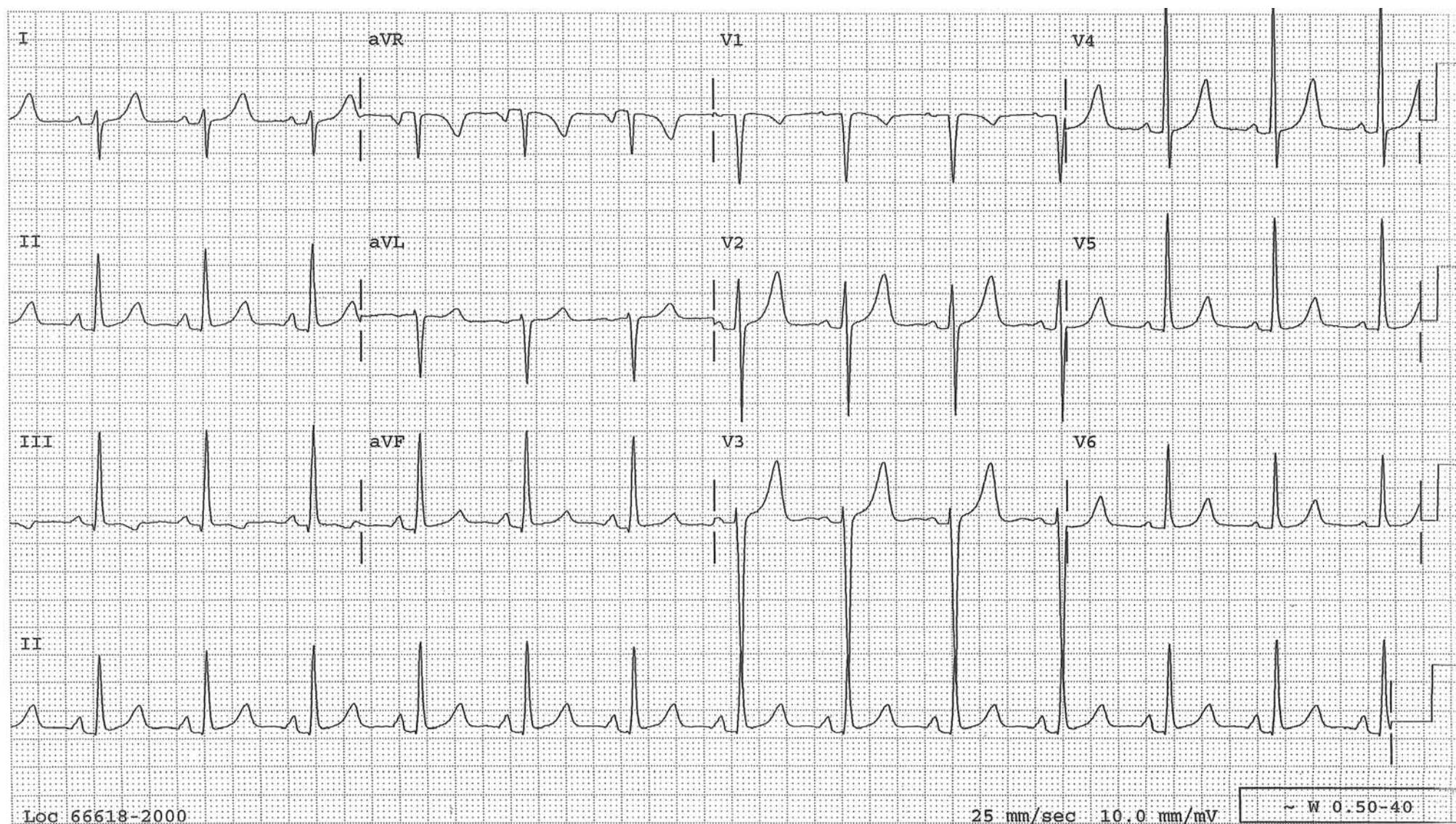
Practically, LAFB can be called just from left axis deviation (LAD) made of rS pattern in lead II unless the LAD is made of Qr pattern in lead II, in which case, it is due to inferior infarct, not LAFB. Late transition (the change of R/S ratio from  $<1$  to  $>1$  in the precordial leads) is a common accompaniment of LAFB as seen in this tracing.





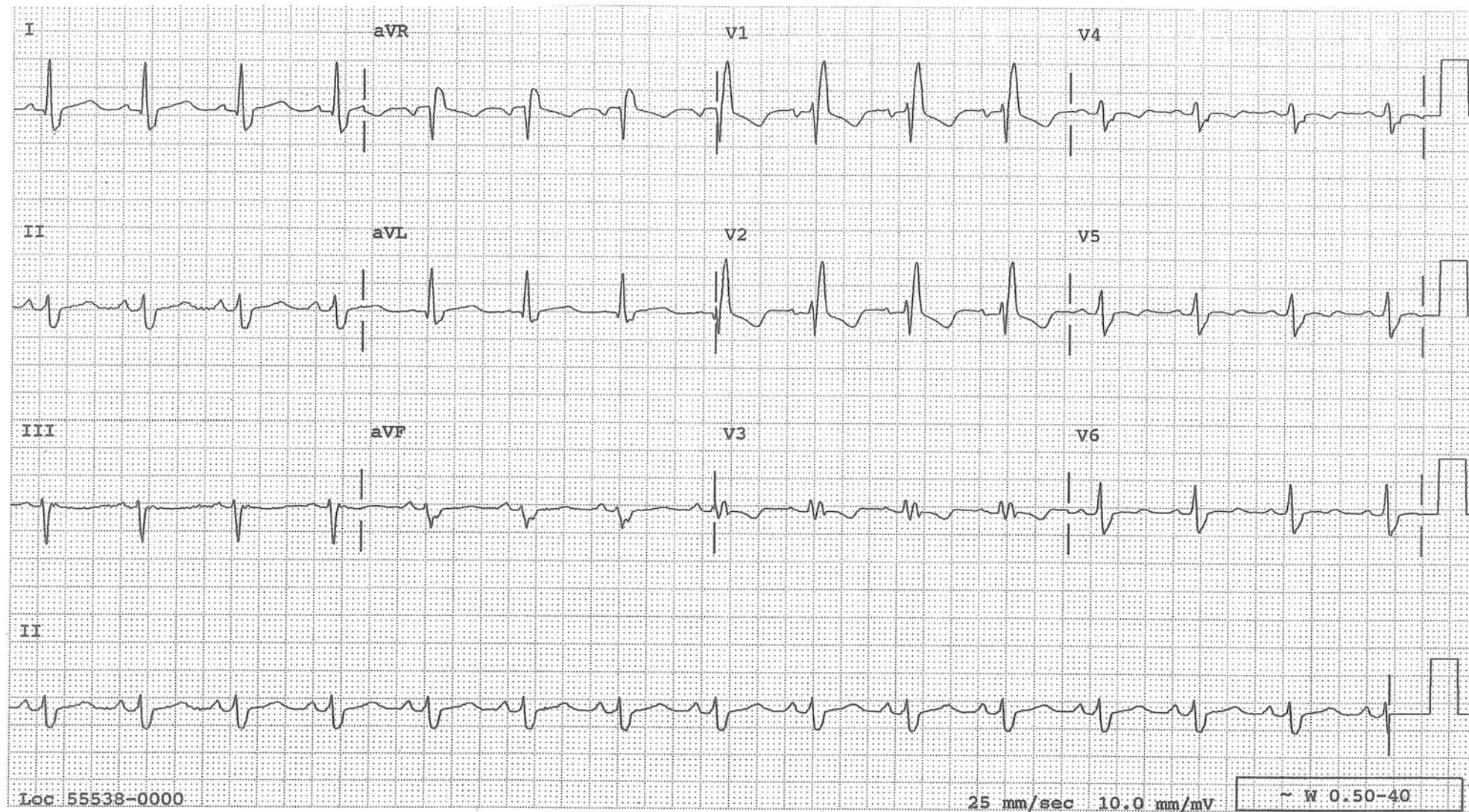
## Left Posterior Fascicular Block

The mean QRS axis is deviated rightward to about  $+120$  in the absence of a vertical heart, COPD, RVH and lateral MI





**Bifascicular Block**  
**RBBB and Left Anterior Fascicular Block**  
**(RBBB + LAD)**

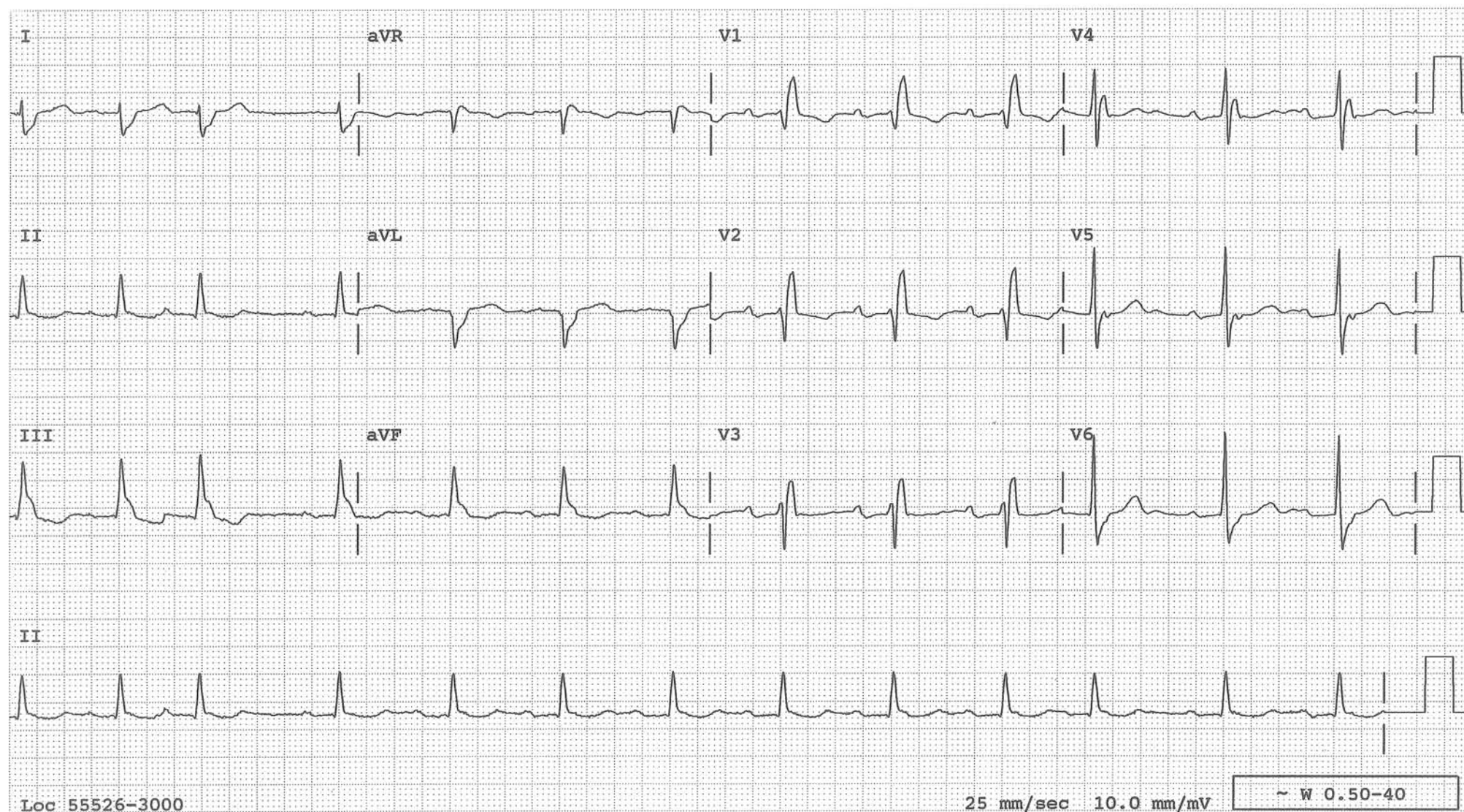




## Bifascicular Block

### RBBB and Left Posterior Fascicular Block

RBBB and RAD in which the R-wave width in lead I is less than 0.03 s. The PR interval is prolonged in this example. The PR prolongation during bifascicular block is due to prolonged conduction within the AV node in about 60% of the cases and in the other fascicle in the remainder. The former is called bifascicular block with 1° AV block, the latter is called trifascicular block, i.e. complete block in the right bundle branch and one fascicle and first degree block in the other fascicle.



## AV Block

AV block is classified into first degree (1°), second degree (2°), and third degree (3°).

In 1° AV block, every atrial impulse is conducted to the ventricle but with longer than usual ( $>0.2$  s) PR interval. The block is most often within the AV node. In patients with bifascicular block, if the PR interval is prolonged, the block is within the AV node in about 60% of cases (bifascicular block and 1° AV nodal block). In the remaining cases, the PR prolongation is due to delay of conduction in the remaining fascicle (trifascicular block, with complete block in the two fascicles and first degree block in the remaining fascicle).

In second degree AV block, some P waves are followed by QRSs while others are not. The AV conduction ratio is expressed by the number of P waves to the number of QRS(s) in a given group, e.g. 2:1, 3:1, 3:2, 5:4, etc.

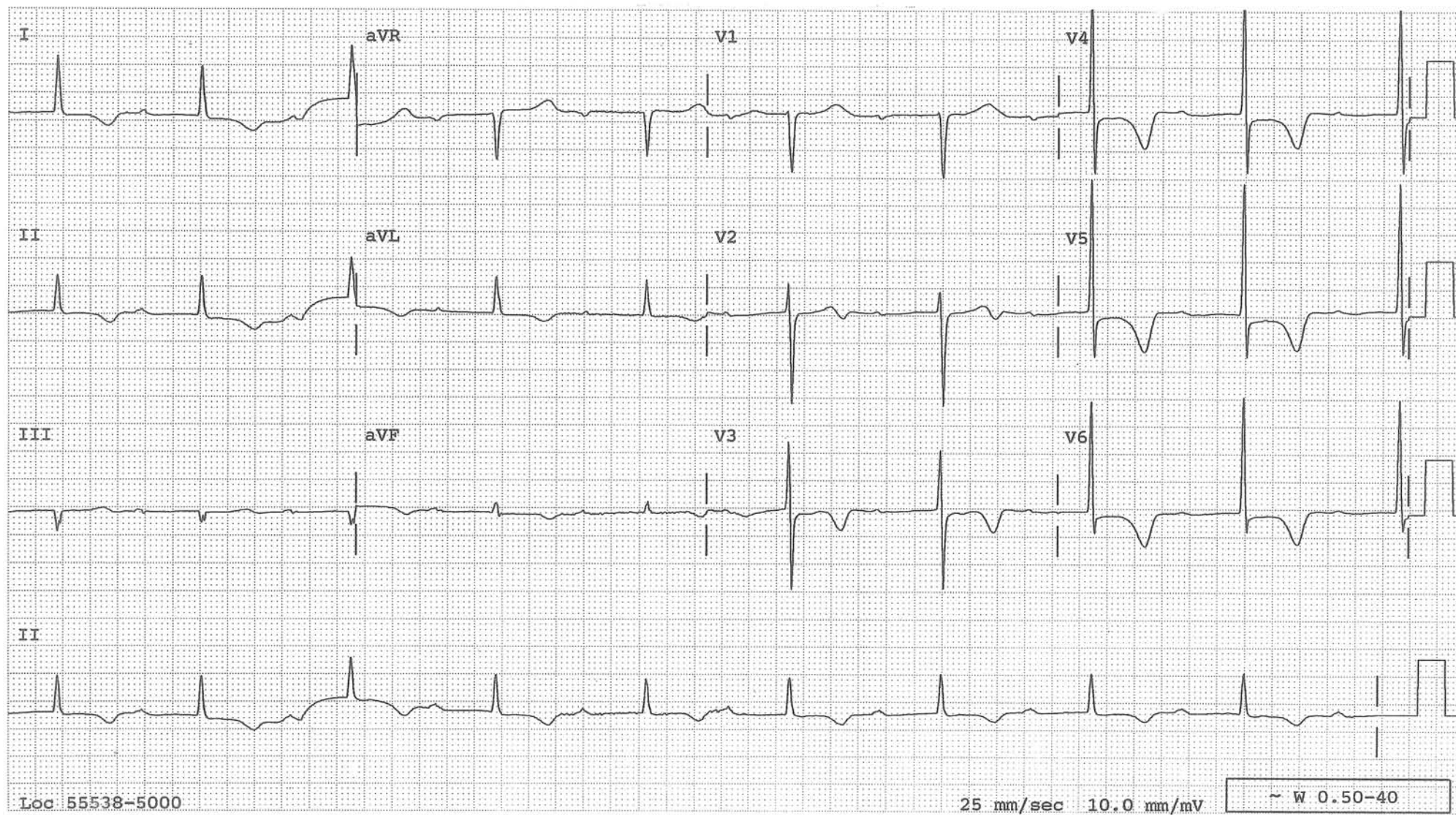
During 2° AV block, when two or more consecutive atrial impulses are conducted to the ventricle, Wenckebach, and later Mobitz, made a clinically useful observation that the PR interval behaves in two different ways: it either progressively lengthens and carries a more favorable prognosis, or it stays the same, in which case the patient is prone to syncope and the prognosis is poor. The former is called the AV Wenckebach phenomenon or Mobitz Type I 2° AV block and the latter Mobitz Type II 2° AV block. It turned out that Type I 2° AV block is most often due to block within the AV node (with some exceptions) from reversible causes, whereas Type II 2° AV block is due to block below the His bundle from nonreversible conditions, such as fibrosis or necrosis of the conduction system.

Many call 2:1 AV block type II claiming that the PR interval does not lengthen, not realizing that one needs two or more consecutively conducted beats to be able to say whether the PR interval lengthens or not. In fact, 2:1 AV block is more often a form of Type I 2° AV block with the block within the AV node. It can be considered as the shortest Wenckebach cycle, that is 5:4 AV conduction ratio becoming 4:3, then 3:2 and eventually 2:1. In that case, one may find a definite Wenckebach phenomenon in other parts of the strip or the conducted QRS is narrow and the PR interval is often long. 2:1 AV block can be due to a block below the His bundle. In that case, the conducted QRS complex is wide and the PR interval is usually normal.

In 3° AV block, no atrial impulses are conducted to the ventricle. The patient is dependent on an escape mechanism originating either from the AV junction or from the ventricle. These escape rhythms are very regular, especially if it is AV junctional. In fact, if QRSs do not occur regularly, the beat which occurs with a shorter R-R interval is probably conducted and one is no longer dealing with a complete AV block.



**1° AV Block**  
(PR interval longer than 0.20 s)



## 2° AV Block

	<i>Type I</i> <i>(Wenkebach phenomenon)</i>	<i>Type II</i>
Etiology	: Reversible conditions (e.g. drugs, vagotonic state, inflammation, ischemia or edema associated with inferior MI)	Not reversible conditions (e.g. fibrosis, necrosis from anterior MI)
Location of block	: Usually within the AV node	Below His bundle
Escape rhythm if block progresses to 3°	: AV junctional with narrow QRS; rate: 40–50 min	Ventricular with wide QRS; rate: 20–30 min
Prognosis	: Transient	Permanent



## Wenckebach Phenomenon

In a typical AV Wenckebach phenomenon, the PR intervals progressively lengthen until finally an atrial impulse is blocked completely. The PR intervals increase with decreasing increments, resulting in progressively shortened R-R intervals, as illustrated in the diagram.

If the P2-R2 interval remains the same as the P1-R1 interval, the R1-R2 interval will be the same as the P1-P2 interval (0.6 s). However, the P2-R2 interval is longer than the P1-R1 interval by 0.12s ( $\Delta 1$ ) and the R1-R2 interval is longer than the P1-P2 interval by that much. Therefore, the R1-R2 interval is  $0.6 \text{ s} + 0.12 \text{ s} = 0.72 \text{ s}$ . If the P3-R3 interval remains the same as the P2-R2 interval, the R2-R3 interval will be the same as the P2-P3 interval. However, the P3-R3 interval is longer than the P2-R2 interval by 0.06 seconds ( $\Delta 2$ ). Therefore, the R2-R3 interval is  $0.6 \text{ s} + 0.06 \text{ s} = 0.66 \text{ s}$ , which is shorter than the R1-R2 interval of 0.72 s. Again, the R3-R4 interval is the same as the P3-P4 interval plus  $\Delta 3$  (which now is only 0.02 s), and is  $0.6 \text{ s} + 0.02 \text{ s} = 0.62 \text{ s}$ . It is clear that the PR intervals lengthen progressively with each beat. They, however, lengthen with *decreasing* increments, which explains the shortening R-R intervals.

The PR lengthening is most marked between the first and second or second and third beats and the increments become less and less thereafter. Therefore, these shortening R-R intervals are most noticeable between the first and second or second and third QRS. Near the end of a Wenckebach phenomenon, the PR interval does not change appreciably and the R-R interval remains about the same as well.

By observing this unique behavior of the R-R intervals in the Wenckebach phenomenon, the phenomenon can be suspected even when no P waves are present to appreciate the lengthening PR intervals, such as in AV junctional tachycardia with Wenckebach phenomenon during atrial fibrillation or type I SA block.

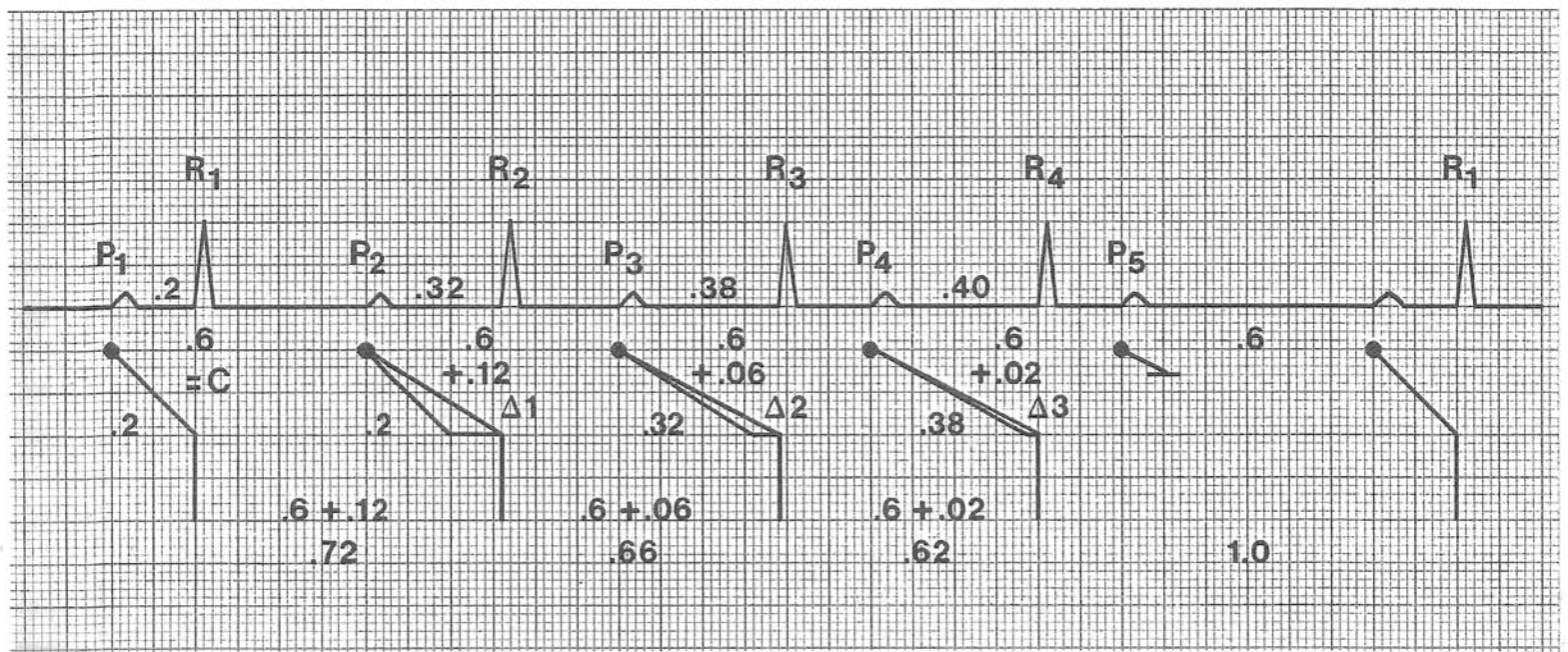
On rare occasions, the last conducted beat in a Wenckebach period may have a larger PR increment than the preceding PR interval, and the R-R interval, instead of remaining the same or further shortening, may actually lengthen.

The first QRS after the blocked P wave is usually the first QRS of the next Wenckebach period, i.e. a complex induced by the sinus impulse. However, occasionally it may originate from the AV junction. In the latter case, if the AV junctional beat occurs with an effective rate of 40-50/min, it is merely an escape beat. If the effective rate is greater than 60/min, then the AV junctional pacemaker is called "accelerated." The cause for this should be determined in addition to the cause of the Wenckebach phenomenon. Digitalis intoxication and inferior myocardial ischemia or infarction can cause both.

Even though the Wenckebach phenomenon was originally described in association with AV block, the phenomenon has been observed in the SA junction, within the His bundle, within the right bundle branch, within the left bundle branch, and within the purkinje system.

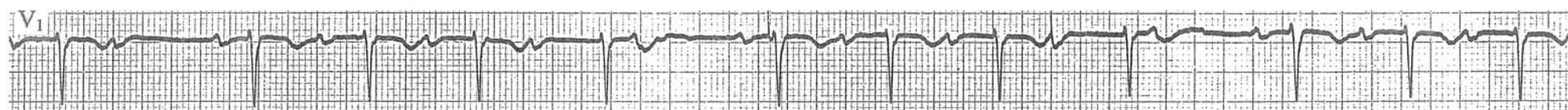
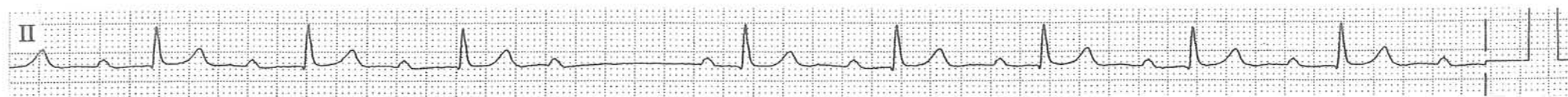
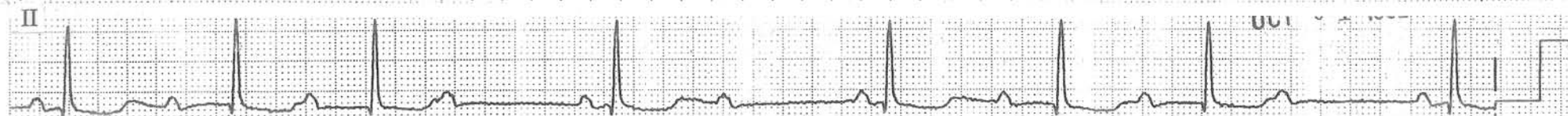
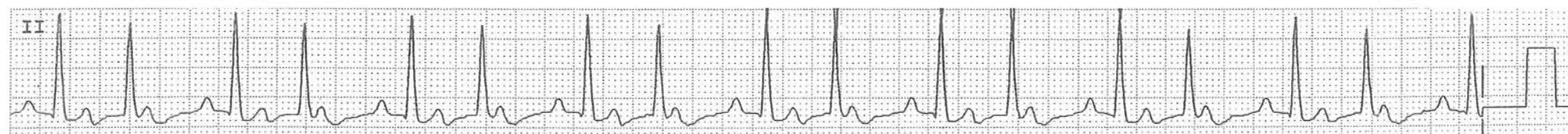
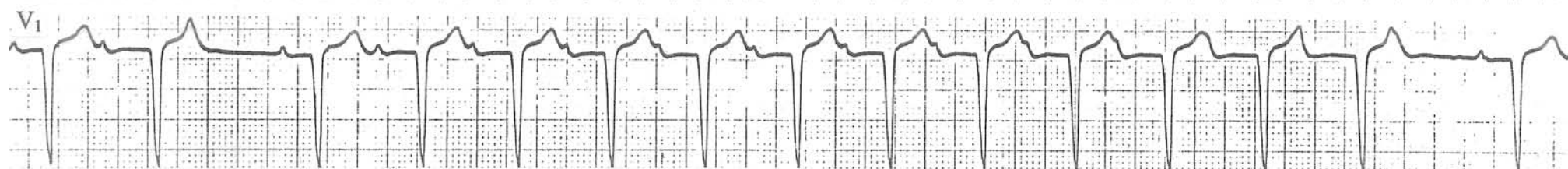
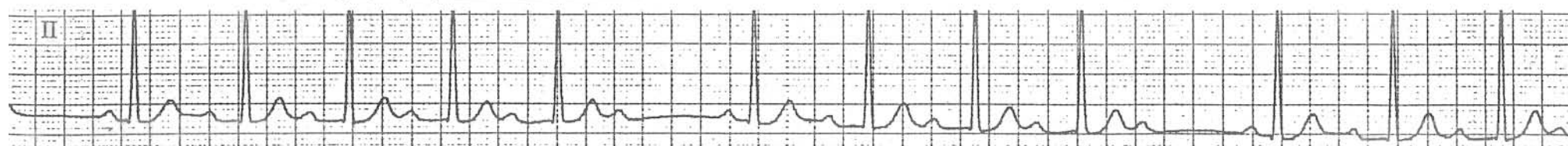
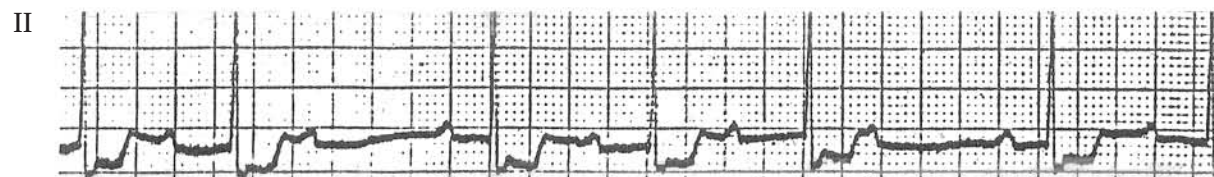
(See diagram on the next page)

$$\begin{aligned}
 R_1 R_2 &= C (P_1 P_2) + \Delta 1 \\
 R_2 R_3 &= C + \Delta 2 \\
 R_3 R_4 &= C + \Delta 3
 \end{aligned}
 \quad C: \text{constant}$$

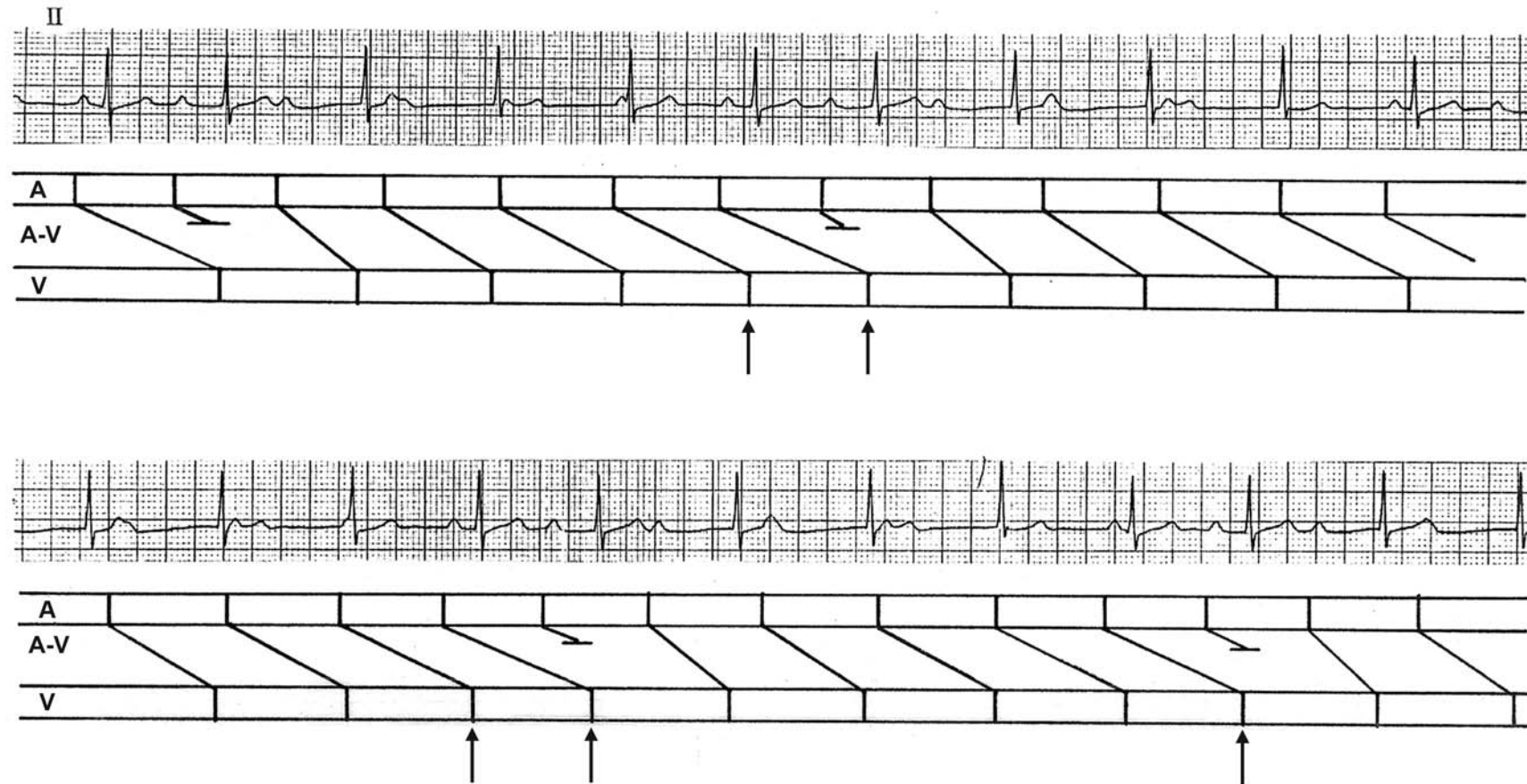




### Examples of AV Wenckebach Phenomenon (Type I 2° AV block)



## An atrial impulse conducting not to the next QRS but to the one after that

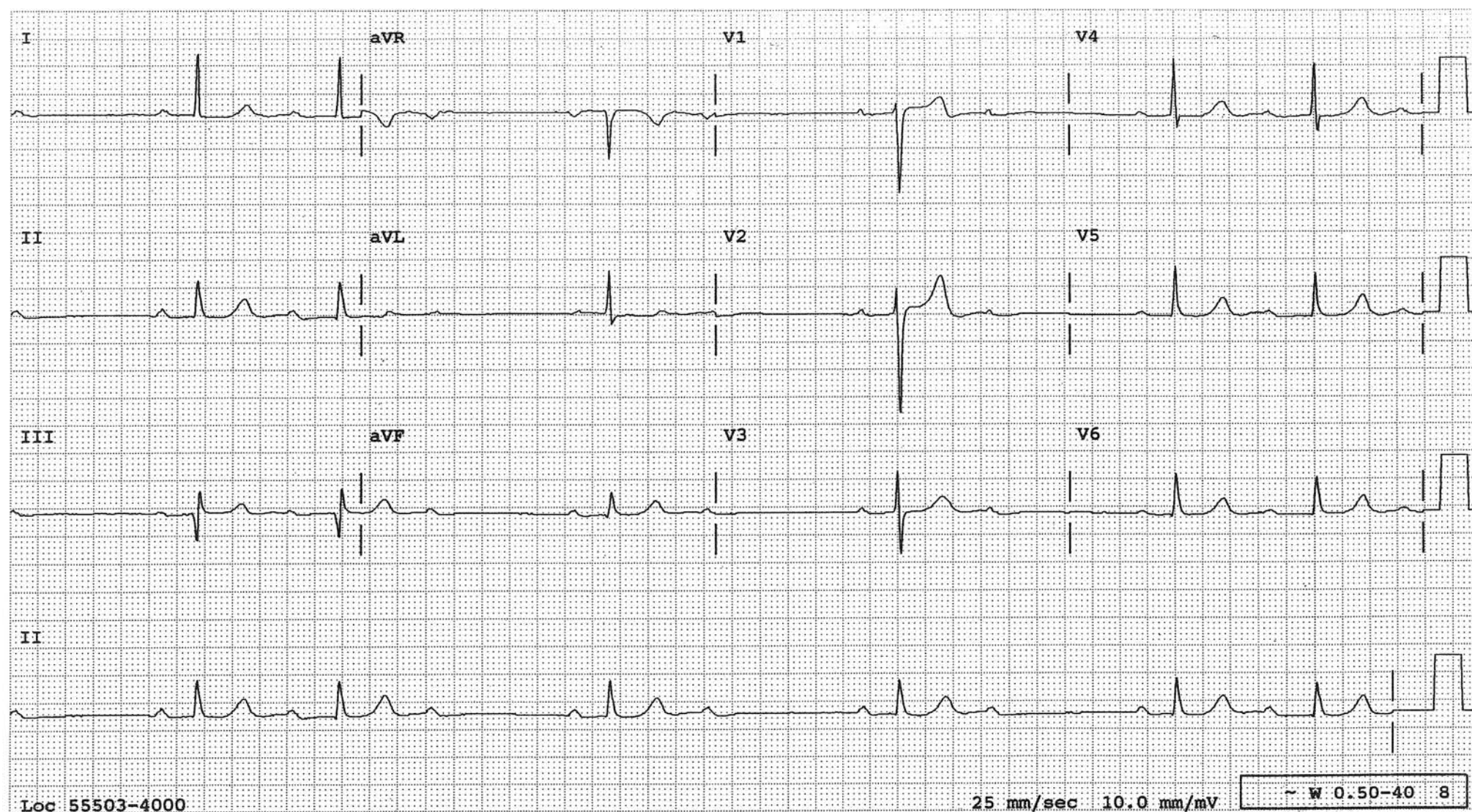


An interesting manifestation of the AV Wenckebach phenomenon, in which the atrial impulse is sometimes conducted not to the next QRS but to the one after that (↑) as diagrammed. At a quick glance, one could wonder how an impulse from the P wave could “jump over” a QRS and conduct to the next one, but the ladder diagram helps us understand the phenomenon. This situation is akin to a city bus dispatcher sending out a bus before the bus in front has reached its destination.



## Type I 2° AV Block Throughout

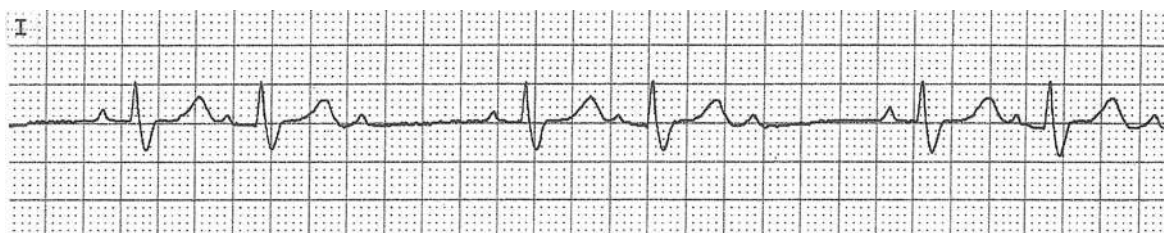
An AV Wenckebach phenomenon is evident in the first and last part of the tracing and 2:1 AV block is evident in the middle. This is sometimes erroneously interpreted as Type I and Type II 2° AV block in the same tracing, while it is actually type I 2° AV block throughout. 2:1 AV block may be due to block within the AV node or below the His bundle. In 2:1 AV block, if the conducted complex has a long PR interval and the QRS is narrow, the block is more likely within the AV node. If there is a definite AV Wenckebach phenomenon in other parts of the strip, it is certain that the location of the block is within the AV node (type I). This tracing is from a patient with an acute inferior myocardial infarction with Type I 2° AV block in which case the block is within the AV node. As expected in the setting of an inferior myocardial infarction, the AV block in this patient was transient.





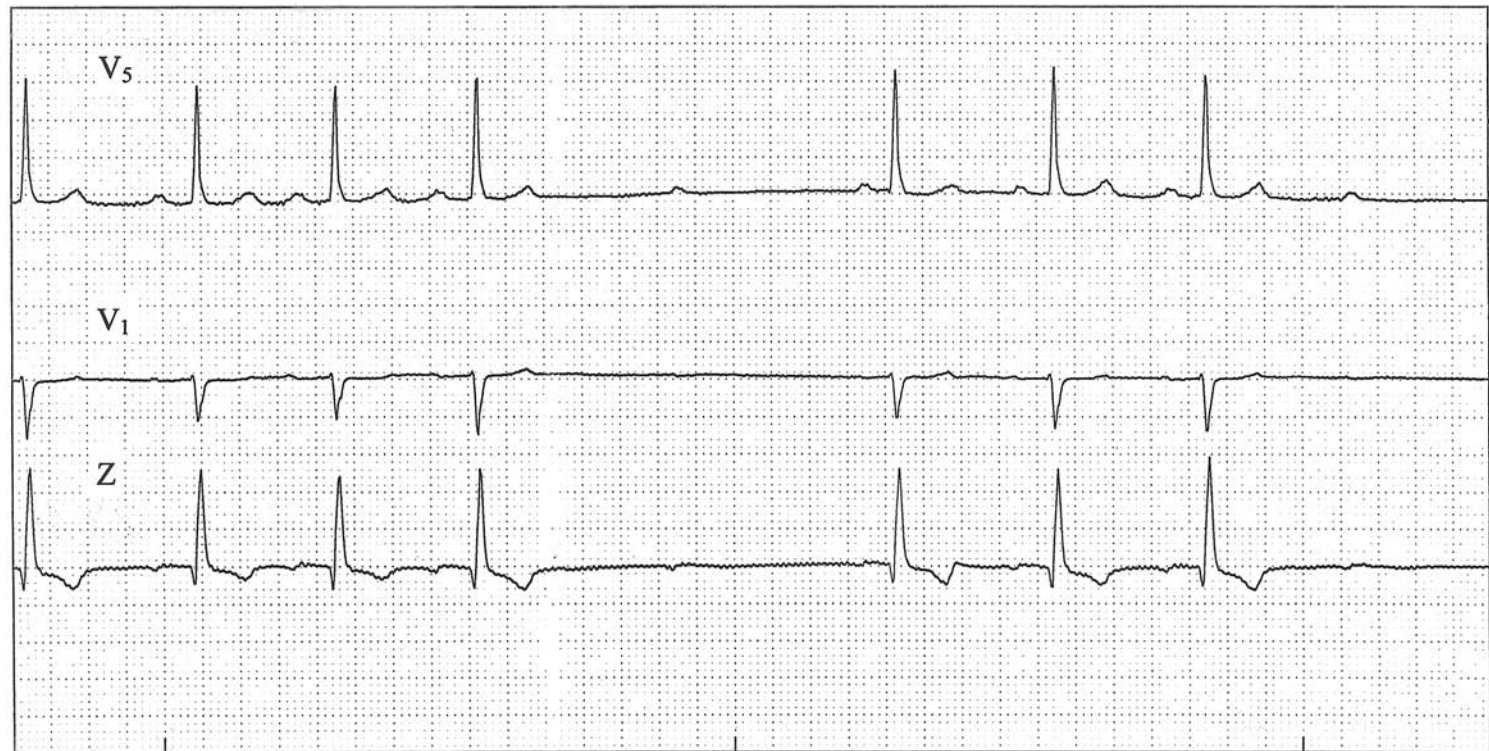
## 2° AV Block, Type II

Every third P wave fails to conduct to the ventricles (3:2 AV block) while the PR interval of the conducted beats does not change appreciably: 2° AV block, type II. In type II 2° AV block, intraventricular conduction defect is also commonly present and the QRSs are wide as in this case.



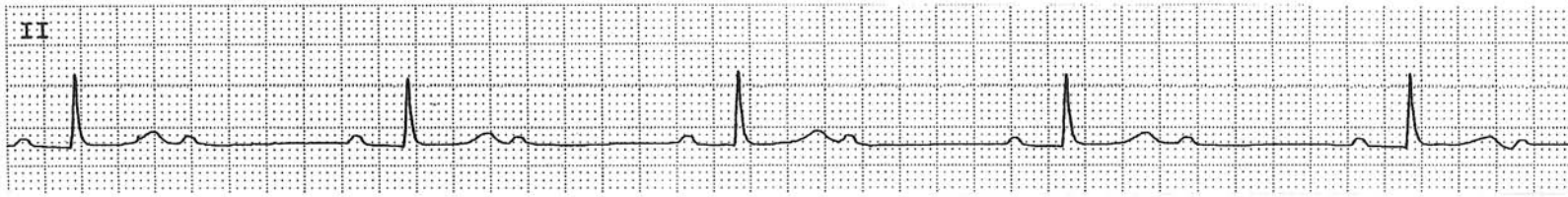
### “Pseudo” Type II 2° AV Block Due To Transient Vagotonia

Three channel rhythm strips taken simultaneously reveal intermittent 2° AV block. The PR interval does not lengthen prior to the “dropped” beat, raising the possibility of Type II 2° AV block. However, the P to P interval lengthens around the time when the atrial impulse is blocked, suggesting that it is not an intrinsic AV conduction problem, but that some force extrinsic to the heart is affecting both the sinus node to slow down and the AV node to block at the same time. This is an example of AV nodal block secondary to transiently increased vagal tone and is a benign condition. This tracing should not be interpreted as Mobitz type II 2° AV block which usually requires a permanent pacemaker. When an atrial impulse is blocked unexpectedly, paying close attention to the P to P interval can be useful, as in this case.

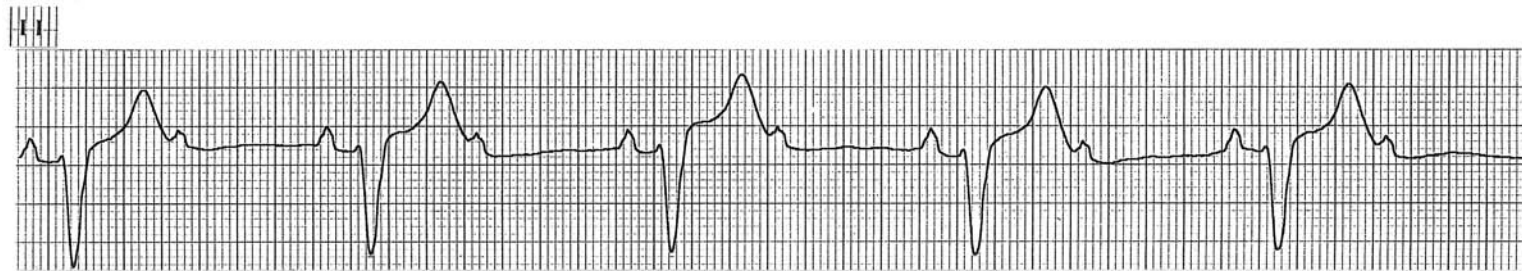



**2:1 AV block with narrow QRSs. Note also the PR interval is long.  
The block is more likely within the AV node (Type I)**

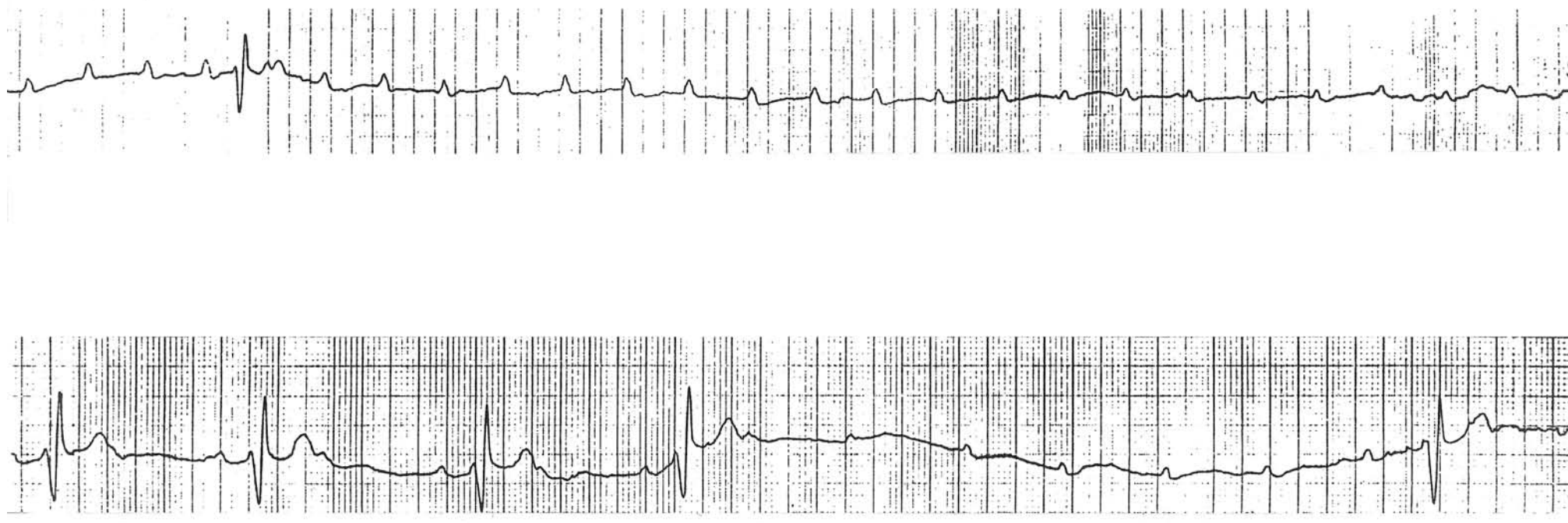


**2:1 AV block with wide QRSs. Note that the PR interval is not long.  
The block is most likely below the his bundle (Type II)**



**Bifascicular block with intermittent high grade AV block causing syncopal episodes**

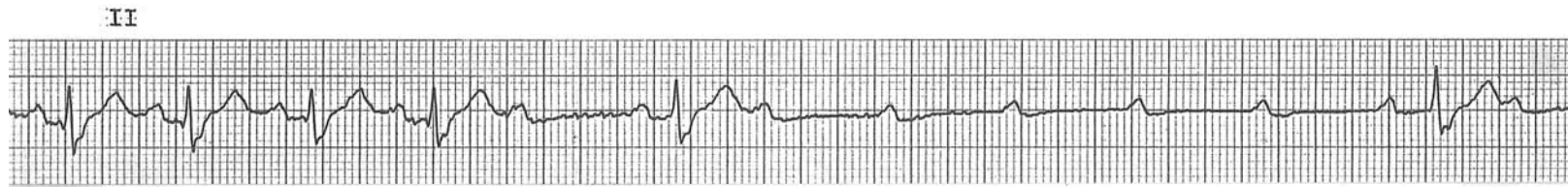
MCL1





## High Grade AV Block

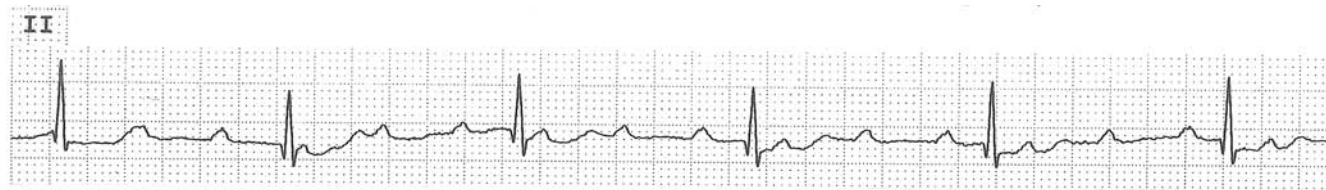
(Initially every atrial impulse is conducted to the ventricles while many consecutive atrial impulses are blocked later.)



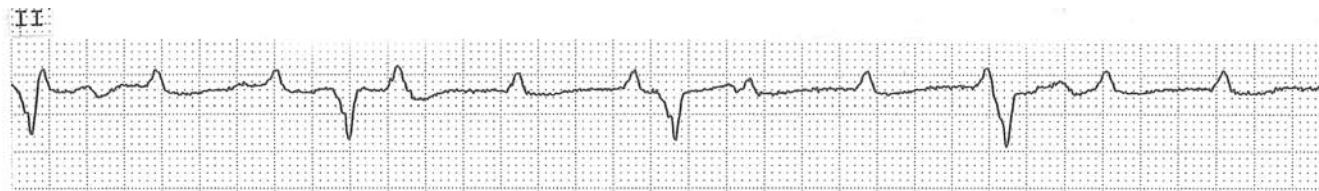
## 3° (Complete) AV Block

- No atrial impulses are conducted to the ventricles
- Escape rhythm is very regular, especially if it is AV junctional rhythm

Complete (3°) AV block with AV junctional escape rhythm

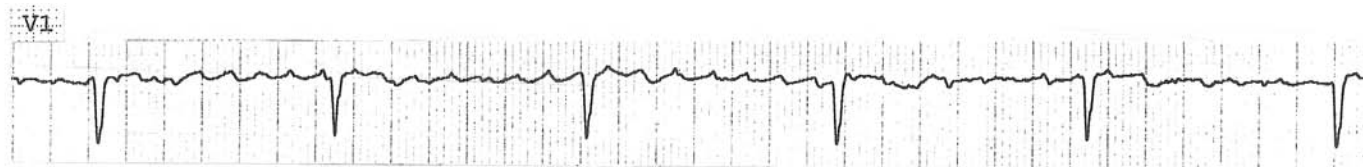

Complete (3°) AV block with ventricular escape rhythm



Atrial fibrillation with complete (3°) AV block and AV junctional escape rhythm.

Note the QRSs are narrow and occur regularly.



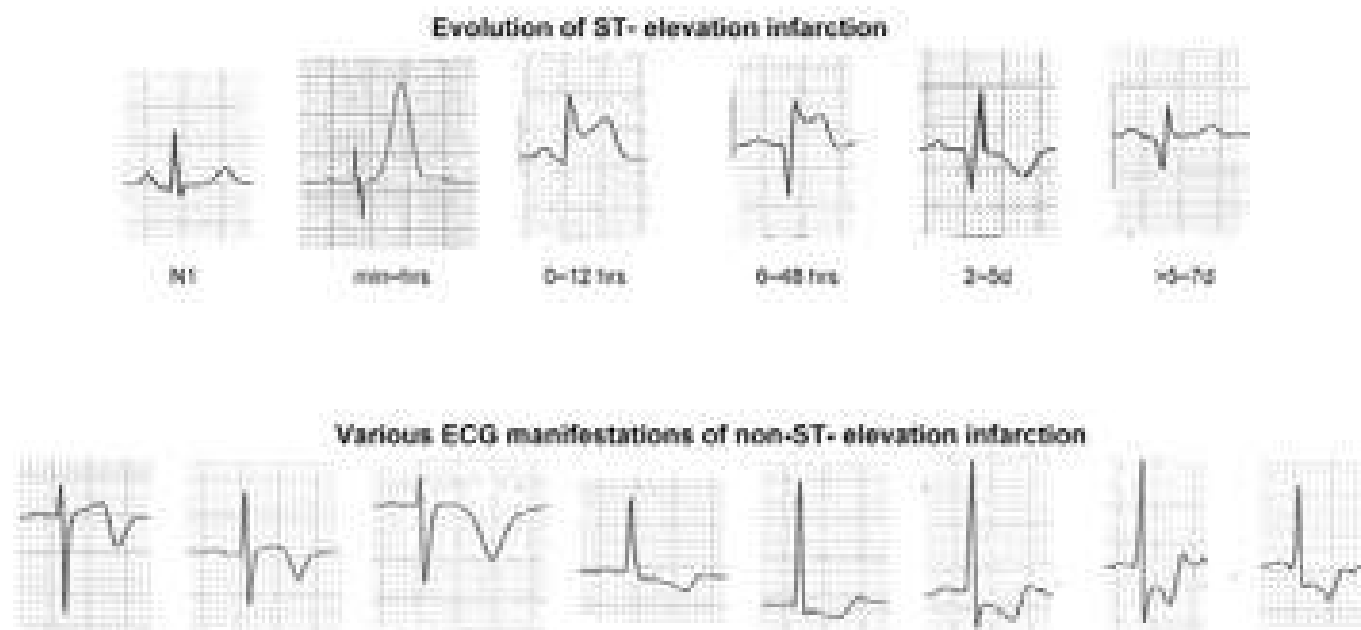
## Myocardial Infarction

Myocardial infarction is called either Q-wave or non-Q-wave infarction depending upon whether it results in pathologic ( $>0.03$  s) Q waves or not. A thrombus occluding the coronary artery lumen completely results in an infarct which involves full or nearly full thickness of the ventricular wall and more often results in Q-wave infarction. The infarcted area becomes electrically silent and the initial vector of the QRS is pointed away from the electrodes facing this area, resulting in Q waves. When the coronary artery is occluded partially by a thrombus and the resulting infarct involves a smaller area, e.g., subendocardial layer, non-Q-wave infarction results.

On the ECG, Q-wave infarction manifests initially as tall T waves (hyperacute T wave changes), then ST-segment elevation (current of injury), appearance of Q waves, reduction of ST-segment elevation with the beginning of T-wave inversion, then normalization of all of these changes except for the Q waves in that sequence as illustrated below. In 20–30% of the patients, the abnormal Q waves disappear eventually. All Q-wave infarctions begin with ST elevation, but not all ST-segment-elevation infarctions result in Q-wave infarctions, especially with early reperfusion. Therefore, at an early stage, the infarction is now called either ST-elevation infarction or non-ST elevation infarction. Sometimes, the ST-segment elevation represents transmural ischemia without myocardial injury during coronary artery spasm (Prinzmetal's angina).

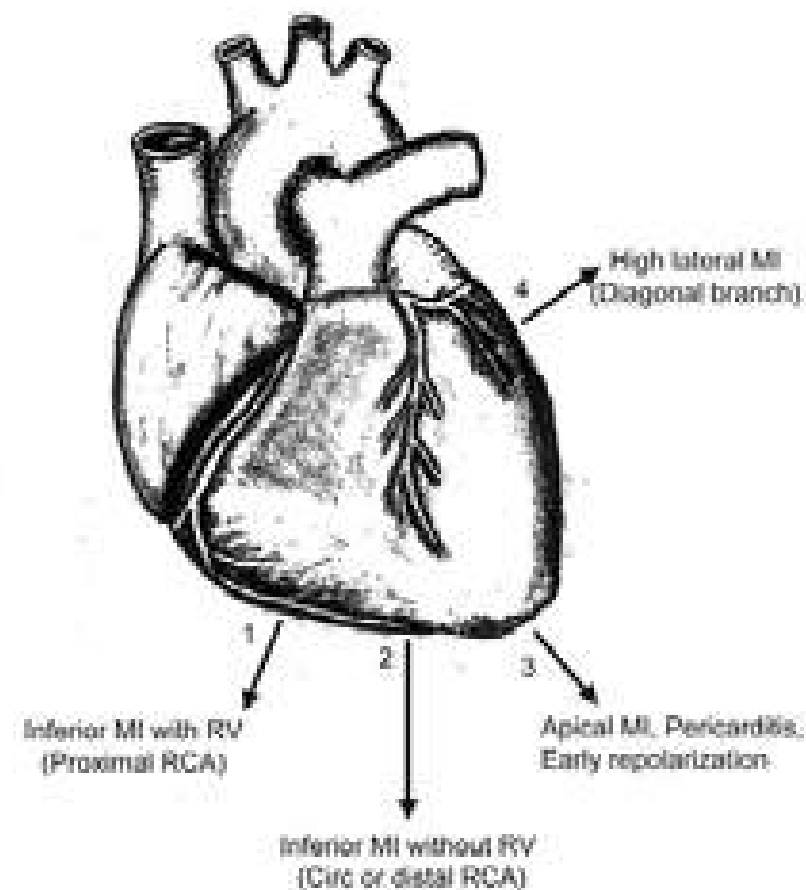
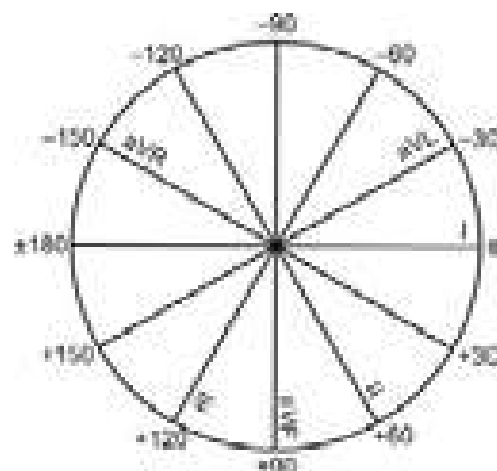
Non-Q-wave infarction manifests as ST-segment depression or T-wave inversion as illustrated below.

Since these ECG changes are reflected in the leads facing the infarcted area, naturally inferior infarction will manifest in leads II, III, and aVF (also called inferior leads), anteroseptal infarction in  $V_{1-3}$ , anterolateral infarction in  $V_{4-6}$ , extensive anterior infarction in many of these precordial leads, high lateral infarction in leads I and aVL, right ventricular infarction in the right-sided precordial leads, and posterior infarction in  $V_{1-2}$  (reciprocally).





## Axis of the ST-Segment Shift in Various Conditions



Once the axis of the ST-segment deviation is determined, how it will register in various limb leads is automatic.

In inferior MI with RV involvement (proximal RCA occlusion), ST axis (1) is close to lead III axis (down and to the right).

Therefore, ST  $\uparrow$  III > II, ST  $\downarrow$  in aVL as well as in I

In inferior MI without RV involvement (circumflex artery occlusion or RCA not proximal), ST axis (2) is close to lead aVF axis (straight down).

Therefore, ST  $\uparrow$  III = II, ST  $\downarrow$  only in aVL, not in I

In high lateral MI, the ST axis (4) is close to lead aVL axis.

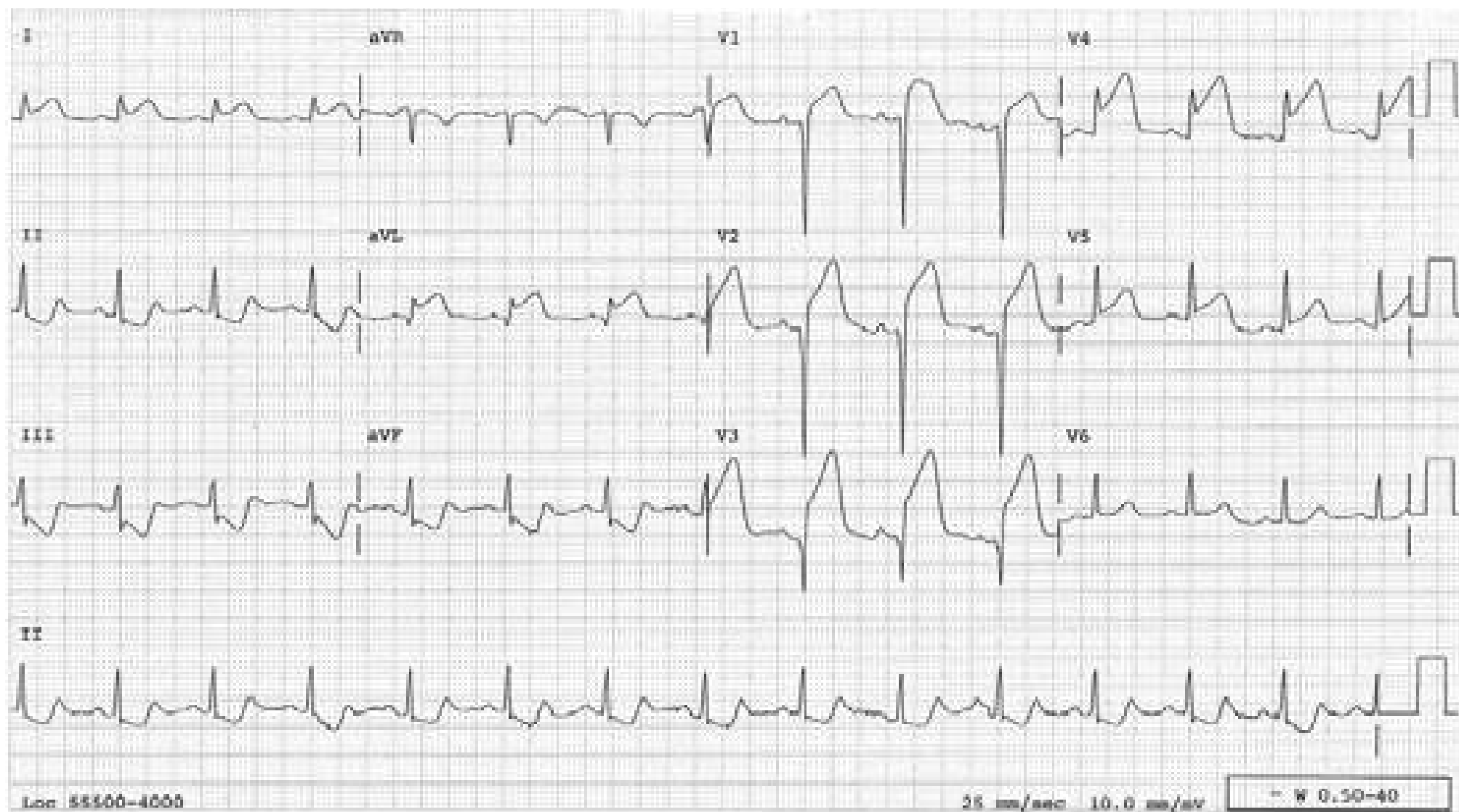
Therefore, ST  $\uparrow$  in aVL, ST  $\downarrow$  in III

In pericarditis, early repolarization or apical MI, the ST-axis (3) is parallel to the anatomical axis of the heart, which is close to 45°.

Therefore, ST  $\uparrow$  II > III and aVL, ST  $\downarrow$  in aVR

## Acute Anterior Infarct

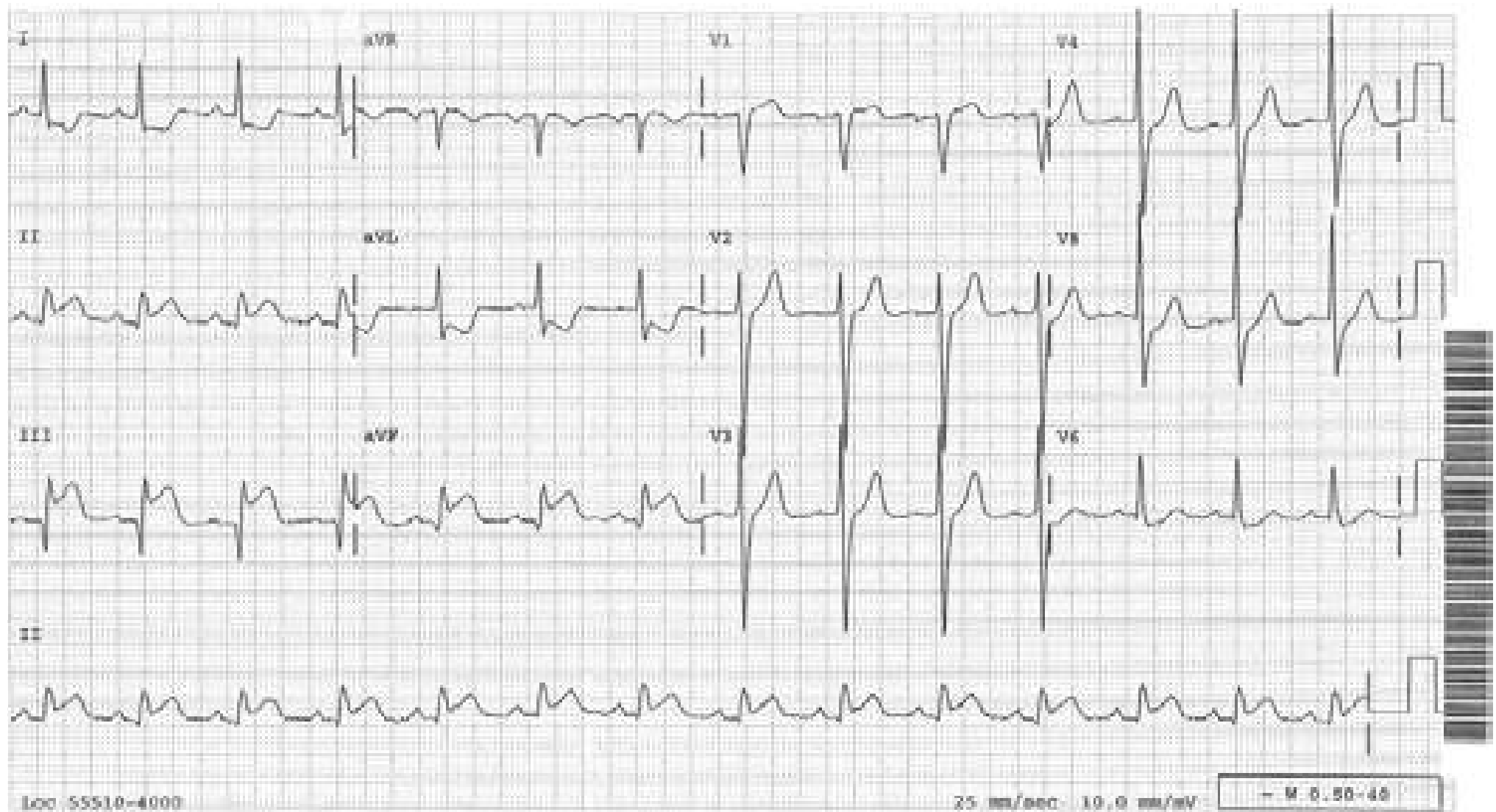
ST-segment elevation in V1-5 from acute, extensive anterior MI. ST segment is also elevated in leads I and aVL indicating the involvement of high lateral wall, which is perfused by the first diagonal branch. This branch takes off from proximal LAD. Therefore, the culprit lesion is in the proximal LAD. When the ST segment is elevated in aVL from MI, it has no other way to manifest but as ST depression in lead III, an obligatory reciprocal phenomenon. There is nothing wrong with the inferior wall. (In anterior MI, reciprocal ST depression in inferior leads occurs only if aVL is involved).





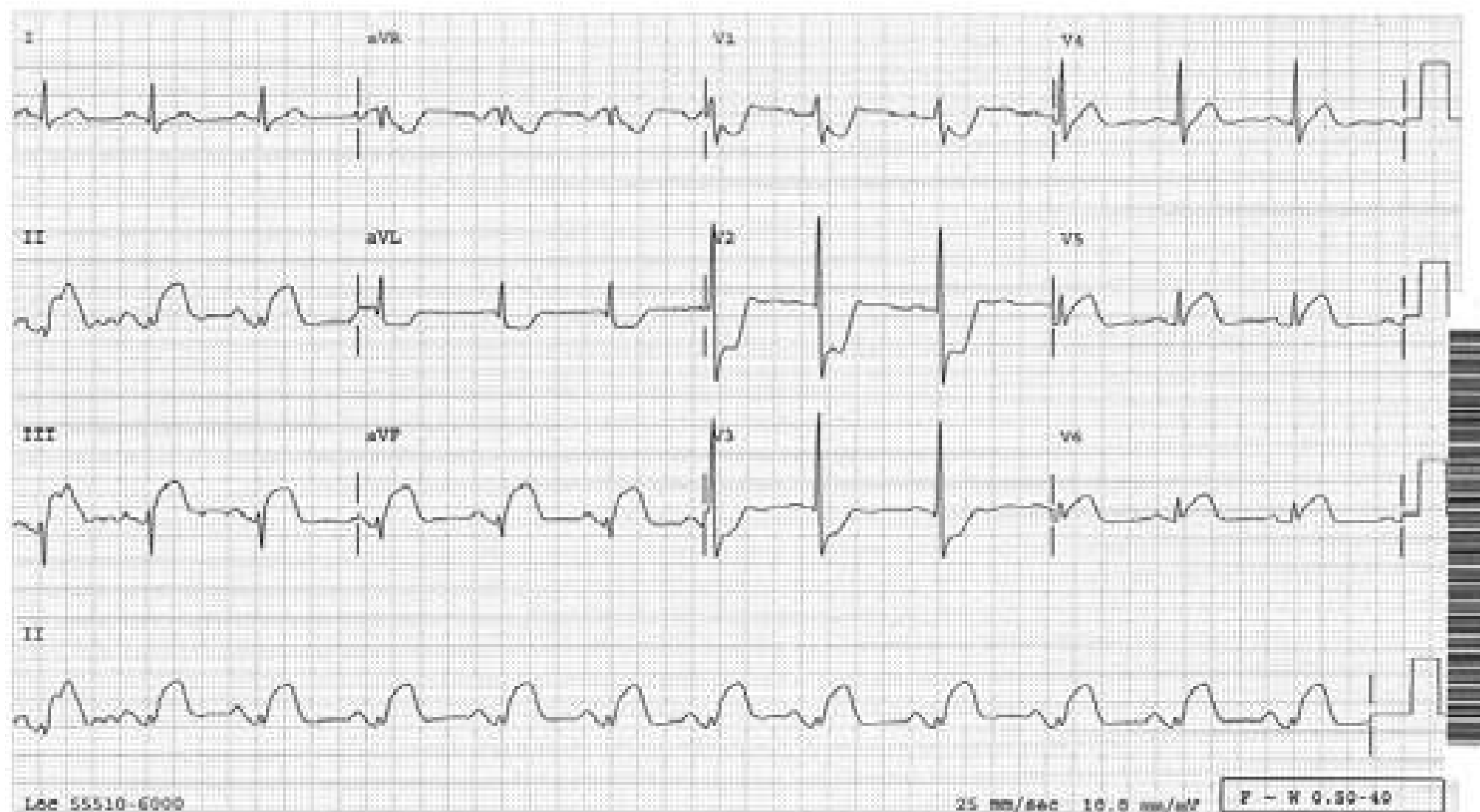
## Acute Inferior MI

ST-segment is elevated in inferior leads from acute inferior MI. This ST elevation always registers as ST depression in aVL – an obligatory, reciprocal phenomenon. Since the ST segment is depressed in lead I as well, this infarction involves RV and is due to proximal RCA occlusion. If it is due to circumflex artery occlusion or RCA not proximal, the ST segment is not deviated in lead I. Leads V1-3 are not the reciprocal leads of the inferior wall. Rather they are the reciprocal leads of the posterior wall. Therefore, ST segment is not depressed in these leads unless the posterior wall is involved.



## Acute Infero-postero-lateral MI

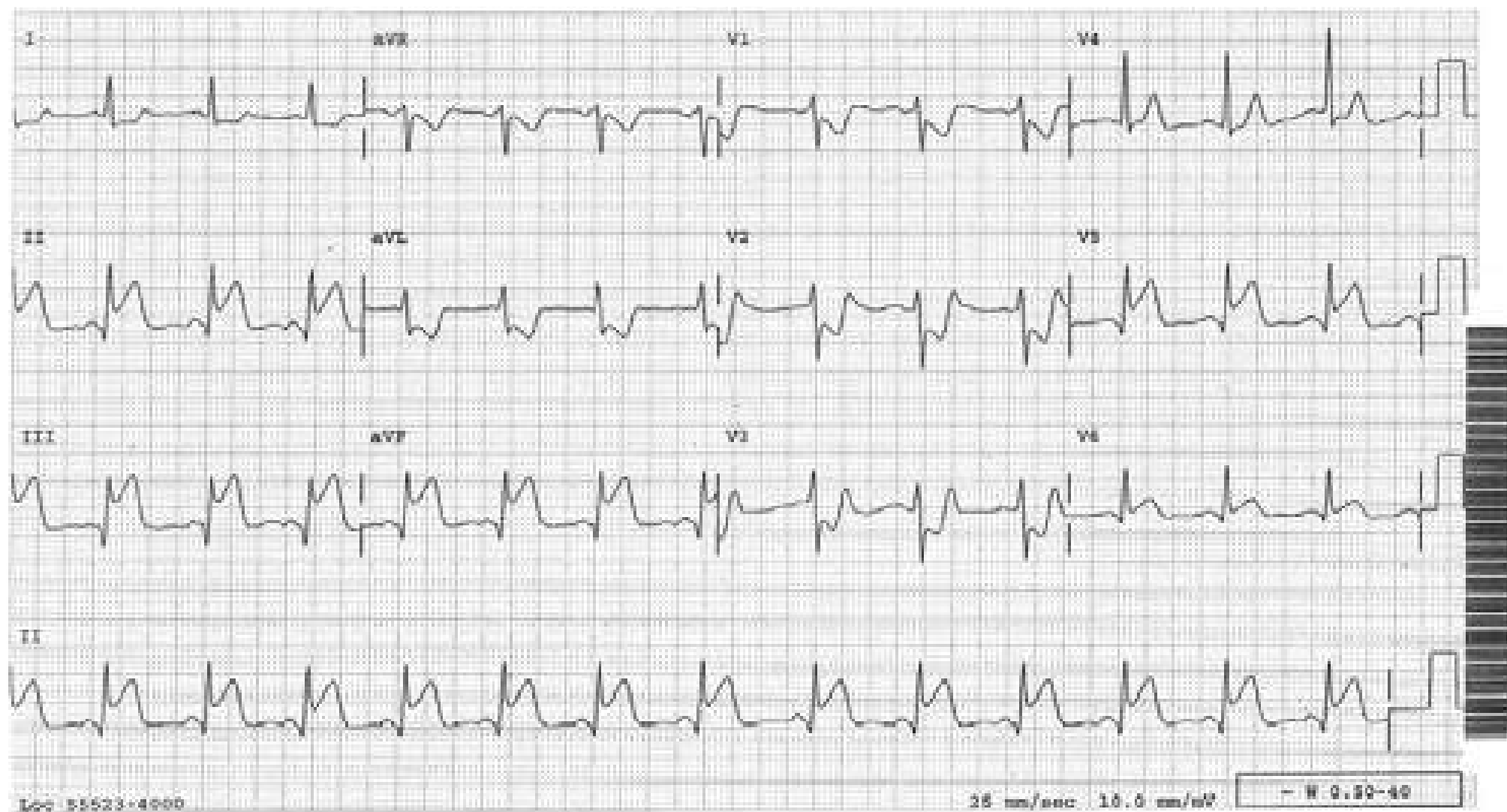
ST elevation in the inferior leads indicates acute inferior MI. Unlike in the case of the preceding tracing, the ST segment is depressed only in aVL, and not in lead I, indicating the RV is not involved and the culprit vessel is either the circumflex coronary artery or RCA not proximal. ST depression in V1-3 reflects ST elevation infarction of the posterior ventricular wall registered reciprocally. ST elevation in V5-6 indicates lateral wall involvement as well. Therefore, this infarction is called acute infero-postero-lateral infarction.





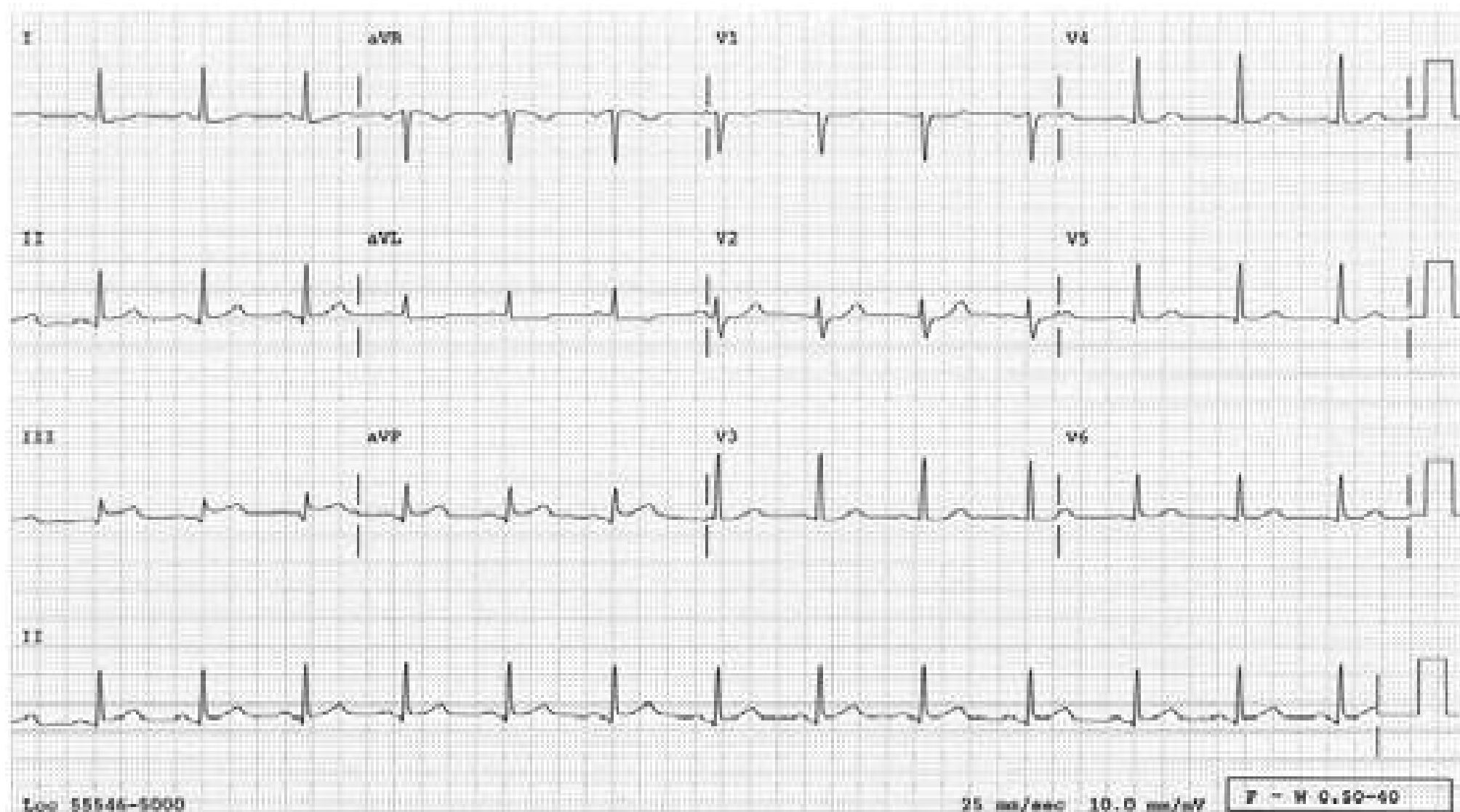
## Acute Infero-post-lateral MI

Same acute infero-post-lateral infarction as in the preceding case. Note that the ST segment is depressed in both leads aVL and I indicating RV involvement due to occlusion of the proximal RCA. Thus, the fact that the lateral wall is involved does not necessarily favor circumflex coronary artery occlusion. It is lead I that holds the key as to which vessel is involved; ST depression in lead I indicates proximal RCA occlusion. If not, either circumflex artery or RCA not proximal.



## Acute Inferior MI

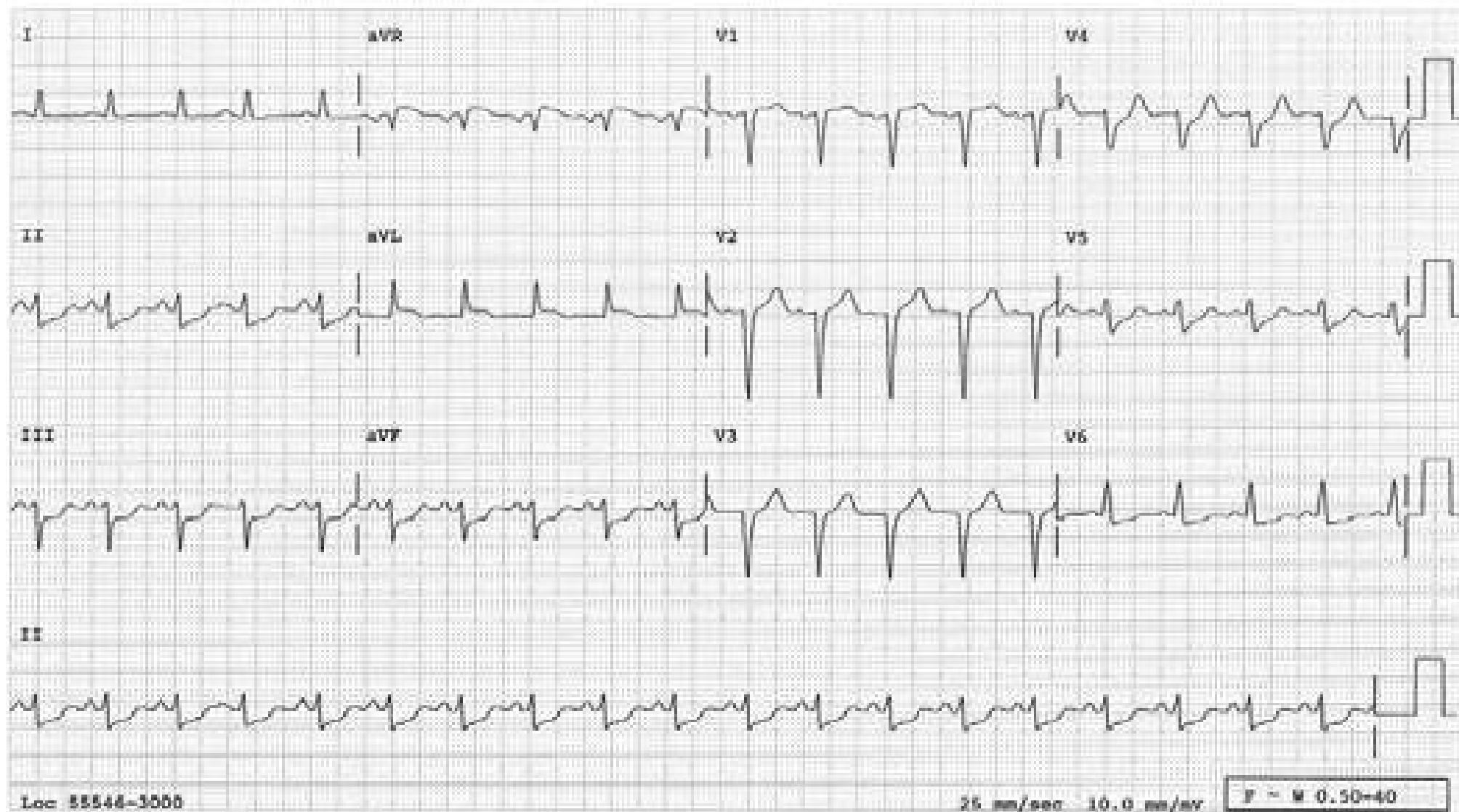
Acute inferior MI in which the ST-segment elevation in the inferior leads is not impressive. However, the fact that there is a reciprocal ST depression in aVL is consistent with acute inferior MI rather than other conditions such as pericarditis or early repolarization.





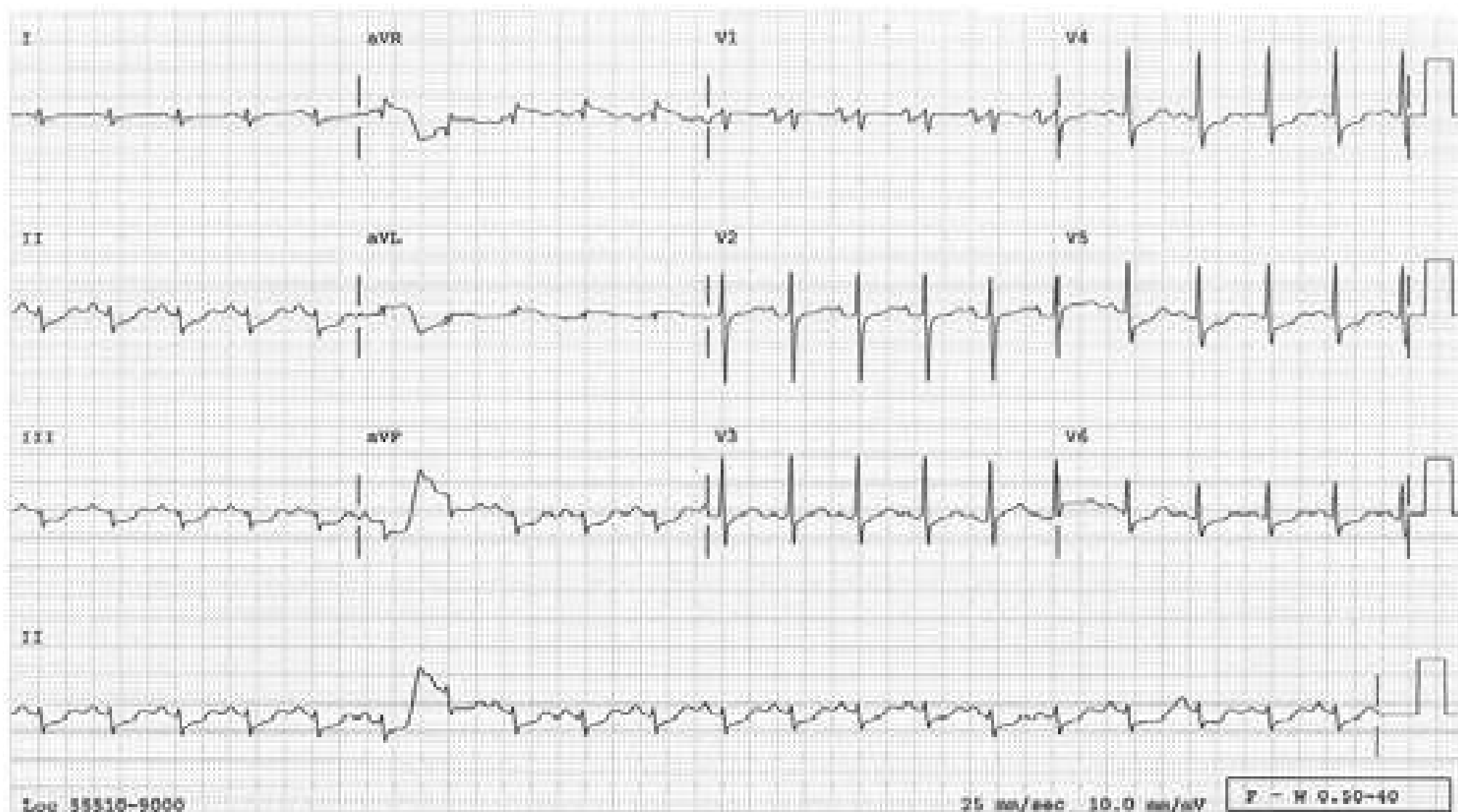
## Acute High Lateral MI

Acute high lateral MI in which the reciprocal change (ST-segment depression) in the inferior leads is more impressive than the primary change (ST-segment elevation) in lead aVL.



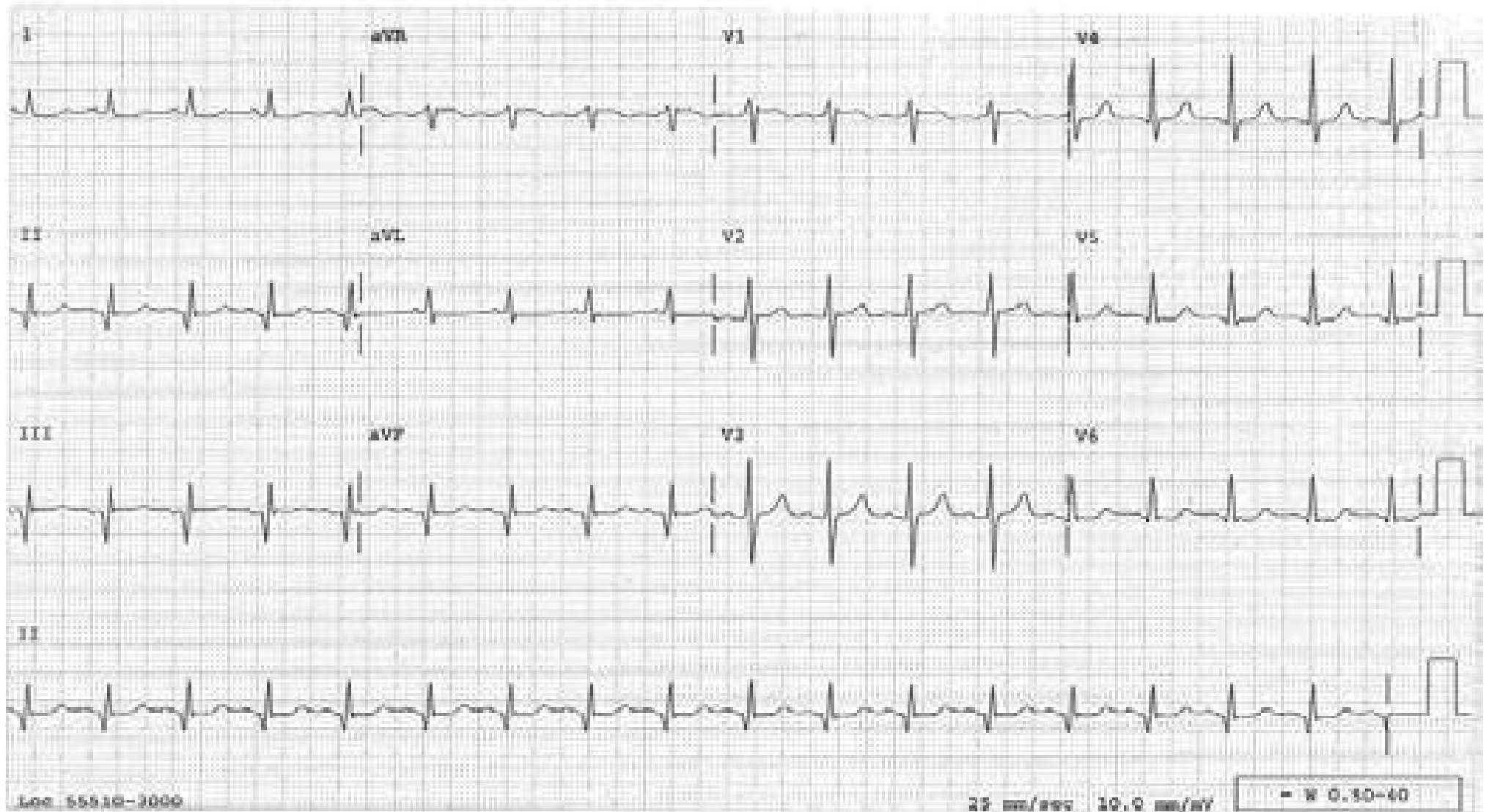
## Acute High Lateral MI

Acute lateral MI in which the reciprocal change (ST-segment depression) in the inferior leads is more impressive than the primary change (ST-segment elevation) in lead aVL. When the entire QRS complex is small as in this case, the ST segment can't be expected to deviate much more than this.



## Inferior MI, Old

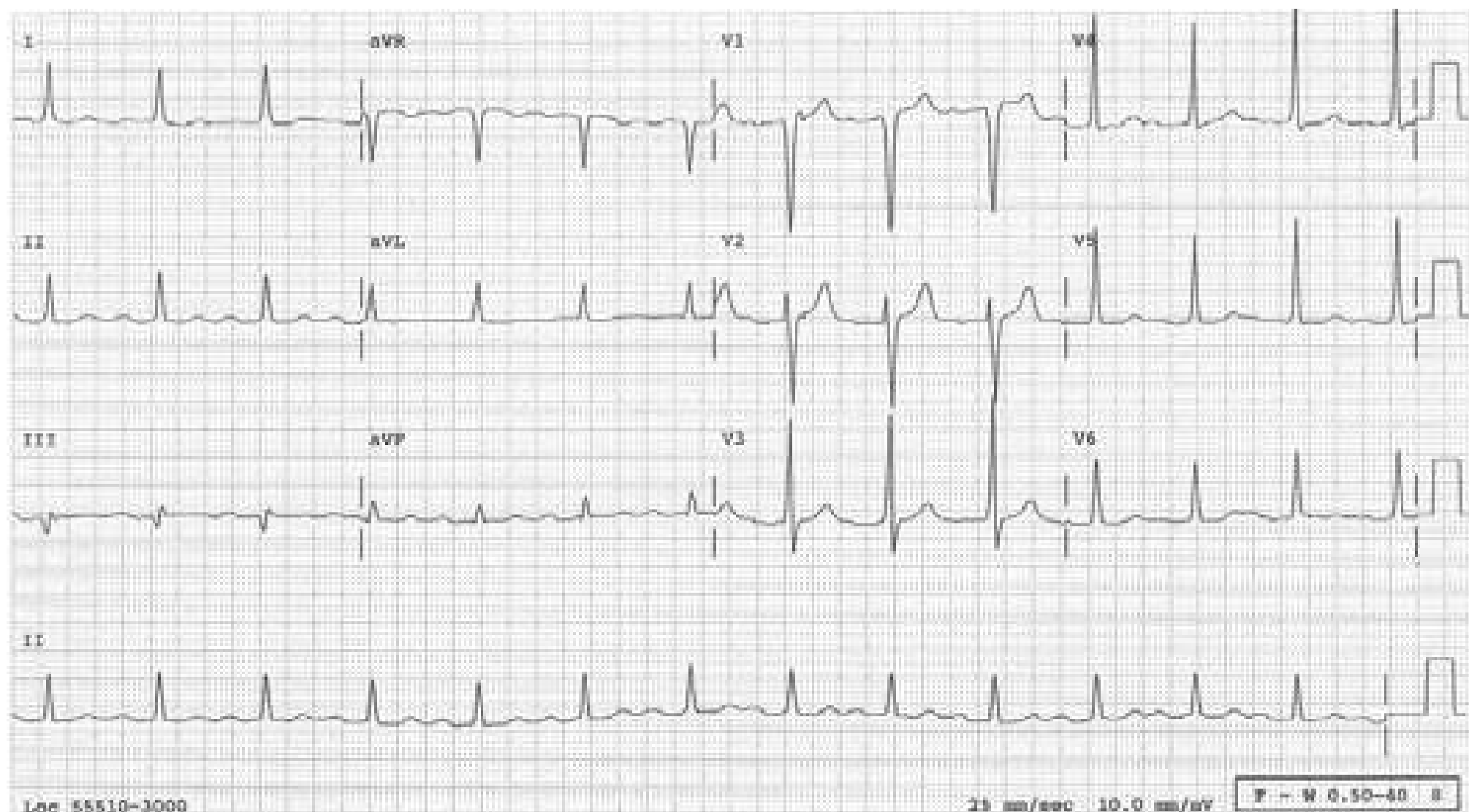
Note that Q waves in the inferior leads are wider than 0.04 s and deeper than 1/3 the height of the R waves, indicating that these are not normal septal Q waves, but are diagnostic of an inferior MI. The lack of ST elevation or T-wave inversion indicate the infarct is old.





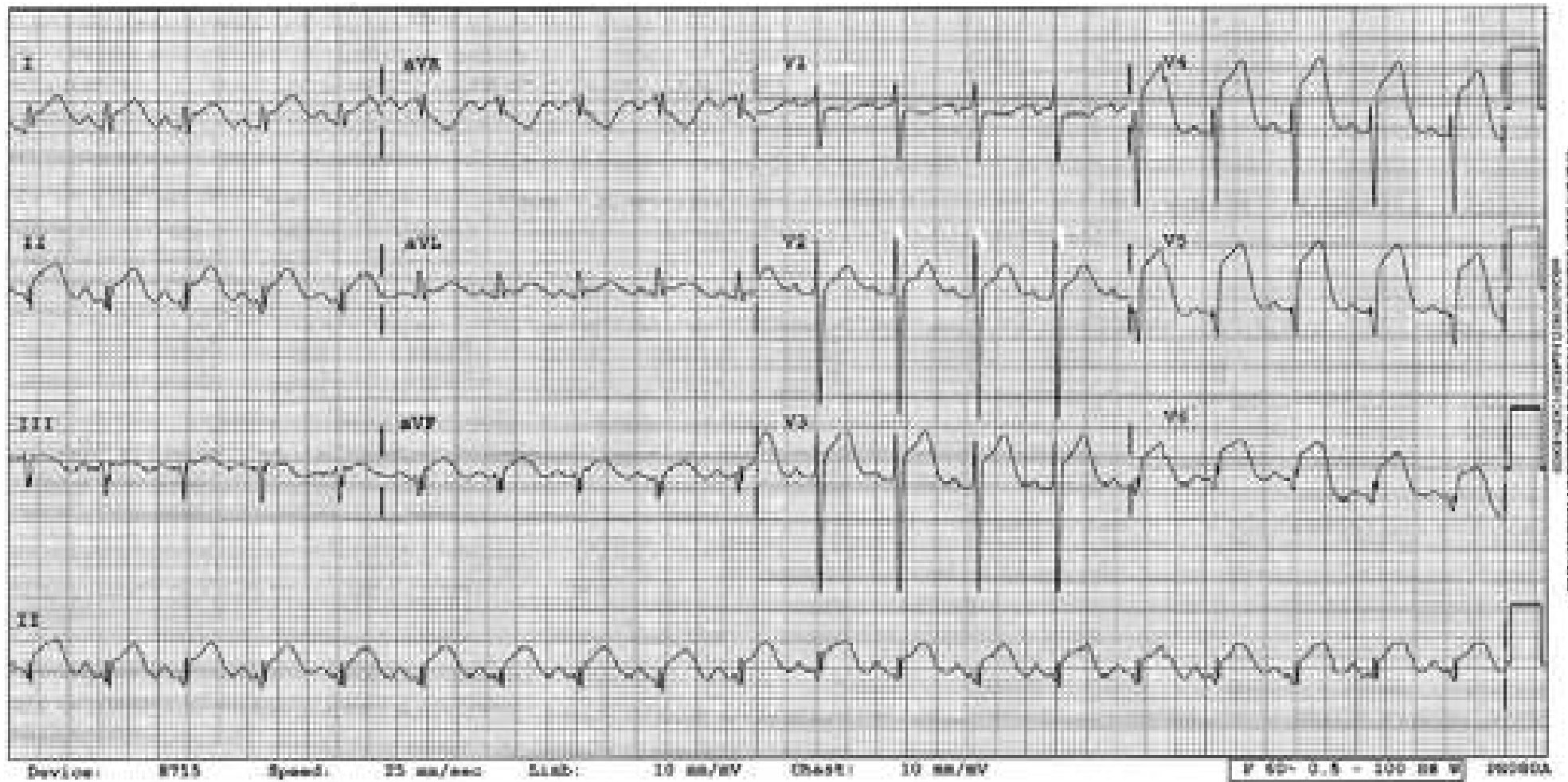
## Inferior Myocardial Infarction with “Unimpressive” Q Waves

This tracing is taken from a patient who has a proven inferior myocardial infarction. The Q wave in lead III is “unimpressive” at a glance. However, it is wide (more than 0.03s) and deep (more than one-quarter of the height of the R wave) and meets the criteria for abnormal Q wave, and reflects inferior myocardial infarction. Of these two criteria, the width has more weight than the depth. Even if it is deep, if it is narrow, it is not diagnostic of an infarction. However, even if it is shallow, if it is wide (more than 0.03s), an inferior infarction can be called. There is no Q wave in lead II and only a tiny Q wave in aVF. Even if there are no Q waves in other inferior leads, if it is present in lead III and is wide, an inferior infarction can be called.



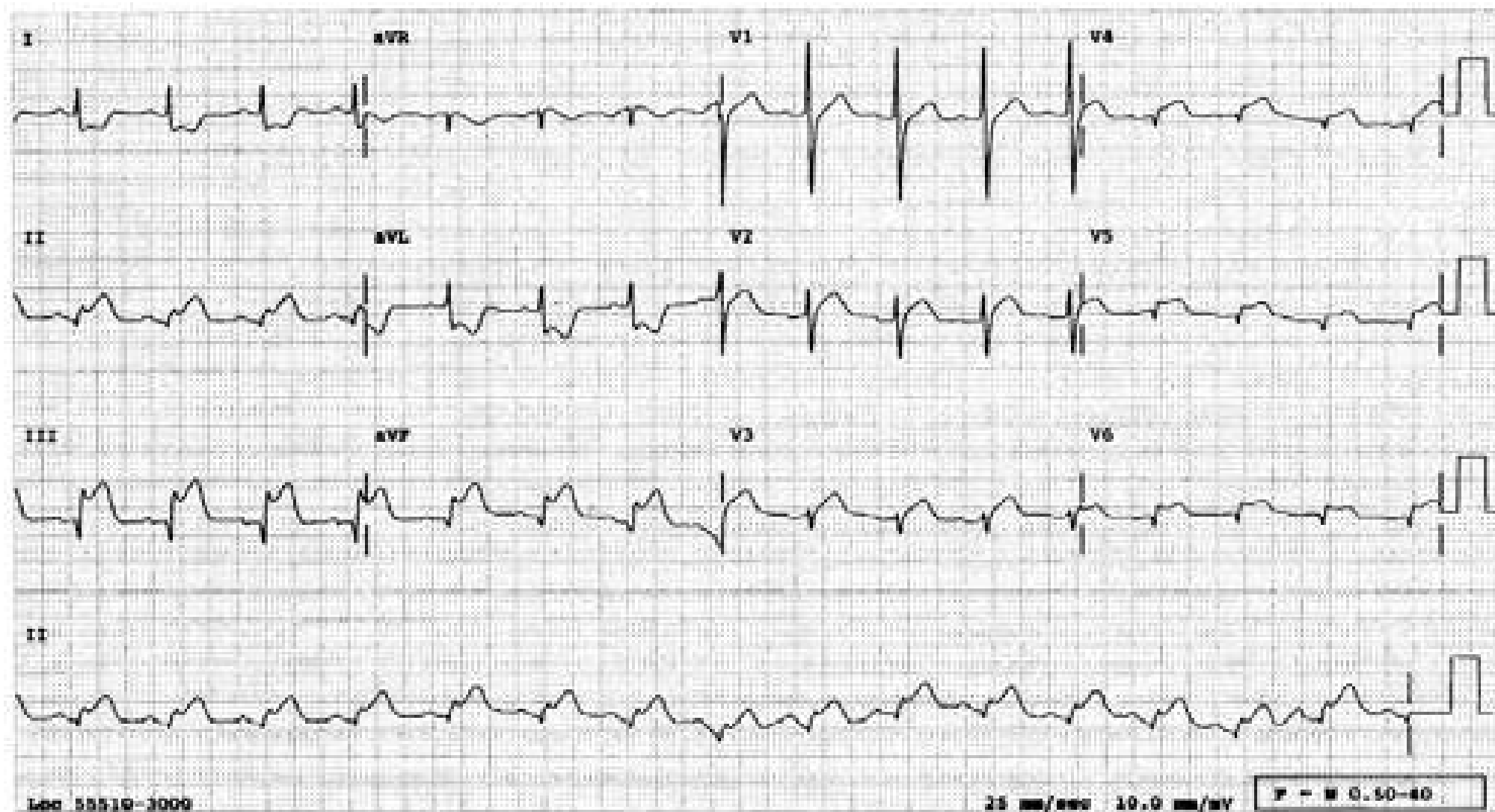
## Acute Apical Infarction

ST segments are elevated in leads V3-6. In the frontal plane, the ST segment axis is close to  $45^\circ$ . Therefore, the ST segment is most elevated in lead II, even though it is elevated in all limb leads except in aVR where it is reciprocally depressed. Note that the ST segments do not behave reciprocally between leads III and aVL as they do in inferior or lateral infarctions. They are elevated in both of these leads like in pericarditis. The infarction in this patient is due to an occlusion of mid-LAD, which raps around the cardiac apex resulting in an apical infarction.



## Inferior MI with RV Involvement

Acute inferior infarct is evident. The precordial leads are right-side. There are two clues for that (see the next page). These leads reveal RV involvement. It is not the QS or Qr pattern but the ST elevation in  $V_4R$ - $V_6R$  that indicate RV infarct (see the next page). The RV involvement is already predicted by the ST depression in lead I. In inferior MI without RV involvement, the ST vector is pointed more or less straight down, which is perpendicular to lead I axis, and the ST segment will not be deviated in lead I while it is depressed in aVL. ST depression in lead I as well as in aVL means the ST vector is pointed down and to the right. Why to the right? Because the RV is involved.





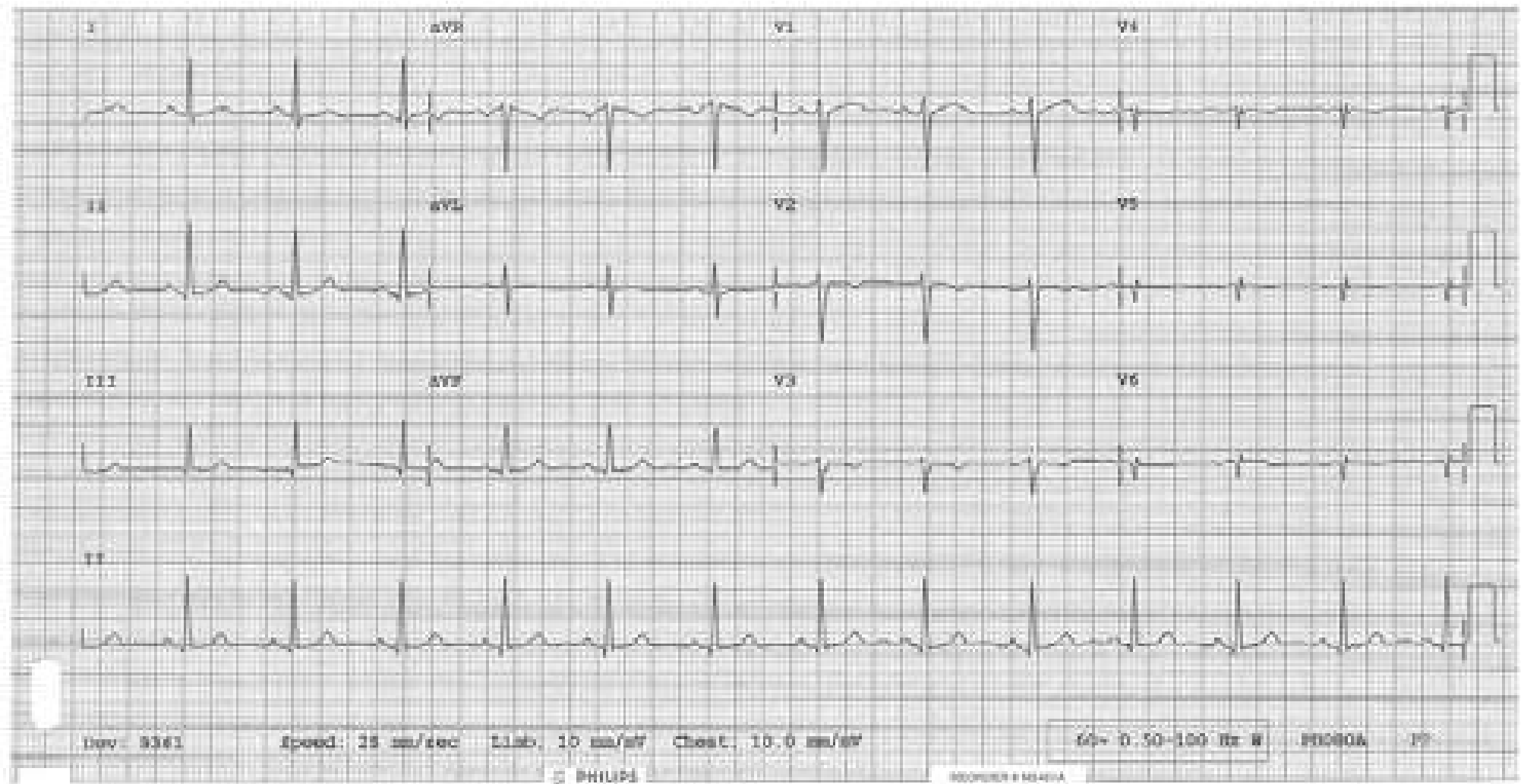
## Normal Right-Sided Precordial Leads

No currently available ECG machine can print out  $V_1R$ - $V_6R$ . Therefore, we have to figure out whether the given precordial leads are regular left-sided or right-sided. There are two clues for the right-sided leads; “QRS” clues and “P” clues.

- “QRS” clues:
1. The R waves regress instead of progressing
  2. The QRS in  $V_6$  is vectorially opposite to those of leads I and aVL. In regular left-sided V leads, the QRSs in I, aVL and  $V_6$  look similar because these leads face the heart from similar angles.

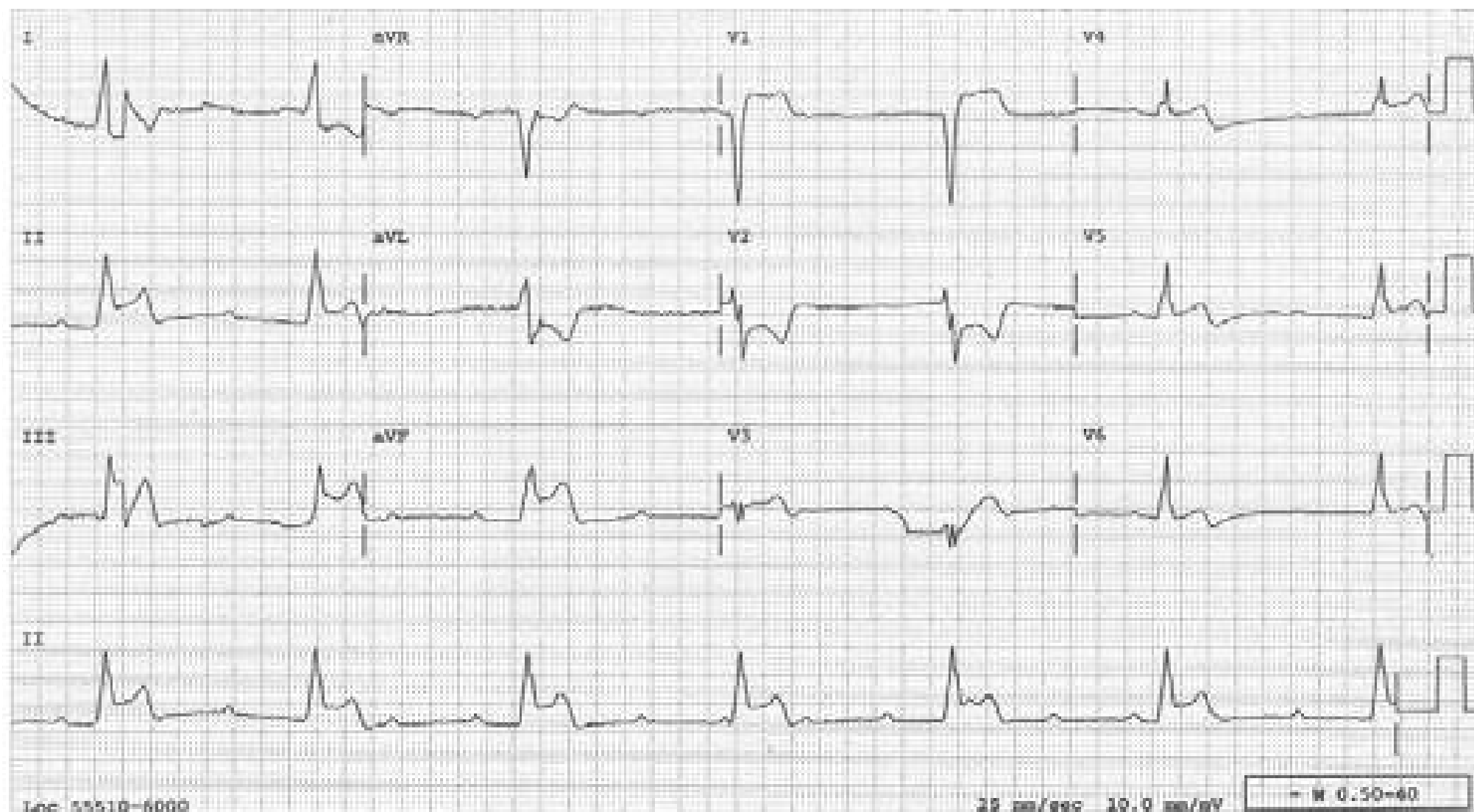
“P” clue: P waves are not upright in  $V_4R$ - $V_6R$  while they are upright in regular left-sided V leads

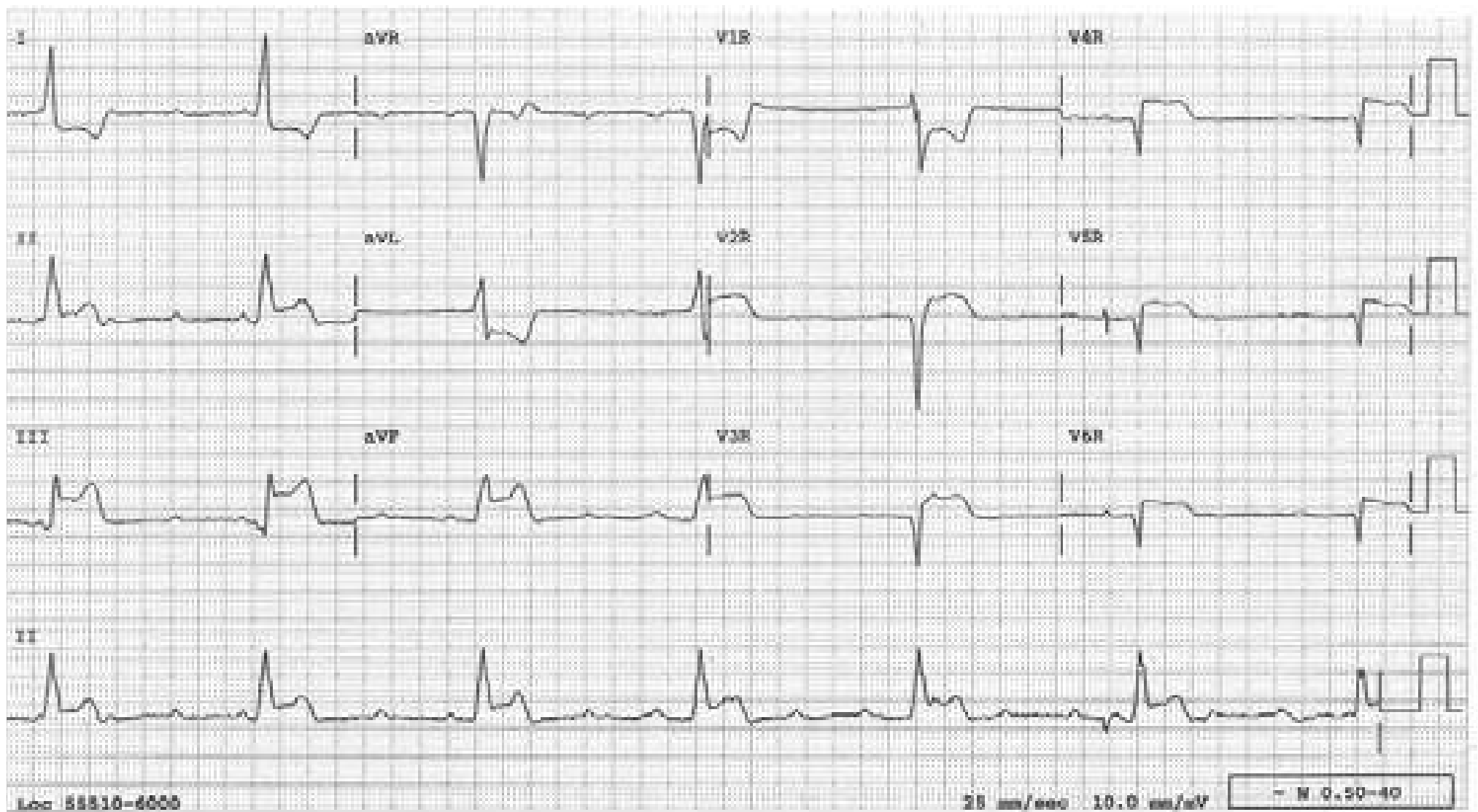
It is the ST elevation in  $V_3R$ - $V_6R$  which indicate RV infarction, not QS or QR pattern, which is normal in right-sided V leads.



## Acute Infero-Postero-Lateral MI and RV Infarct

This tracing reveals sinus mechanism with 3° AV block. ST elevation in the inferior leads indicates an acute inferior MI. ST depression in lead aVL is merely reciprocal to the ST elevation in lead III. However, the ST depression in  $V_2$  is due to the involvement of the posterior wall registered reciprocally. ST segment is elevated in  $V_1$  suggesting RV infarction. This is verified by the right-sided precordial leads which reveal ST elevation in  $V2R-V6R$  (see the next tracing). RV involvement can also be predicted by the ST depression in lead I.



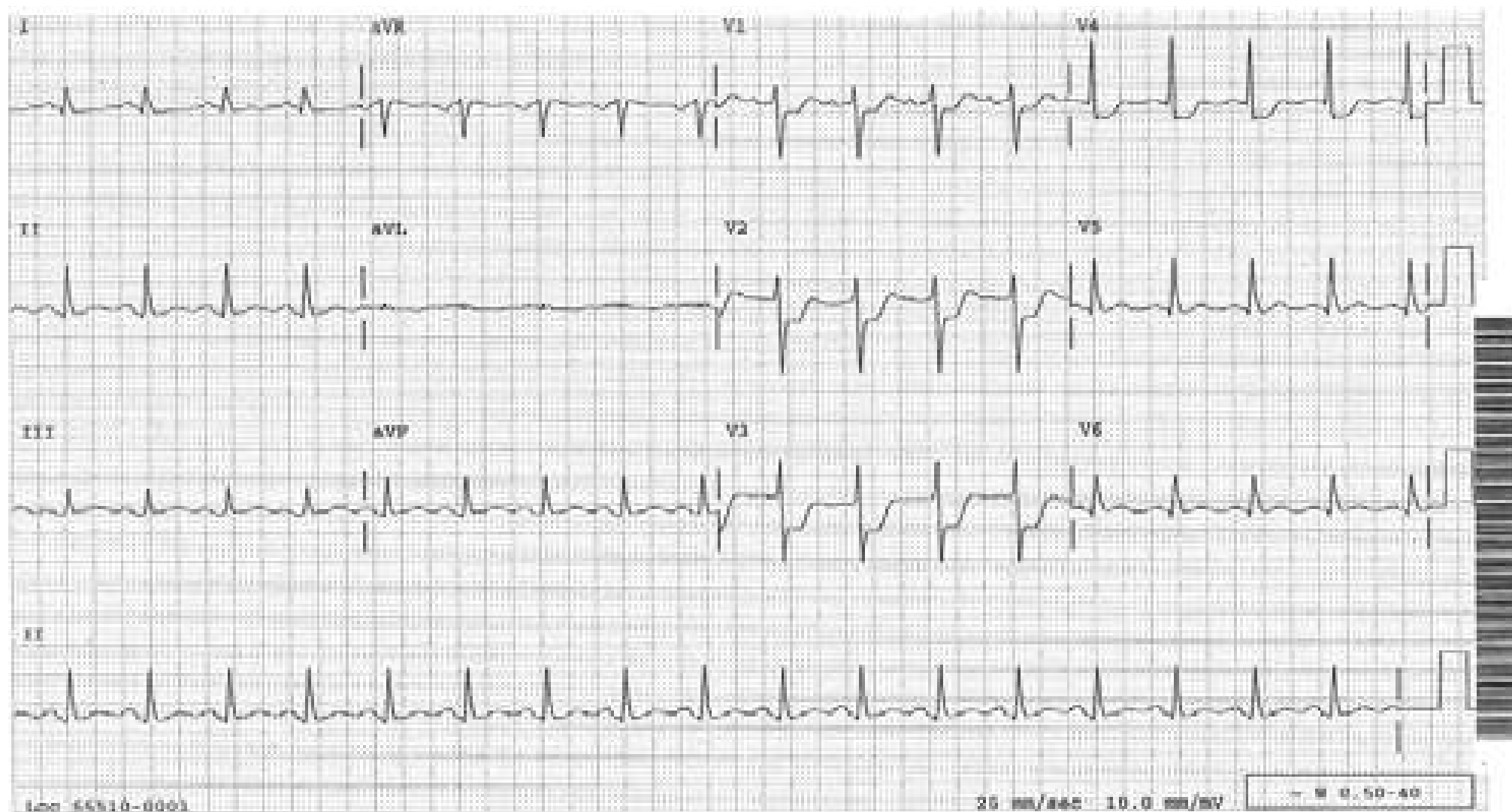


(See the discussion on the preceding tracing)



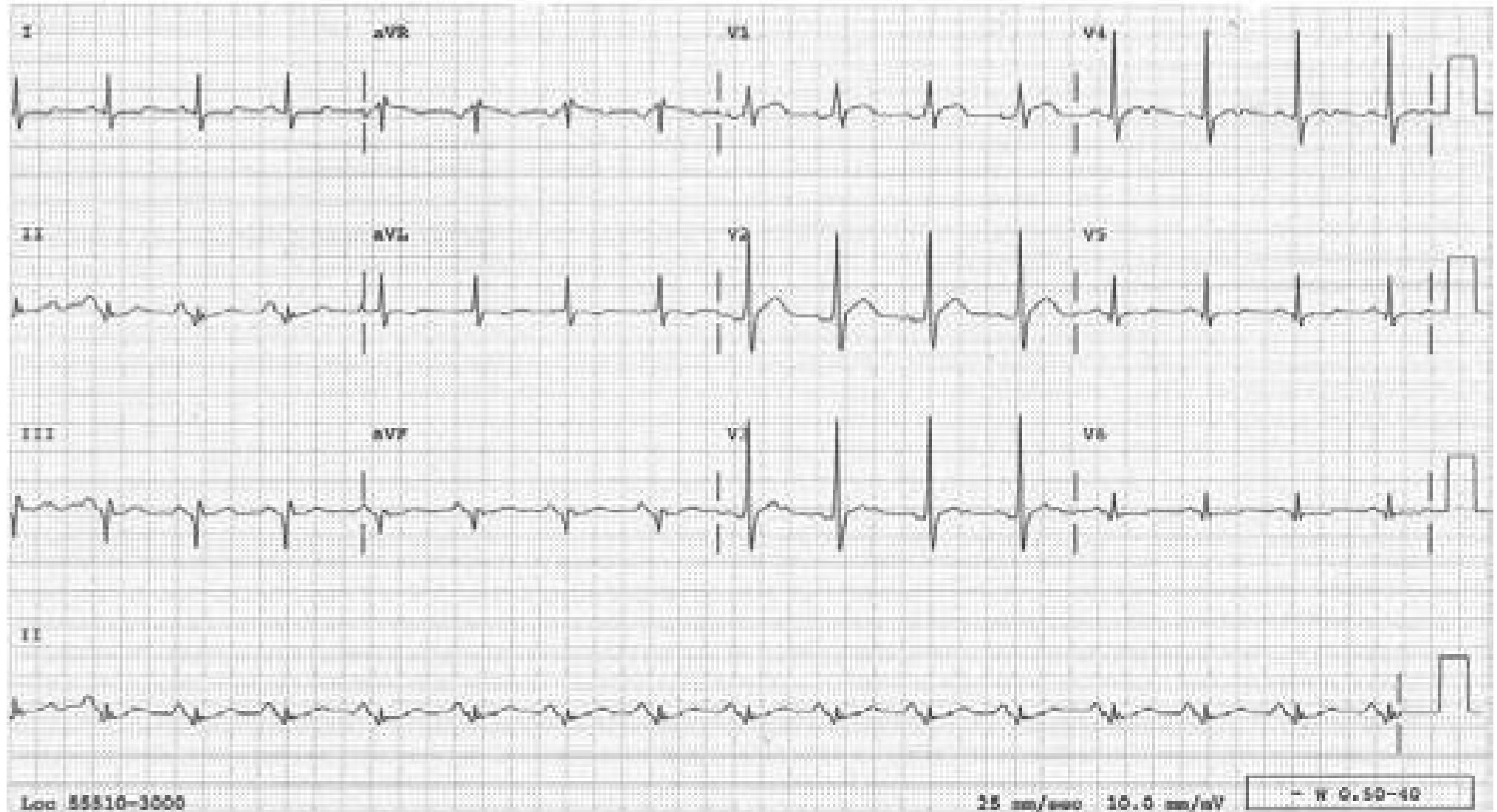
## Acute Posterior Infarction

The horizontal ST depression in V1-3 is actually the injury-pattern ST elevation of the posterior wall registered reciprocally, not anteroseptal subendocardial ischemia or infarction which more likely would have caused down-sloping ST depression and/or T wave inversion, not horizontal ST depression. Often, posterior infarction is part of infero-posterior or postero-lateral infarction and, in that case, the infarction pattern will also be present in these leads, supporting the diagnosis. This case is an example of isolated posterior MI and supporting evidences are not present in the inferior or lateral leads.



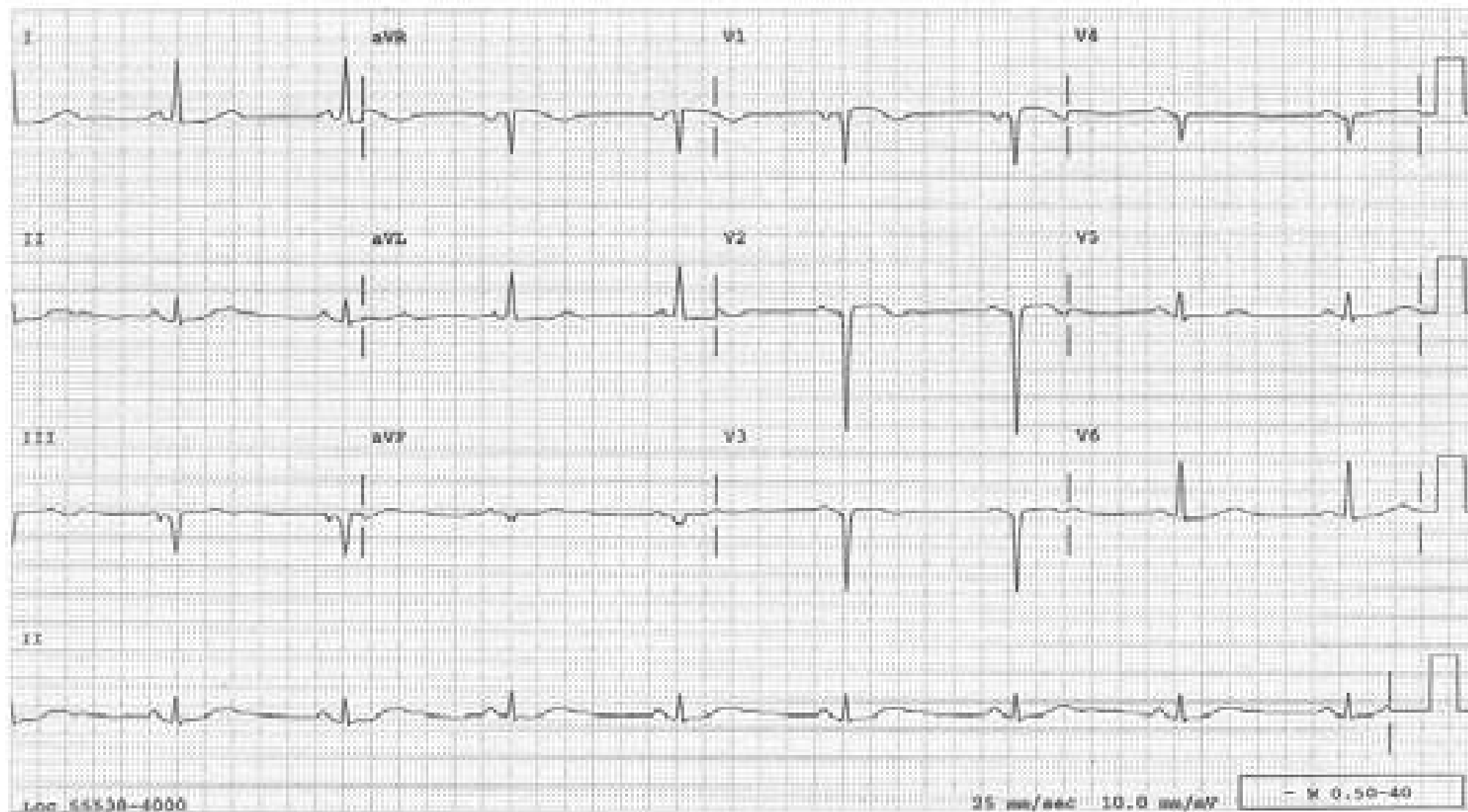
## Infero-posterior MI, Old

Pathologic Q waves in the inferior leads indicate an inferior MI; tall R waves in the right precordial leads indicate posterior wall involvement. Absence of ST elevation in the inferior leads and of ST depression in the right precordial leads indicate the infarct is old.



## Old Anterior and Inferior MIs

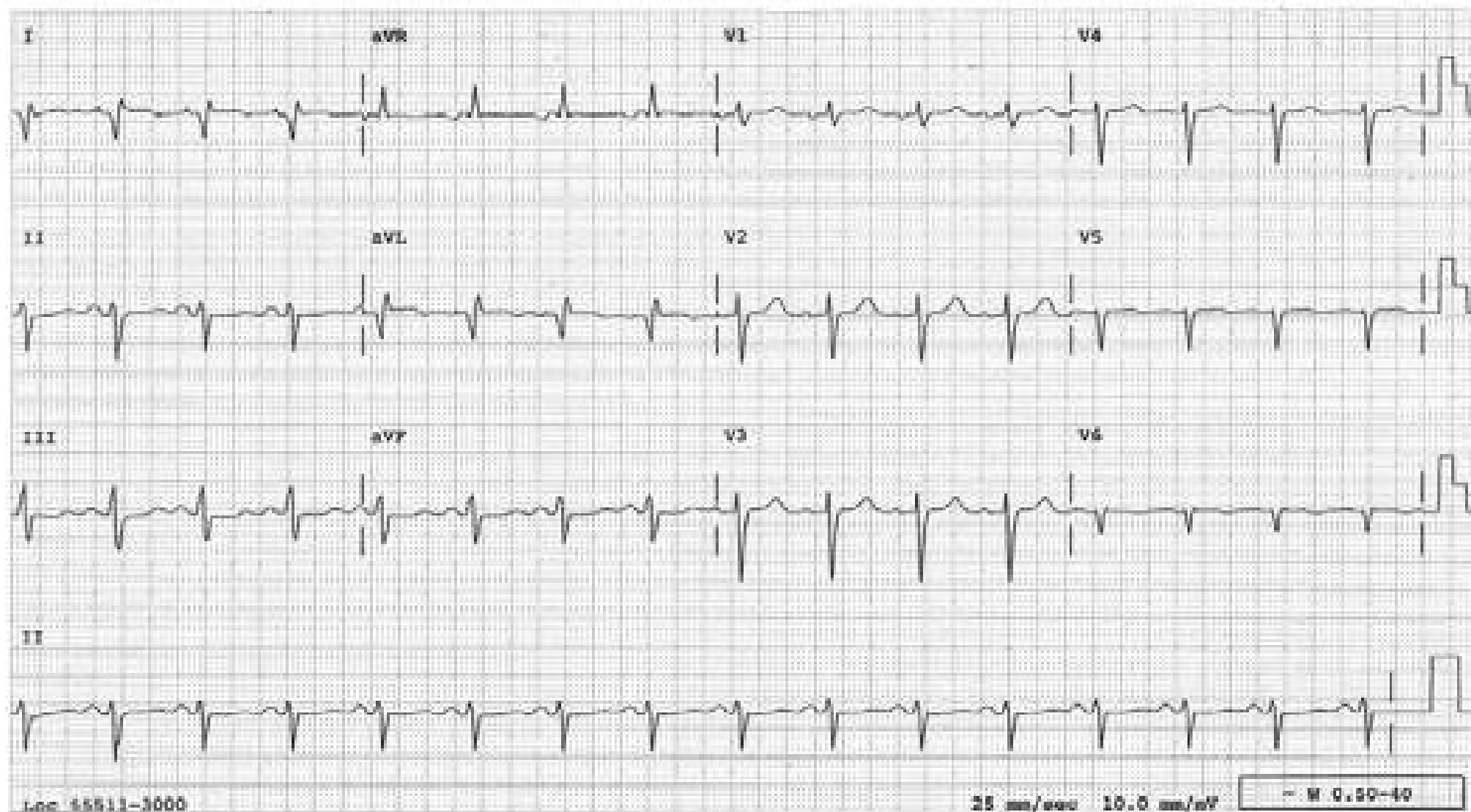
A QS pattern in  $V_{1-4}$  with no significant ST elevation indicate an old anterior MI. A QS pattern in III and aVF with a small Q wave in II without ST elevation or T wave inversion indicate an old inferior MI.





## High Lateral Myocardial Infarction

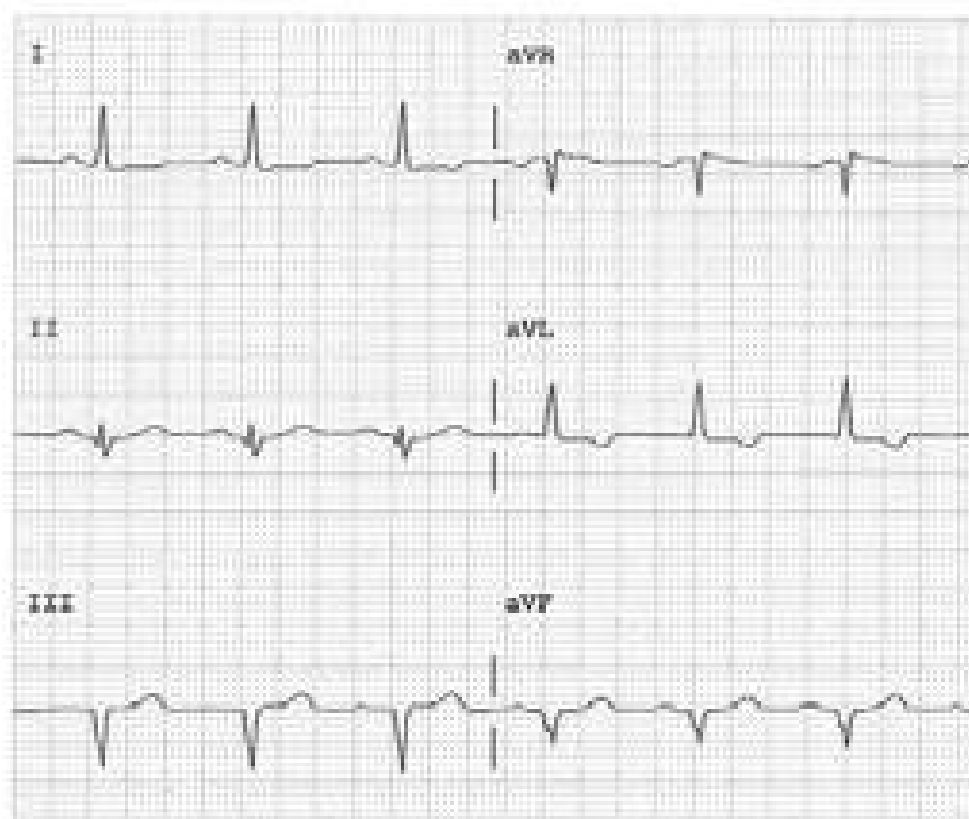
The changes are seen primarily in leads I and aVL. The loss of R waves in leads V<sub>5-6</sub> also supports the diagnosis.



## Left Axis Deviation (LAD) with or without Inferior MI

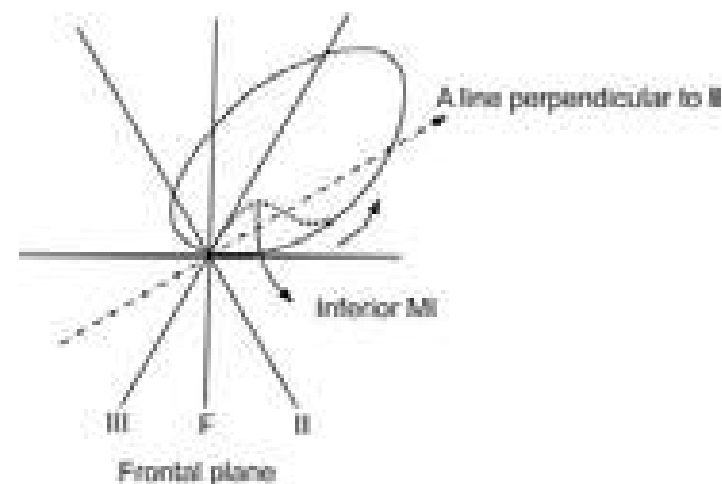
### ECG

When leads III and aVF reveal a QS pattern, the pattern in lead II becomes important. If the QRS in lead II starts with a Q wave (as in this tracing), it most likely reflects an inferior MI. If the QRS in lead II starts with an R wave, the tracing most likely reflects merely an axis deviation. However, on rare occasions, left anterior fascicular block can mask an inferior MI.

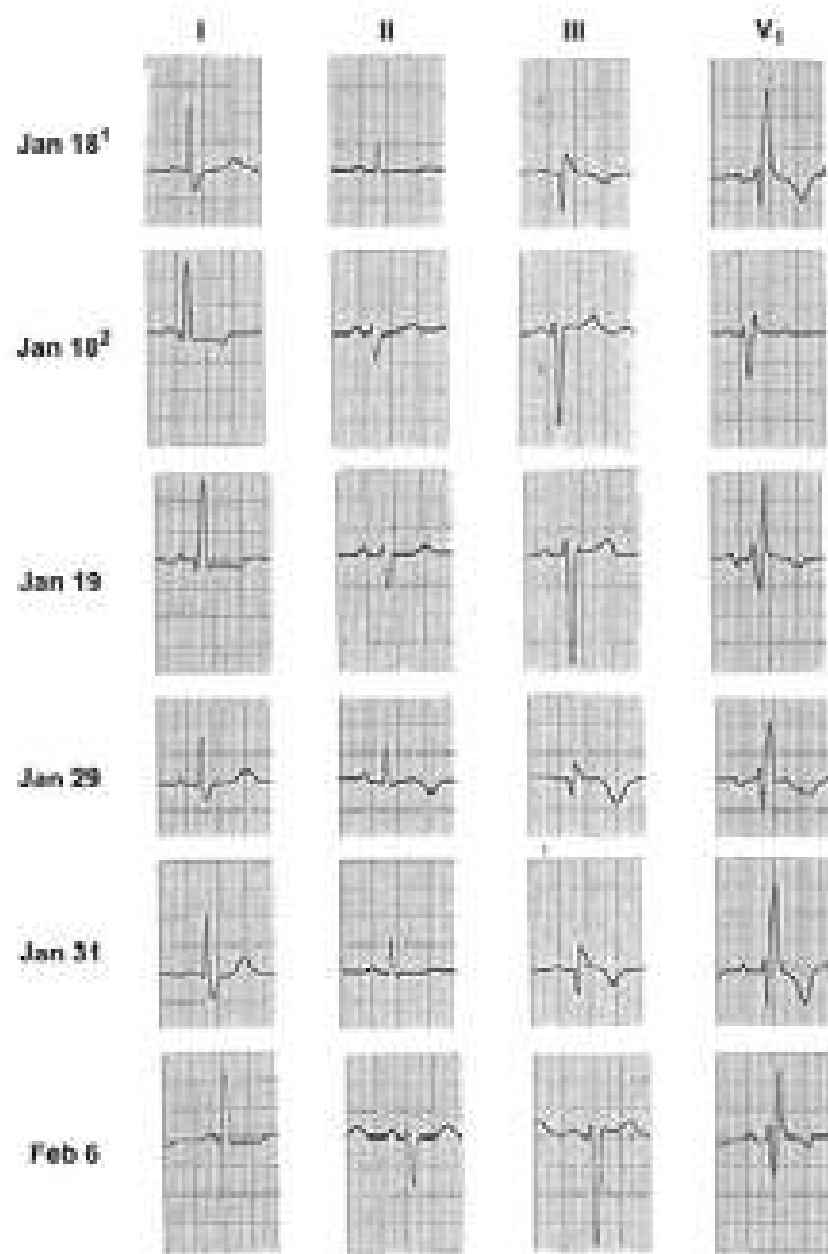


### VCG

In LAD, the QRS vector loop swings superiorly, but proceeds counter-clockwise. The Initial part of the loop is in the positive zone of lead II (area below the dashed line) and registers an R wave. If LAD is combined with an inferior MI, the initial vectors will be directed more sharply superiorly, and fall into the negative zone of lead II (area above the dashed line) to register a q wave. In either situation, the entire QRS loop is often in the negative zones of leads III and F. The result is a QS pattern in these two leads.



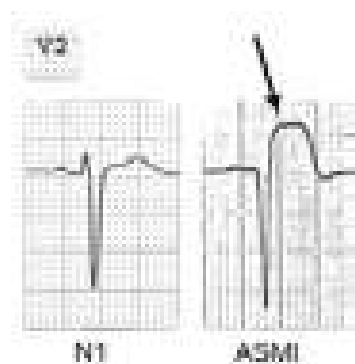
## Left Anterior Fascicular Block Masking Inferior MI



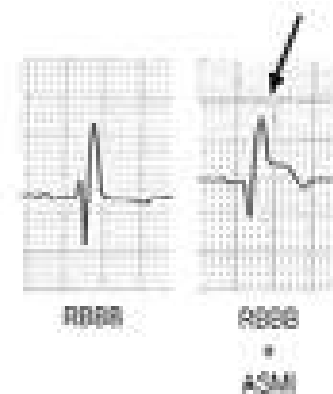This patient has a proven inferior MI which is revealed in Lead III on 1/18<sup>1</sup>, 1/29 and 1/31. Whenever she develops left anterior fascicular block (1/18<sup>2</sup>, 1/19 and 2/6), she loses the infarct pattern (RBBB is constantly present).



## Anteroseptal MI With and Without RBBB (Lead V<sub>2</sub>)



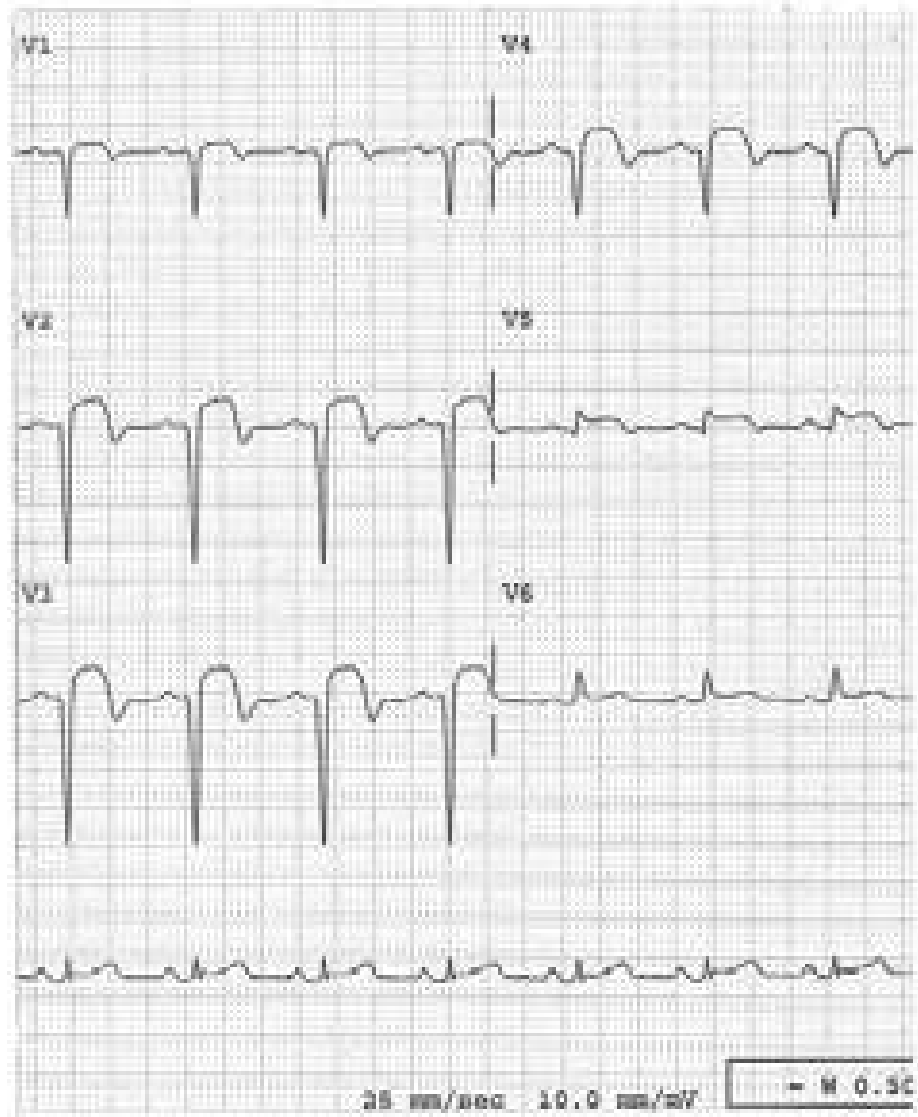
Note the smooth ST-segment elevation (↓)



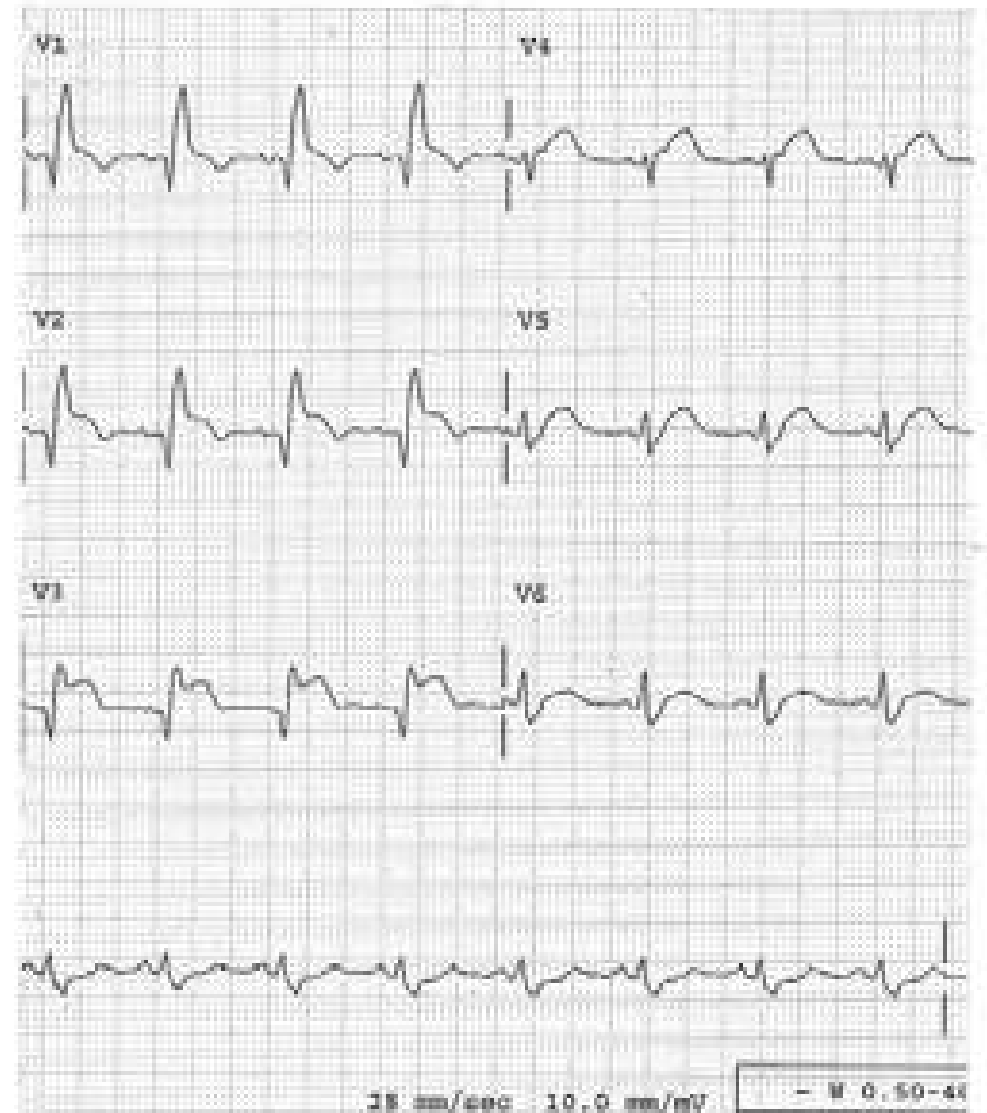
Note the 2<sup>nd</sup> peak (↓) persists while the 1<sup>st</sup> peak is replaced by a Q wave

Right bundle branch block affects only the terminal portion of the QRS; the initial portion is not affected. Therefore, it should not be difficult to recognize Q-wave infarction in the presence of RBBB.

**Anteroseptal MI  
without RBBB**

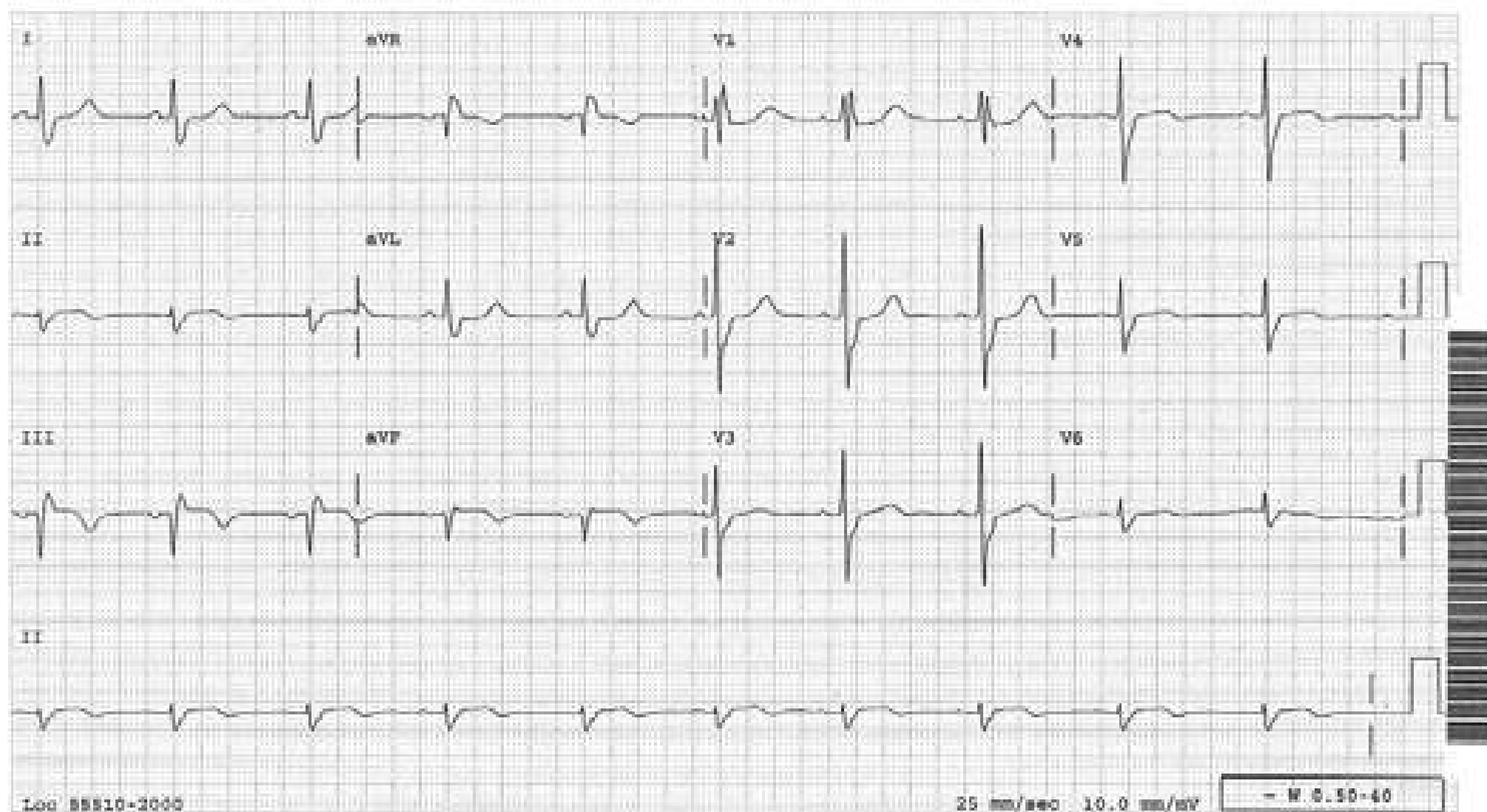


**Anteroseptal MI  
and RBBB**



## Acute Inferior MI and RBBB

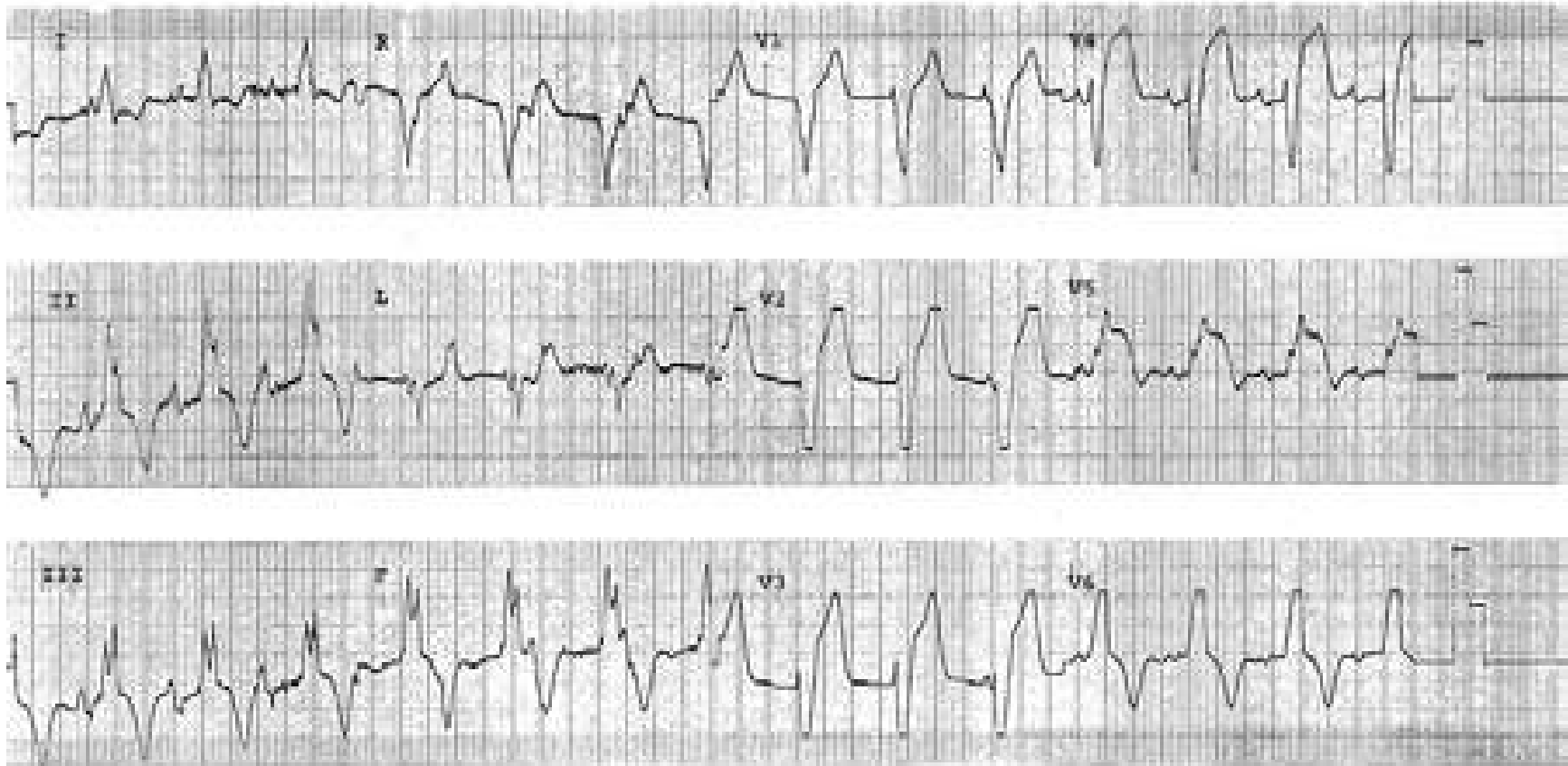
RBBB is evident (rSR' in VI, broad S waves in leads I, aVL, and V6). Q waves, ST-segment elevation and T wave inversion in leads III and aVF are diagnostic of acute inferior infarct. RBBB does not interfere with ECG manifestations of infarction as exemplified by this case.



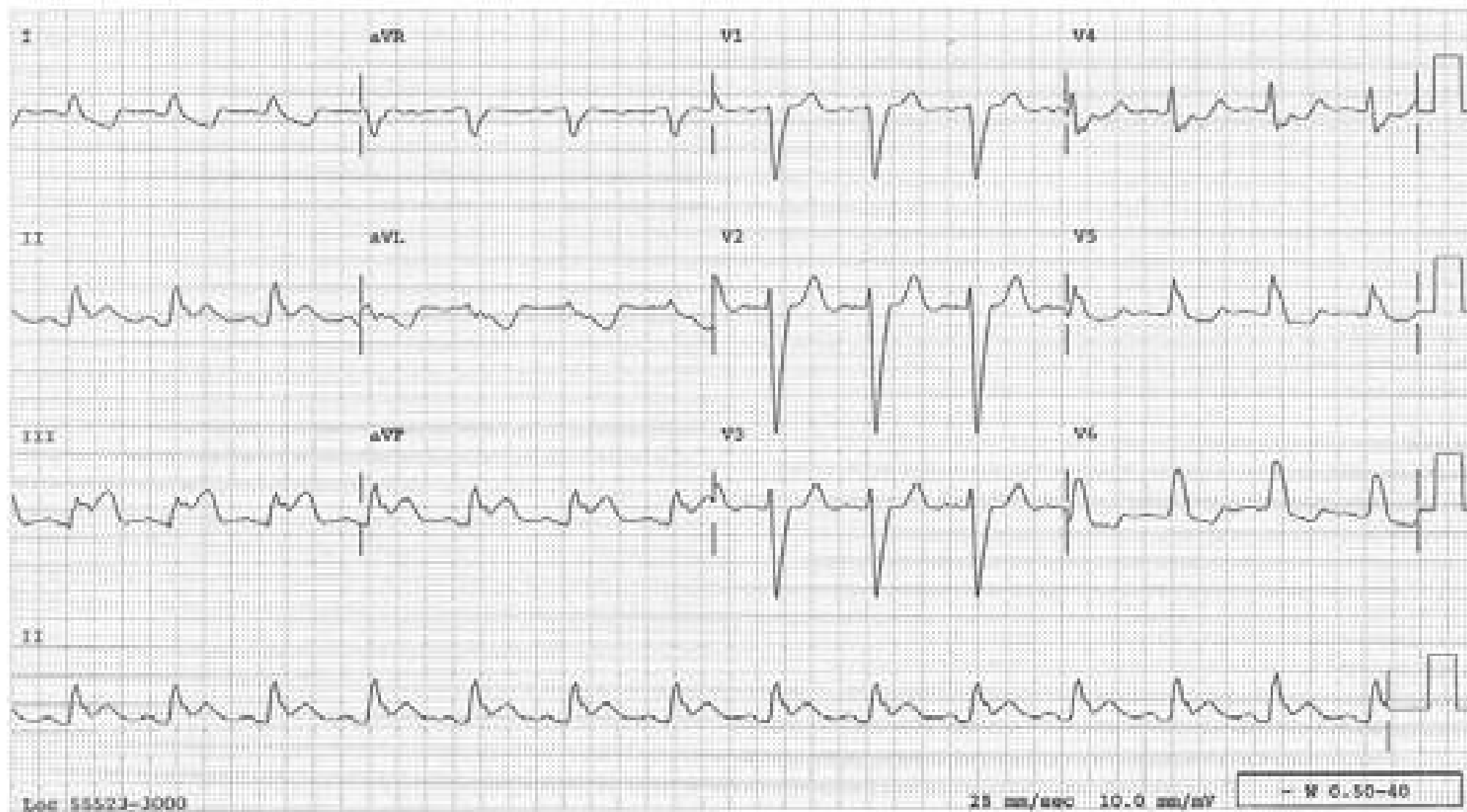


## Recognition of Myocardial Infarction in the Presence of LBBB

In LBBB, the ventricular depolarization is altered from the beginning to the end. The repolarization is also affected resulting in secondary ST-T changes. Therefore, the Q waves and ST-T changes of myocardial infarction can be simulated or masked. The direction of the ST-T changes secondary to LBBB is in the direction opposite (discordant) to the main QRS component. When the direction of ST-segment deviation is in the same direction as the main QRS component (concordant), the ST change is no longer secondary to LBBB; rather it is considered primary and indicates myocardial injury. A prominent Q wave in lead I or aVL, unusual for LBBB, is also highly suggestive of Q wave infarction. This tracing is taken from a patient with a proven acute anterior MI. The ST segment in  $V_5$  is markedly elevated which is concordant with the QRS (i.e., primary ST change).

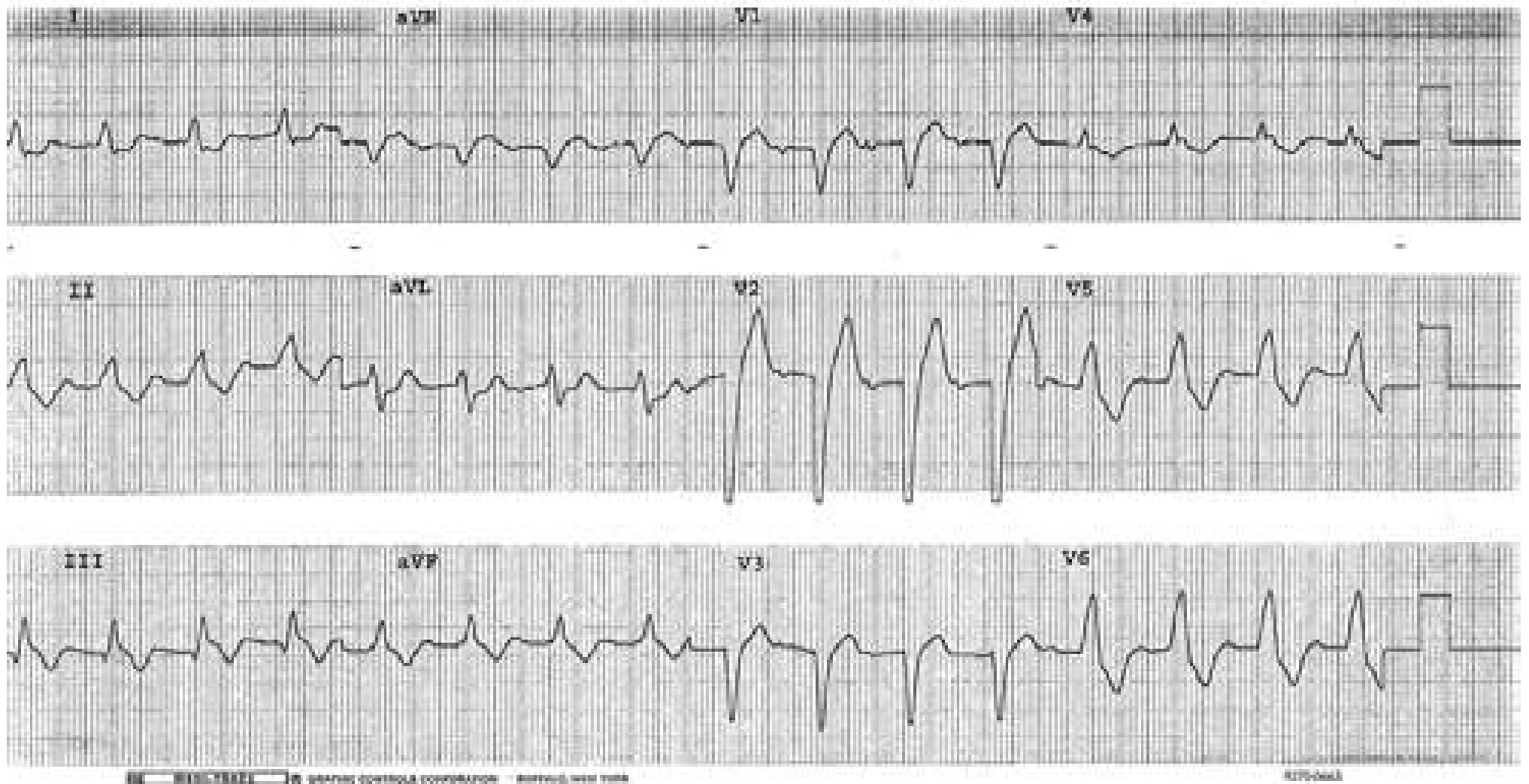


LBBB is evident (see lead V<sub>6</sub> especially). In the inferior leads, there are concordant ST-T changes and are diagnostic of inferior STEMI.



## Acute Inferior MI and LBBB

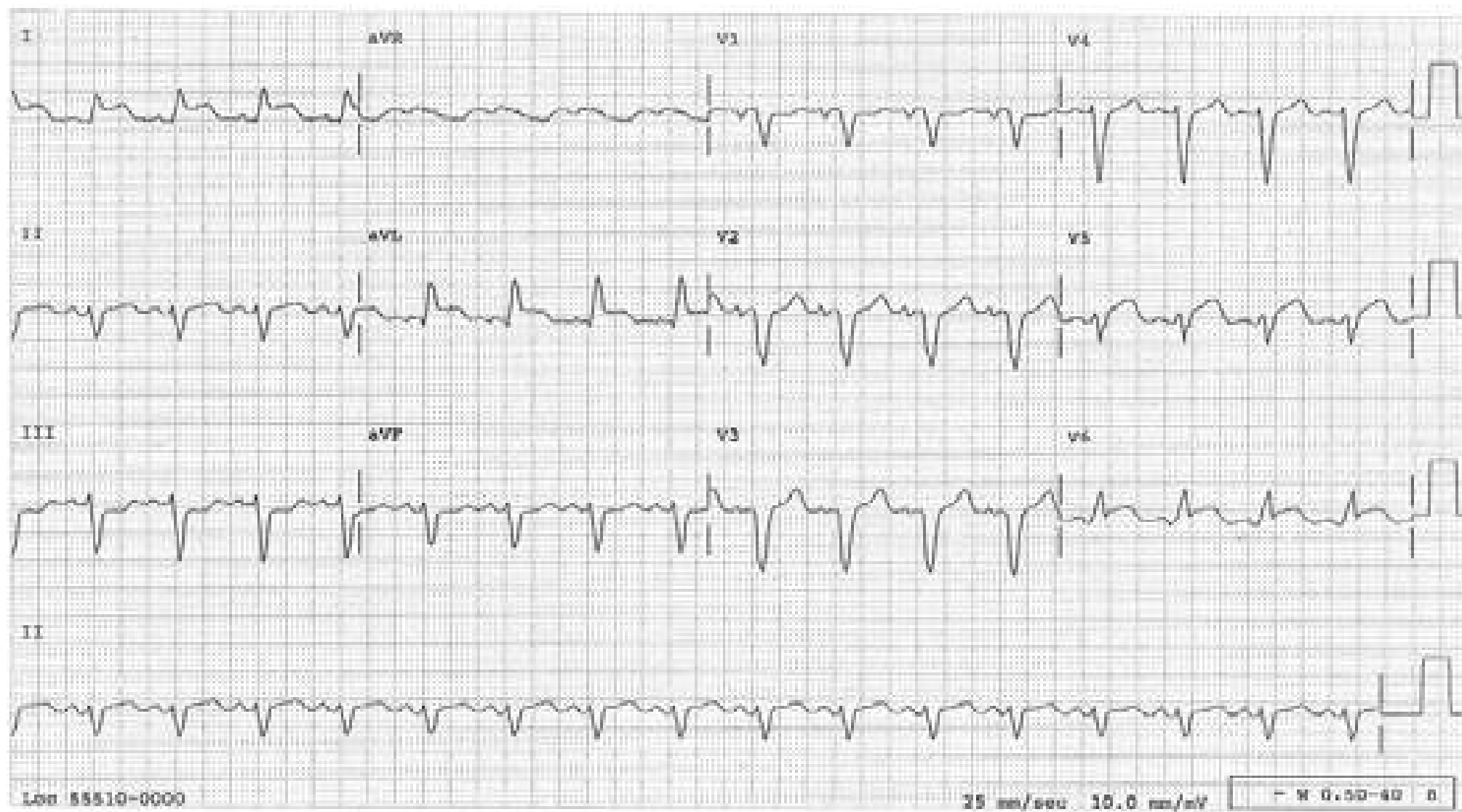
Note the Q wave and concordant ST change in lead III, diagnostic of inferior STEMI.





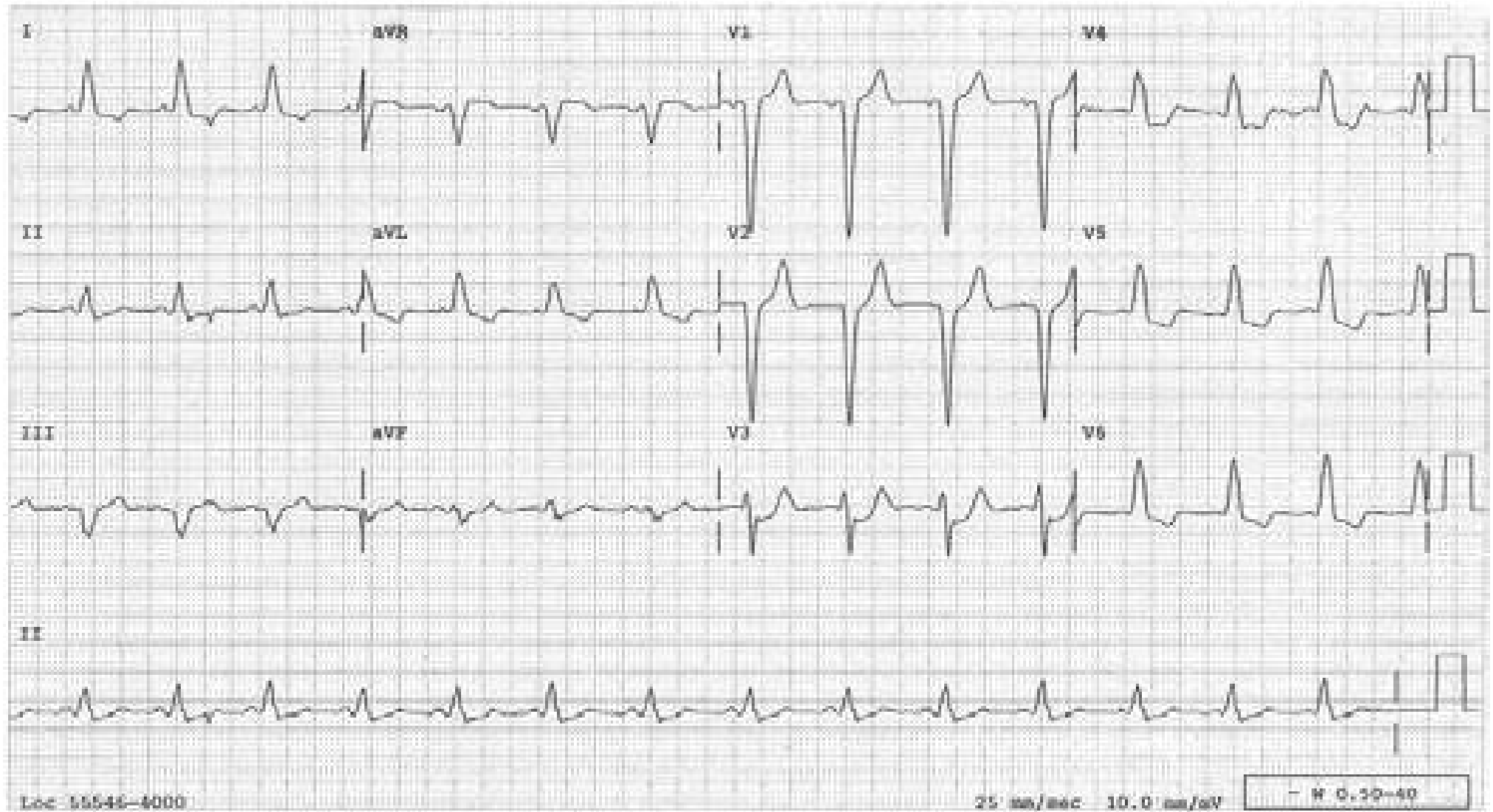
### LBBB and Acute Anterolateral MI

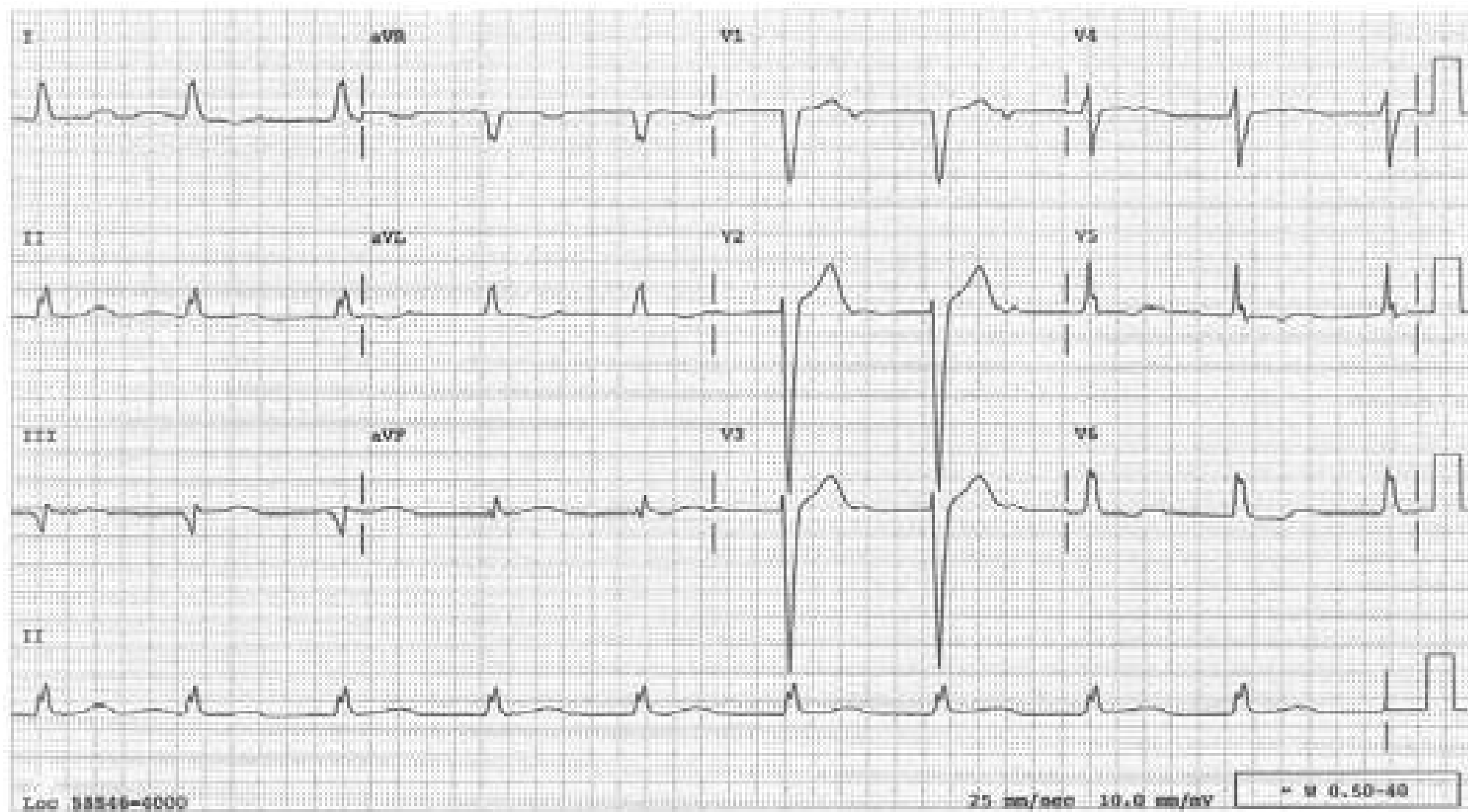
LBBB is evident (see leads  $V_{1-3}$  especially). In leads I, aVL and  $V_6$ , there are concordant ST changes indicating acute infarction, which is what this patient proved to have.



## Acute Posterior MI and LBBB

In  $V_3$ , there is concordant ST change. This horizontal ST depression is the ST elevation of the posterior LV wall registered reciprocally.



**LBBB and Inferior MI****Note Qr Pattern in Lead III**

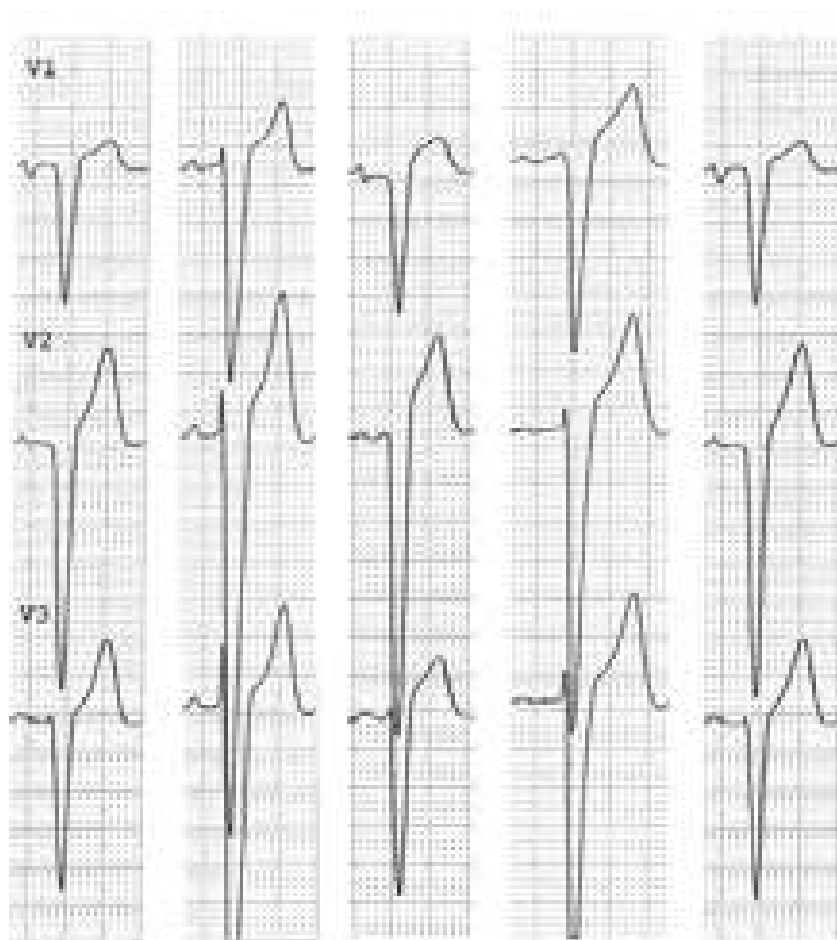


## LBBB with and without Acute Anteroseptal MI

In LBBB, ST-segment deviation concordant with the major component of the QRS complex indicates acute infarction. However, this can never happen in anteroseptal infarction (ASMI) since, in LBBB, the QRS complexes in V1-3 are always negative, i.e. discordant from the elevated ST segment from ASMI. Other clues are available such as convex ST segment, T wave inversion or ST-segment elevation >25% of the S wave amplitude.

### LBBB without acute ASMI in these 5 different patients


Note the elevated ST segment is concave. T Waves are not inverted.



Patient 1 2 3 4 5

### LBBB with Acute ASMI in these 5 different patients

Note the elevated ST segment is convex. If the T wave is terminally inverted, it is also a good sign of acute MI.



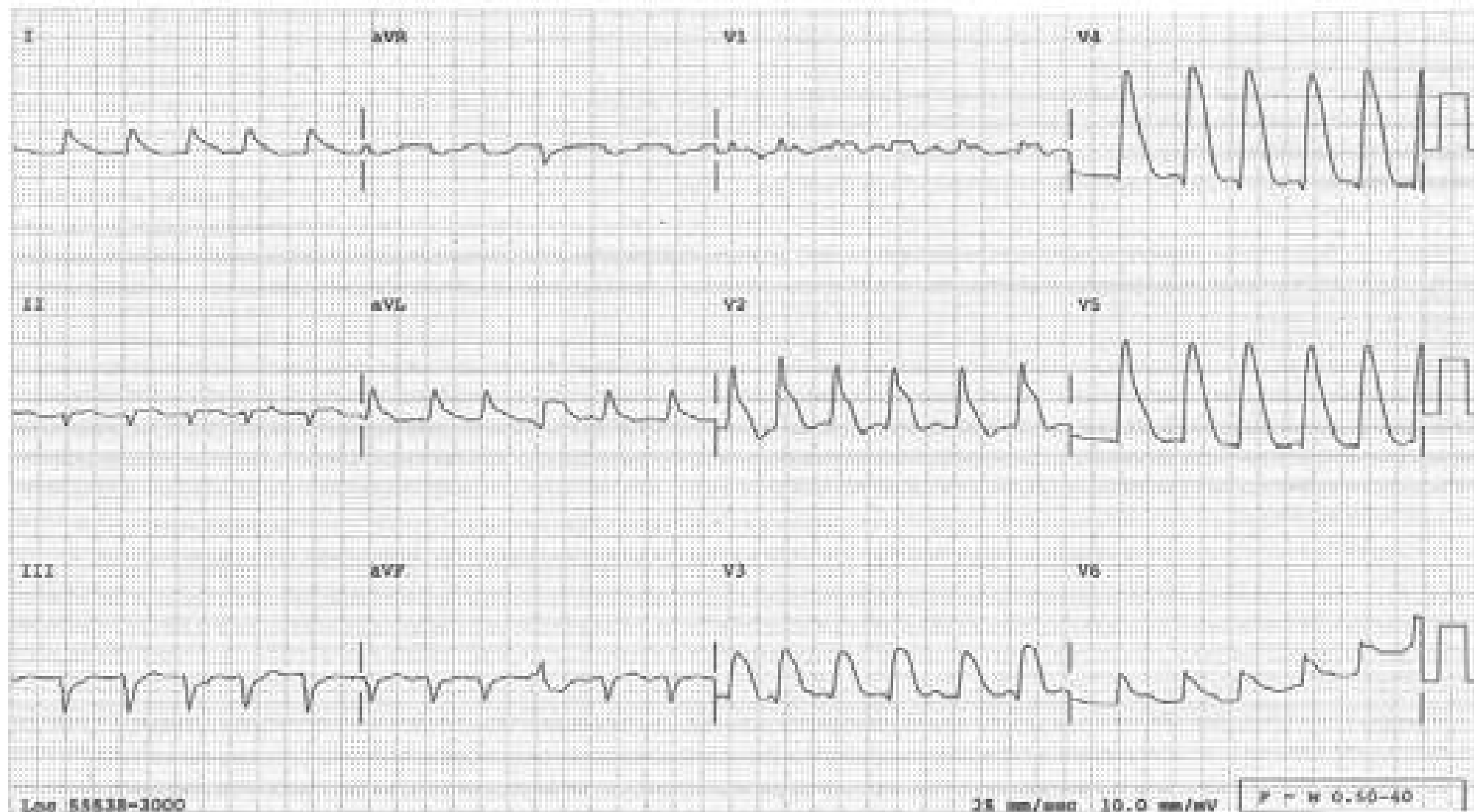
Patient 1 2 3 4 5

### ST Elevation from Acute Anterior MI, Mimicking Widened QRS

Severe ST elevation (best appreciated in  $V_2$ ) in many leads (especially  $V_4$ ) suggest widened QRS.

This tracing could be mistaken for ventricular tachycardia.

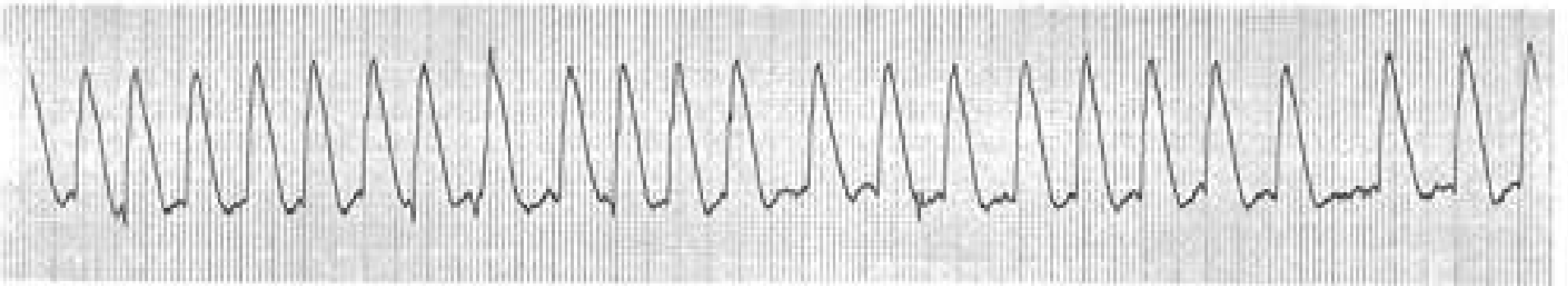
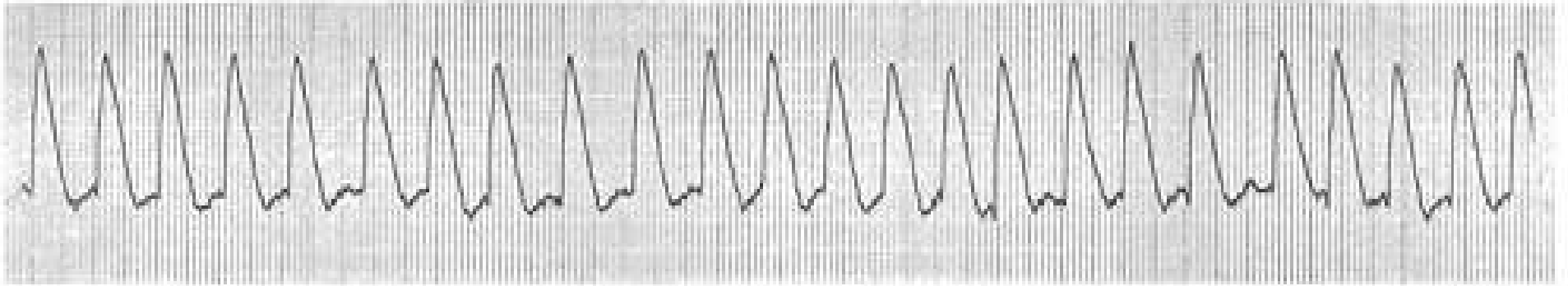
(See next page)



## ST Elevation Simulating Ventricular Tachycardia

This is a rhythm strip of lead V4 from the patient in the preceding page.

V4

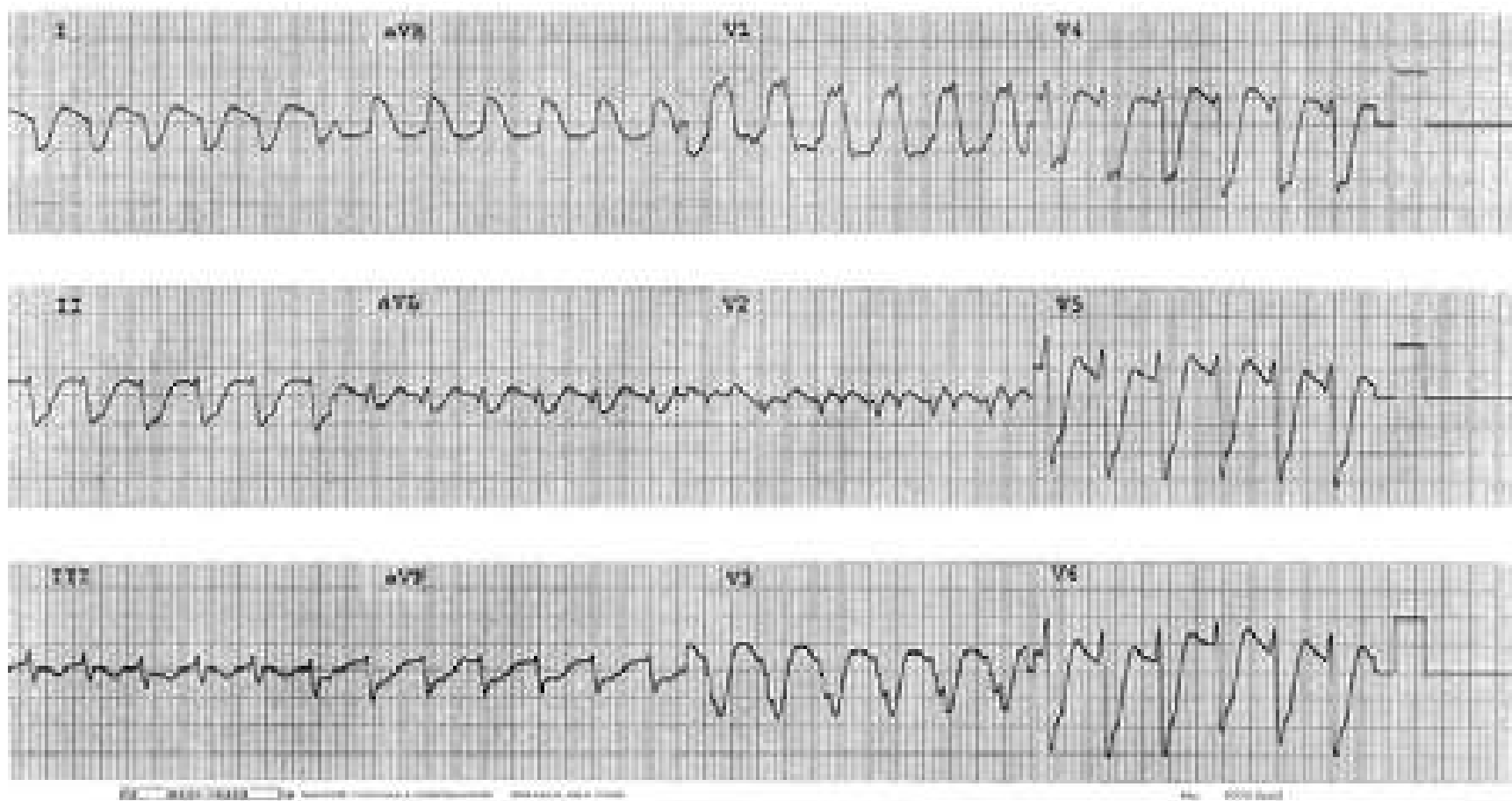




## ST Elevation or Depression Mimicking Widened QRS

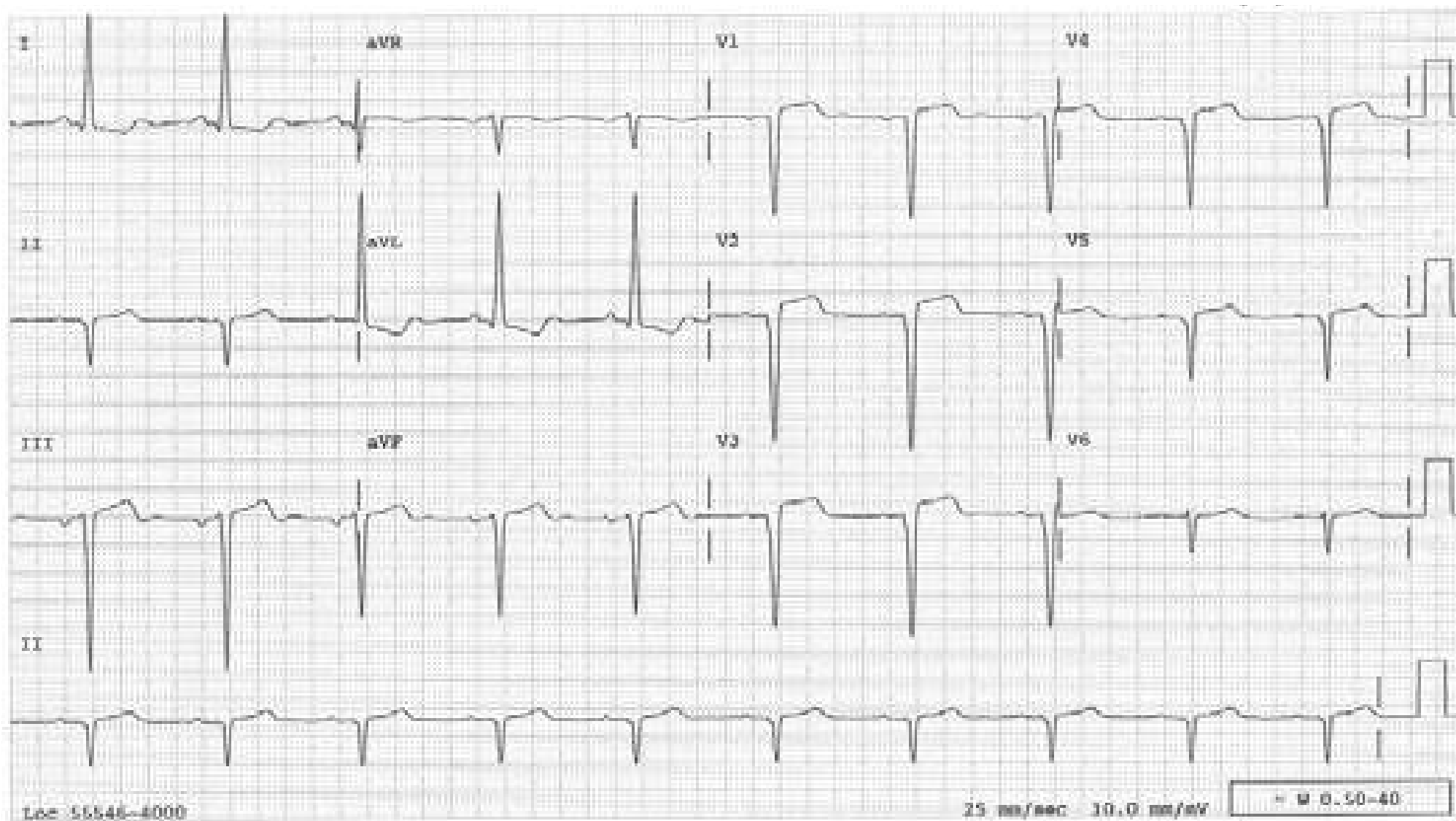
Severe ST depression (best appreciated in  $V_5$ ) and ST elevation in  $V_1$  and aVR suggest widened QRS.

This tracing could also be mistaken for ventricular tachycardia.



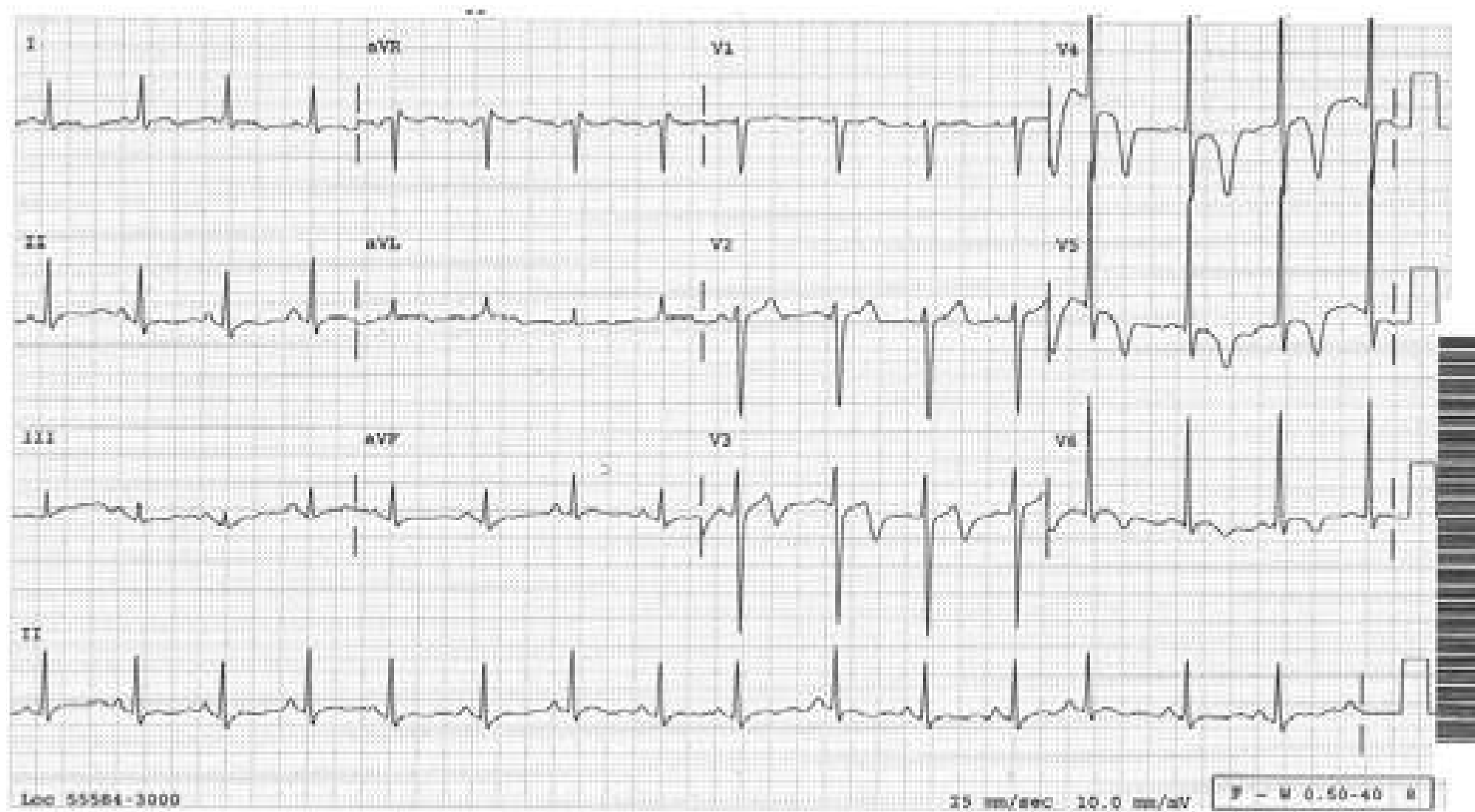
## Ventricular Aneurysm

QS pattern in V1-4 with persistent ST elevation, reflecting an old anterior MI and ventricular aneurysm.



## Non-ST-elevation Infarct

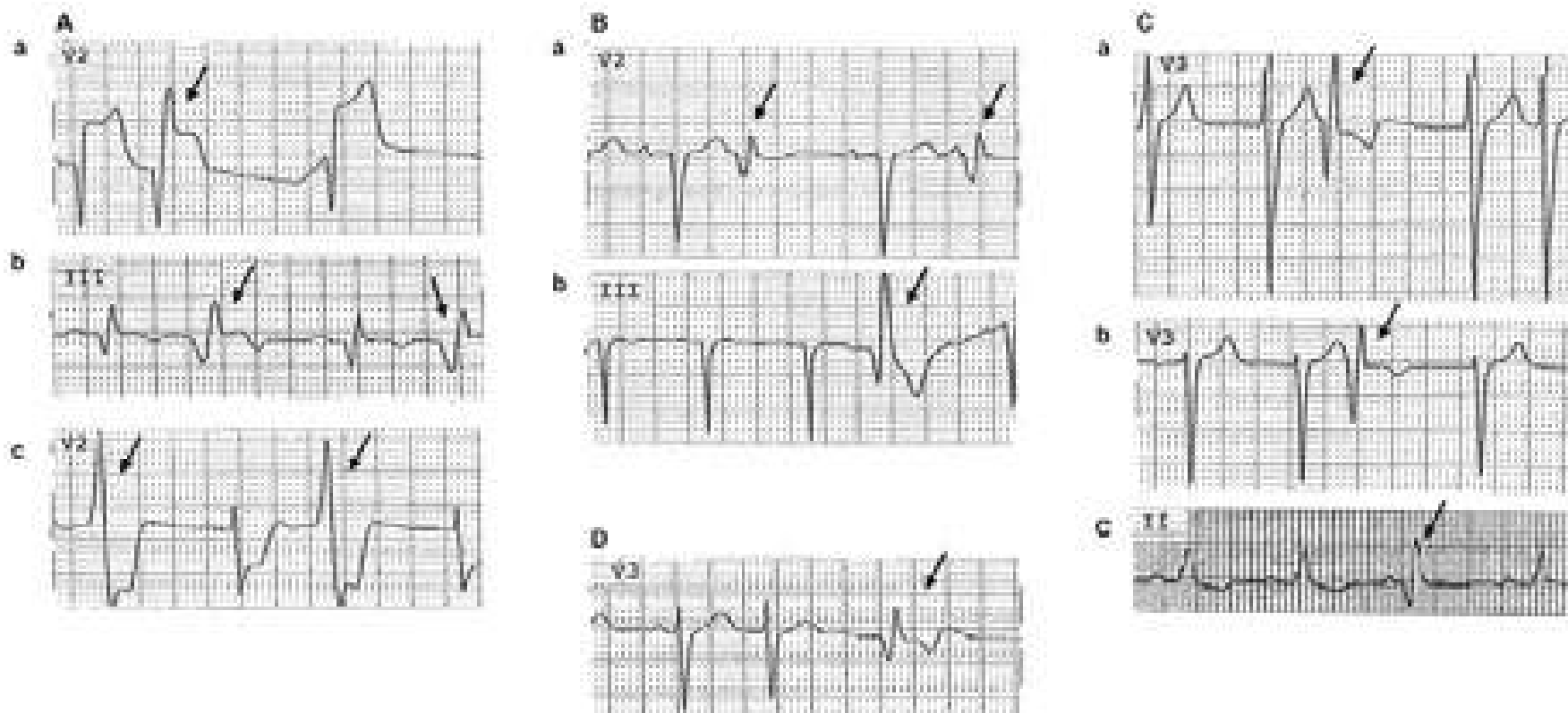
Inverted T waves in V3-6 in this tracing turned out to be due to non-ST-elevation infarct.





## VPBs Revealing Infarction Pattern

(It has to be a QR or qR pattern, not QS)



A: Examples in which both the sinus beats and the VPBs reveal infarction pattern.

a: Anteroseptal infarction; b: Inferior infarction; c: Posterior infarction registered reciprocally in V2

B: Examples of VPBs revealing the infarction pattern while the sinus beats are only suggestive of the diagnosis.

a: Anteroseptal infarction; b: Inferior infarction

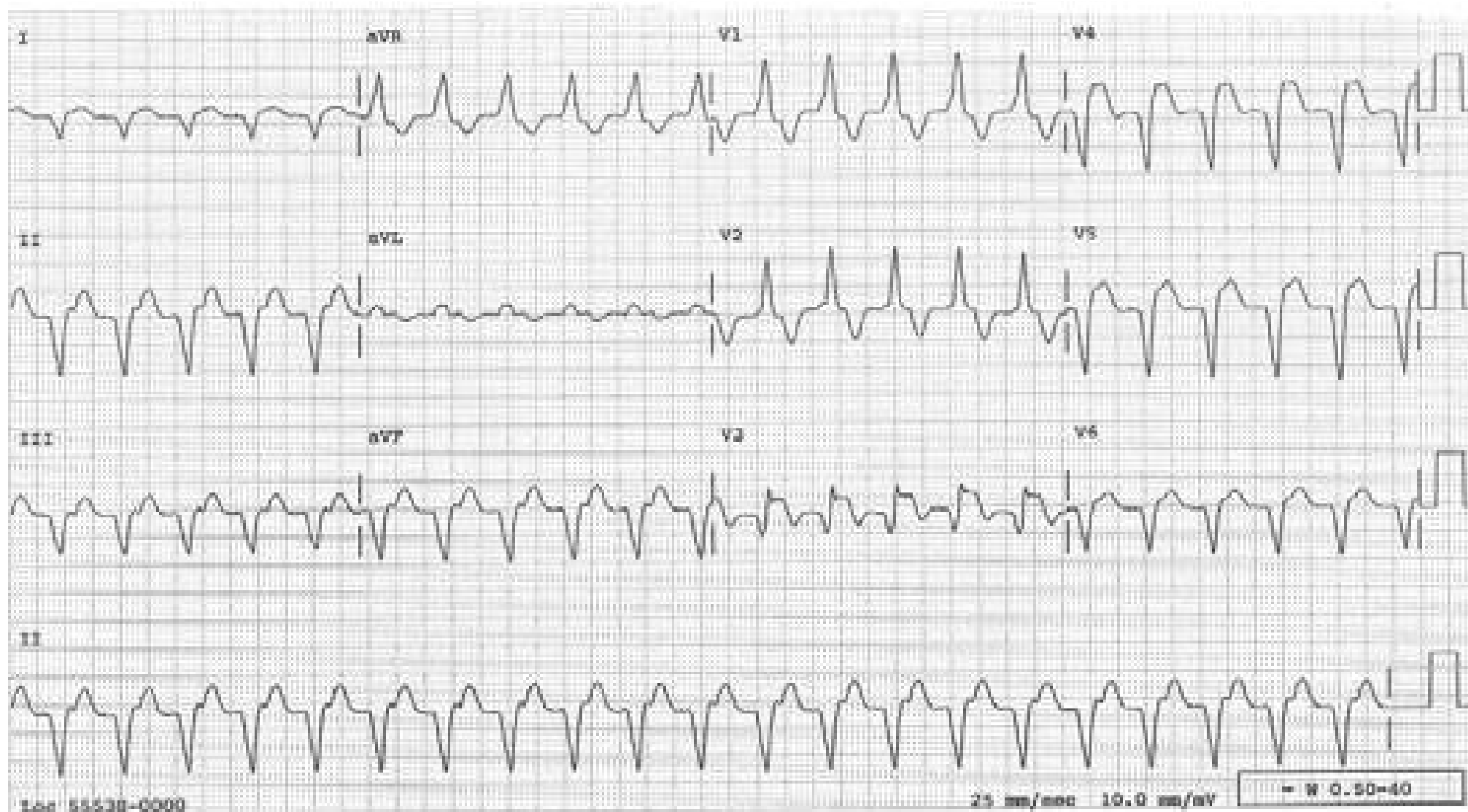
C: Examples of only the VPBs revealing the infarction pattern while the sinus beats do not.

a: Anteroseptal infarction; b: Anteroseptal infarction; c: Inferior infarction

D: An example of a false positive case where the VPB revealed the infarction pattern but the rest and stress echocardiograms were normal. (false positive)

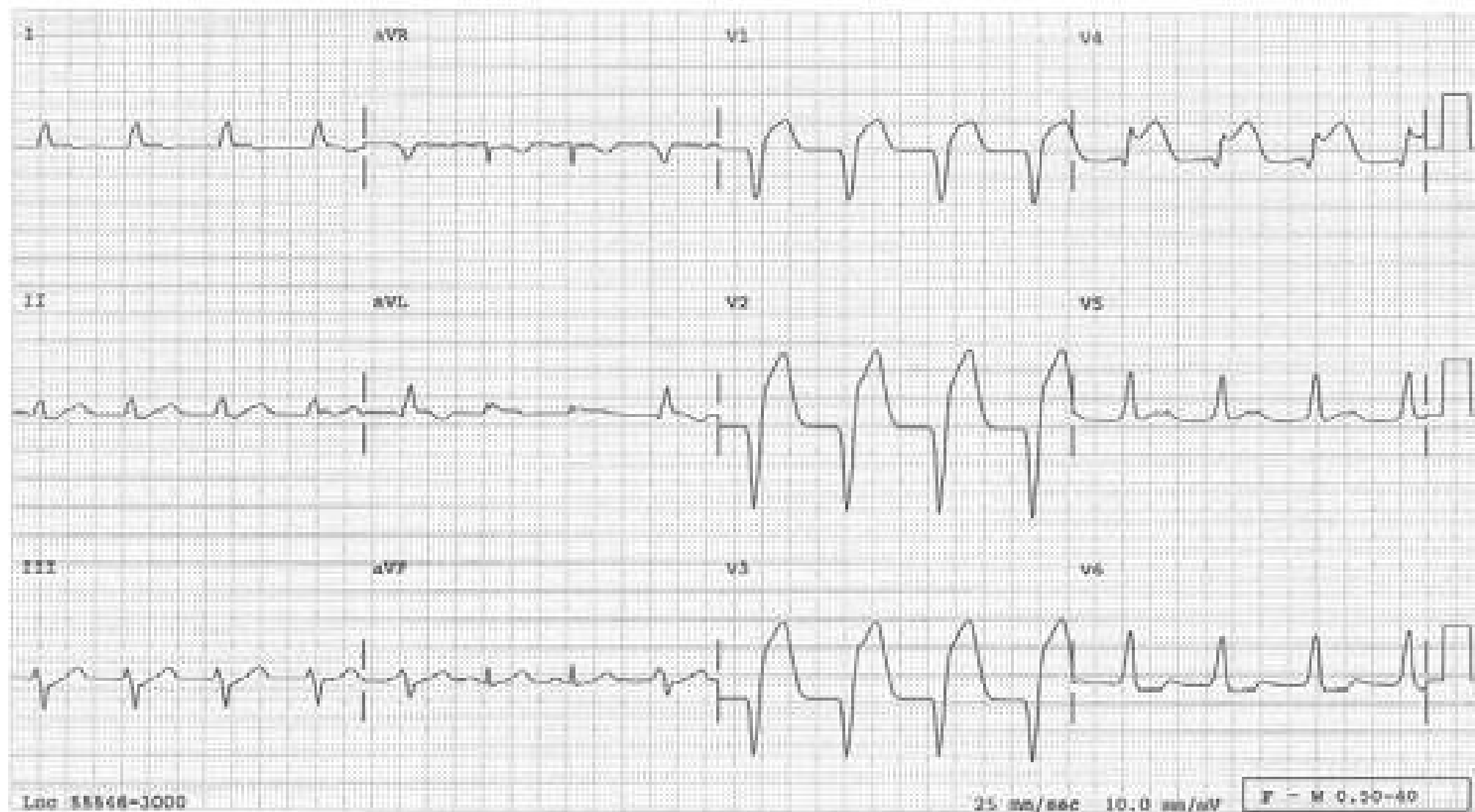
## The QRSs During Ventricular Tachycardia Revealing Infarction Pattern

The QR pattern with ST elevation in V3 is diagnostic of an acute infarction.



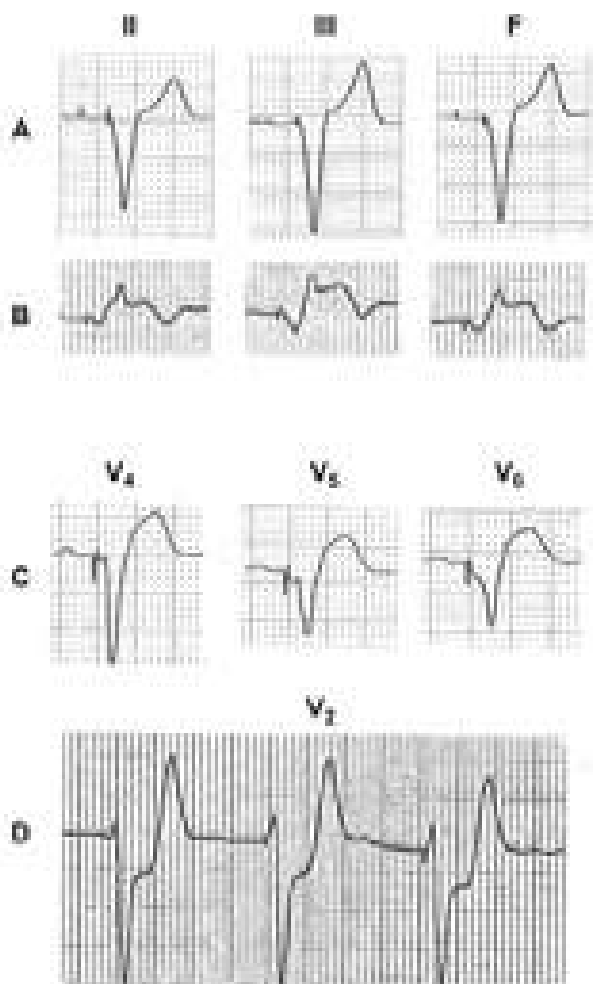
## The QRSs During Accelerated Idioventricular Rhythm Revealing Infarction Pattern

The patient has intermittent accelerated idioventricular rhythm with a sinus rhythm in between (see the leads aVR, aVL and aVF). The qR pattern with ST elevation in V4 is diagnostic of an acute infarction





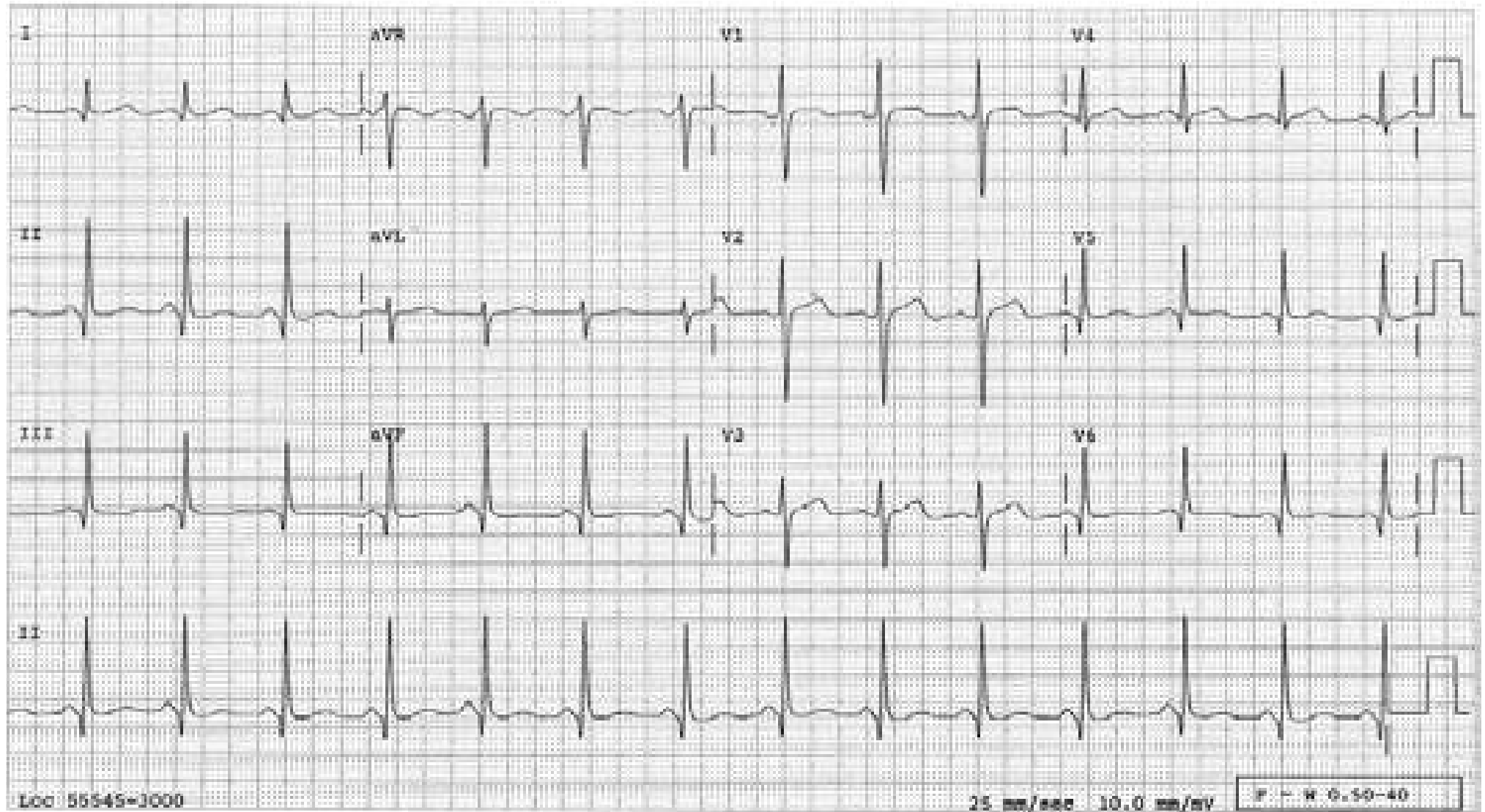
## Ventricularly Paced Complexes Revealing Infarction Pattern



- A: Ventricularly paced complexes in the inferior leads in the absence of an infarction. Since the pacing electrode tip is in the right ventricular apex, most of the inferior leads and precordial leads will normally have a QS pattern with a slight ST elevation as shown. Note the ST segment is concave
- B: QR pattern with ST elevation is diagnostic of an acute Inferior infarction.
- C: "Coved" ST elevation of nearly 5 mm is diagnostic of an acute infarction.
- D: ST segment deviated to the same direction as the major QRS component (concordant or primary ST changes) is diagnostic of an infarction. This is an example of an acute posterior infarction mirror imaged in V2 as ST depression.

## Normal Septal Q Waves

Note that the Q waves are not wide enough ( $<0.03$  s) or deep enough ( $<1/4$  of the R wave amplitude) to be abnormal; they are normal septal Q waves. Of these two criteria, the width has more weight than the depth, i.e., a deep but “skinny” Q wave is not diagnostic of an infarct.

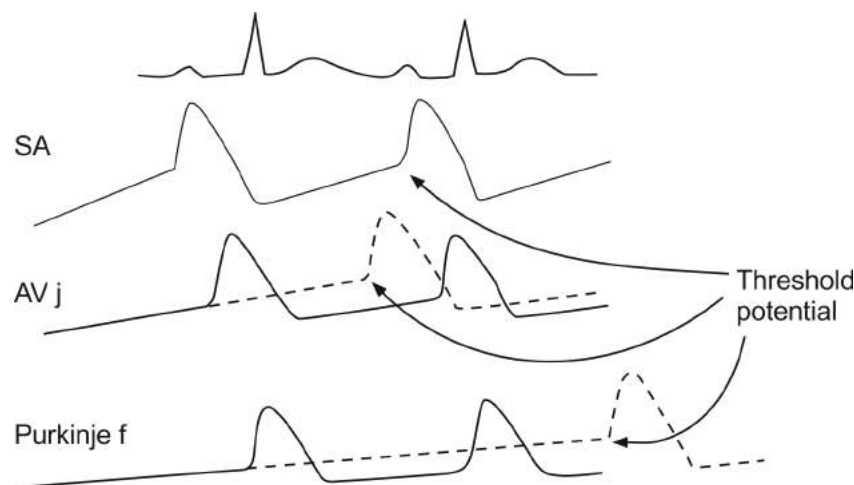


## Simple Electrophysiologic Characteristics of the Conduction System

Understanding simple electrophysiologic characteristics of the cardiac conduction system will facilitate interpretation of arrhythmias.

- a. **Refractoriness:** After depolarization, the myocardial tissue has to be repolarized before it can be depolarized again. During this repolarization period, the myocardial tissue cannot respond to any stimuli and is considered “refractory.” Many ECG manifestations, including AV dissociation in the absence of 3° AV block, aberrant conduction, and concealed conduction, are secondary to this physiologic refractory period.
- b. **Automaticity:** The resting transmembrane potential of the cells in the sinus node, AV junction, and Purkinje fiber do not remain stable. There is a spontaneous, gradual decline in the transmembrane potential (diastolic depolarization or phase 4 depolarization) until it reaches threshold potential. At this time, the tissue is spontaneously depolarized and, therefore, acts as a pacemaker (see the figure below). Normally, it is the sinus node that reaches threshold potential earlier than any other subsidiary pacemaker tissue and dominates the cardiac rhythm. If an impulse from the sinus node fails to reach the AV junction in due time, the AV junctional tissue completes its own diastolic depolarization and is spontaneously activated (AV junctional escape beat). The AV junctional tissue, then, can be considered a “natural” demand pacemaker.

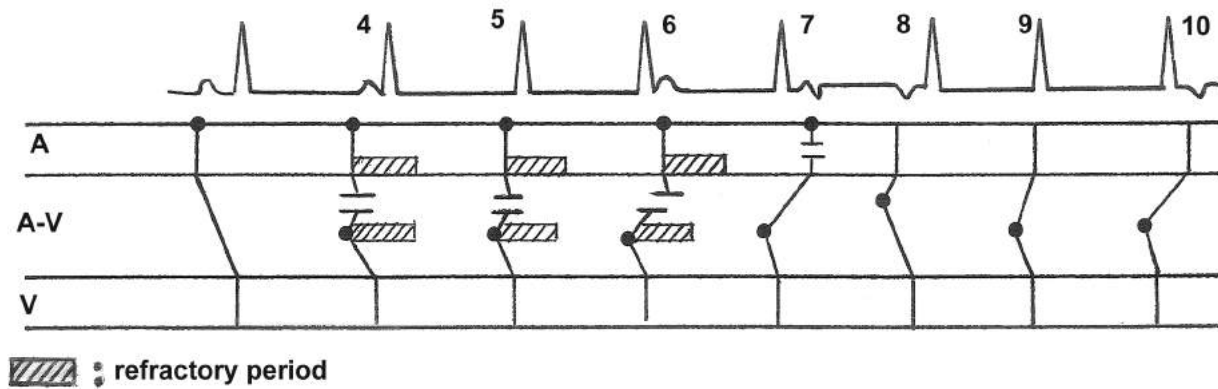
When the slope of the diastolic depolarization of the Purkinje fiber steepens and reaches the threshold potential before that of the sinus node and AV junctional tissue do, an accelerated idioventricular rhythm results.



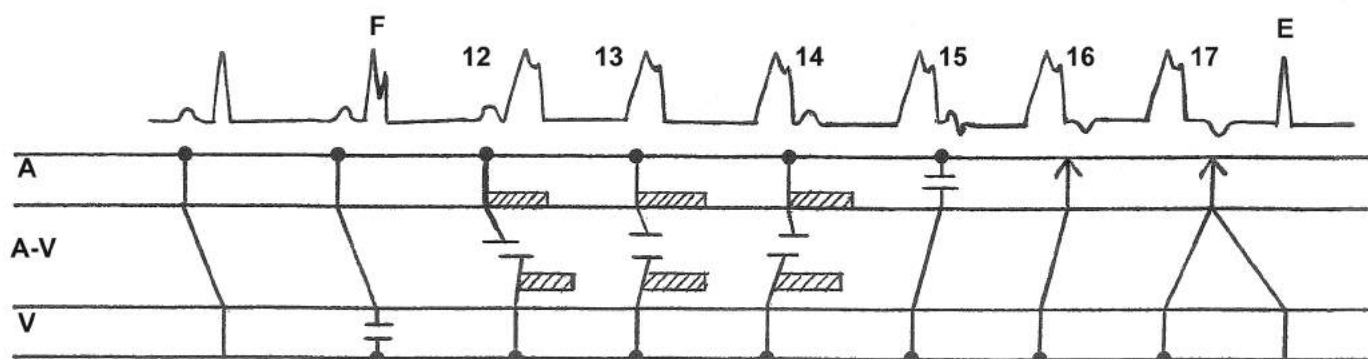
- c. **One lane two-wave traffic:** The conduction system is a one lane two-way traffic pathway; it can transmit the impulse anterogradely as well as retrogradely as long as no impulse is coming from the other side.
- d. **“No reserved seats”:** The atrial or ventricular tissue is not “reserved” for the impulse coming from the sinus node, but it can respond to stimuli coming from any source, as long as the tissue is out of the refractory period. At times, impulses from two different sources (e.g. sinus node and AV junction or sinus node and ventricle) “compete to occupy” the atria or ventricles. The impulse that reaches the atria (or ventricles) first will activate the chambers, as long as the chambers are out of the refractory period.

Let's examine how these "refractory period", "one lane two-way traffic" and "no reserved seats" are applied to the manifestation of impulses originating from the AV junction or ventricle.

An impulse from the AV junction conducts anterograde to the ventricles and retrograde to the atria as long as the atria are "available", i.e. not refractory. In that case a retrograde P wave occurs in front (P8), within (P9) or after (P10) the QRS depending upon the time it takes to reach the ventricles and the atria. If the atria have already been activated by the sinus impulses (P4-6) and are refractory by the time the junctional impulse reaches the atria, the impulse won't be able to depolarize the atria. At the same time, the sinus impulses (P4-6) can't conduct to the ventricles because of the refractory period of the conduction system or the ventricular myocardium; AV dissociation results. If a part of the atrium is activated by the sinus impulse and the other part by the junctional impulse, an atrial fusion results (P7). The ladder diagram helps us to visualize what is happening.

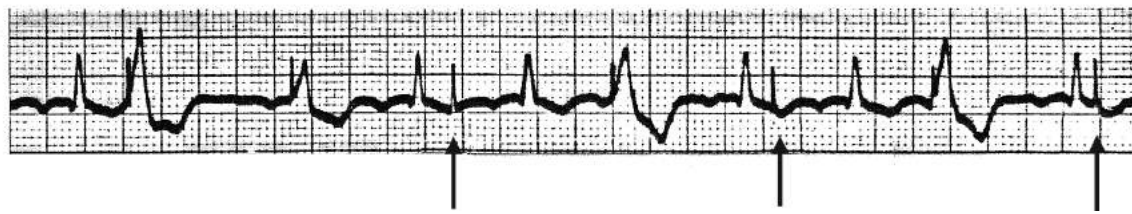


As is the case with junctional impulses, impulses from the ventricle can conduct retrograde to the atria if the atria are "available", i.e. not refractory, resulting in retrograde P waves (P16 and 17). If the atria have already been activated by the sinus impulses (P12-14) and are refractory by the time the ventricular impulses reach the atria, the impulses won't be able to depolarize the atria. At the same time, the sinus impulses (P12-14) can't conduct to the ventricles because of the refractory period of the conduction system or the ventricular myocardium; AV dissociation results. If a part of the ventricle is activated by the sinus impulse and the other part is activated by the ventricular impulse, a fusion beat (F) (hybrid of sinus and ventricular beats) occurs. If the retrograde P wave (P17) occurs some distance away from the QRS so that the conduction system has recovered from the refractory period, the impulse can conduct to the ventricles again, resulting in an echo (reciprocal) beat (E). This echo beat requires dual AV conduction pathways. P15 is an atrial fusion as explained for P7 in the above diagram.



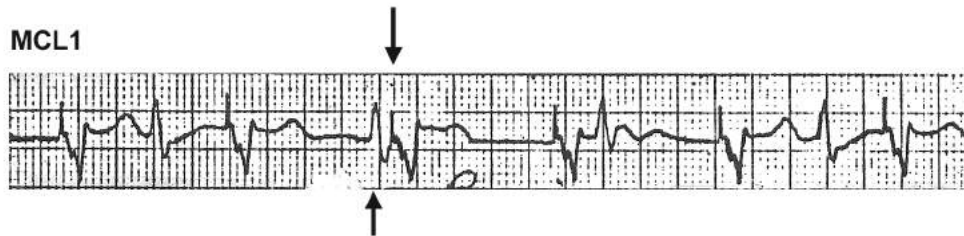


MCL1

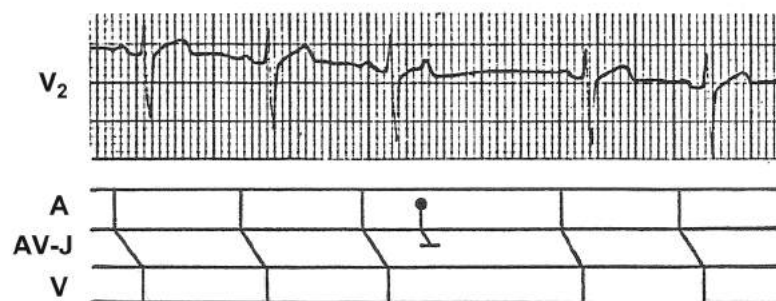


An ECG taken from a patient with a fixed rate electronic pacemaker implanted in the right ventricle. Many pacemaker spikes (↑) do not result in a QRS because the ventricular myocardium is refractory at that time.

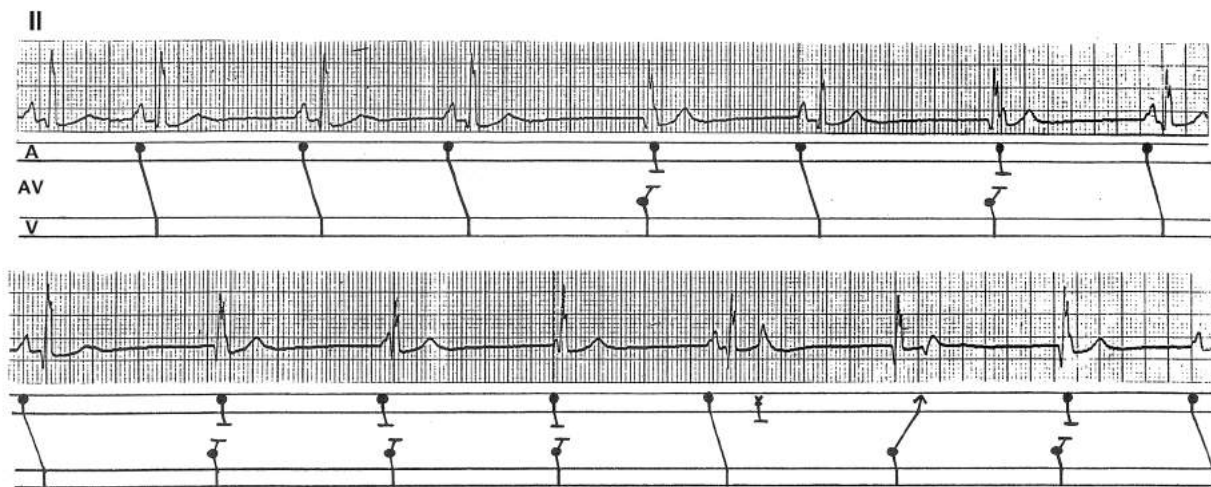
MCL1



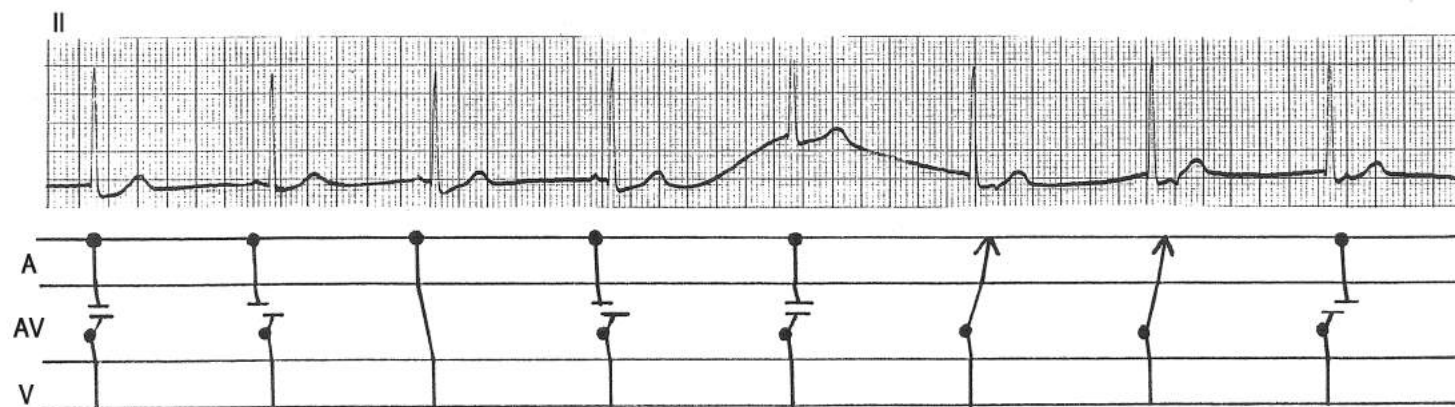
An ECG taken from a patient with a demand-mode electronic pacemaker implanted in the right ventricle. It was erroneously concluded that the third pacemaker spike (↓) failed to sense the QRS, thinking that the deflection in front of it (↑) was a QRS. When one considers the refractory period, the pacemaker spike could not have initiated a QRS if the deflection preceding it was a QRS (see upper tracing). Actually it was a magnified P wave and the pacemaker was functioning normally.



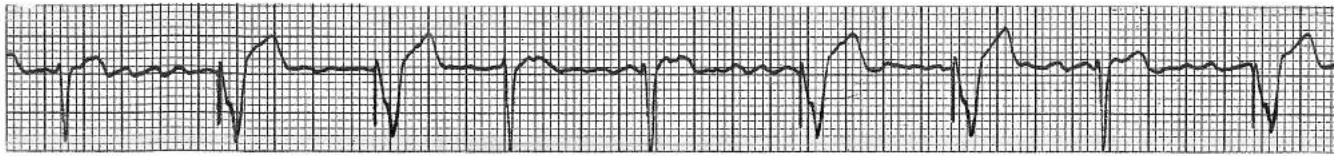A non-conducted APB because it is occurring during the refractory period of the AV conduction system.



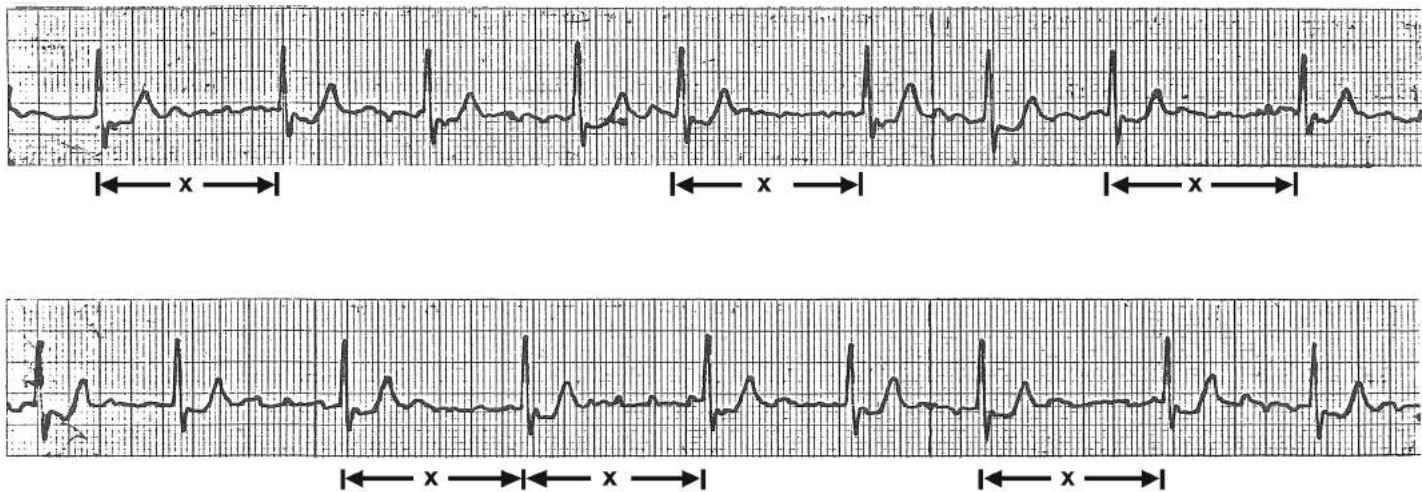
A slow and irregular sinus mechanism allows the AV junctional pacemaker to escape from time to time, resulting in momentary AV dissociation. Given the opportunity, the atrial impulse has no difficulty conducting to the ventricles, and the junctional impulse has no difficulty conducting retrogradely to the atria (the 6<sup>th</sup> complex in the lower tracing). Thus, there is no AV block, either anterograde or retrograde, in this patient. Yet, there is AV dissociation. The AV dissociation occurs because of the physiologic refractory period of the conduction system or the myocardial tissue. The refractoriness of the atrial tissue prevents the junctional impulse from conducting retrogradely to the atria and the refractoriness of the AV junctional tissue or the ventricle prevents the atrial impulse from conducting to the ventricles.



An example of AV dissociation secondary to the slowing of the sinus mechanism which allows the AV junctional pacemaker to escape. When timed right, the atrial impulse has no difficulty conducting to the ventricle (ventricular capture) as illustrated by the third complex. The proof that this complex is induced by the atrial impulse is that it occurs at a shorter R-R interval than the junctional complexes. Also, the AV junctional impulse has no difficulty conducting retrogradely to the atria (atrial capture) as illustrated by the sixth and seventh complexes.

**MCL1**

This patient, who has an electronic demand pacemaker implanted in the right ventricle, is in atrial fibrillation. Whenever the patient's natural QRS does not occur within the set interval, the electronic pacemaker is discharged and a paced QRS results. This is how a demand pacemaker is designed to function, i.e., the pacemaker discharges "on demand". The AV junctional tissue functions just like an electronic demand pacemaker. Hence, it can be considered a "natural" demand pacemaker. An AV junctional escape complex will emerge whenever a chance occurs. The chance may be provided by a slowing of the sinus mechanism, a pause due to resetting of the sinus mechanism from a non-conducted APB, the compensatory pause after a VPB, 2:1 AV block, atrial fibrillation with long pauses, atrial flutter with high grade AV block, etc. Examples of these are shown in the following tracings.

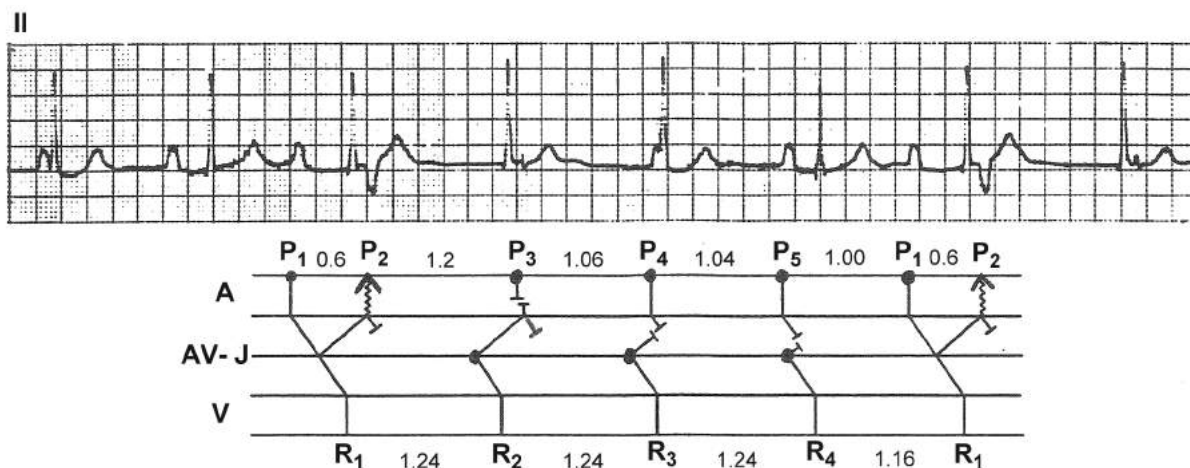
**II**

This is an example of the "natural" demand pacemaker in the AV junction in action. This patient is in atrial fibrillation and all QRSs have the same morphology. Careful observation reveals that:

- The R-R interval marked by "X" recurs several times.
- There is no R-R interval longer than cycle X.

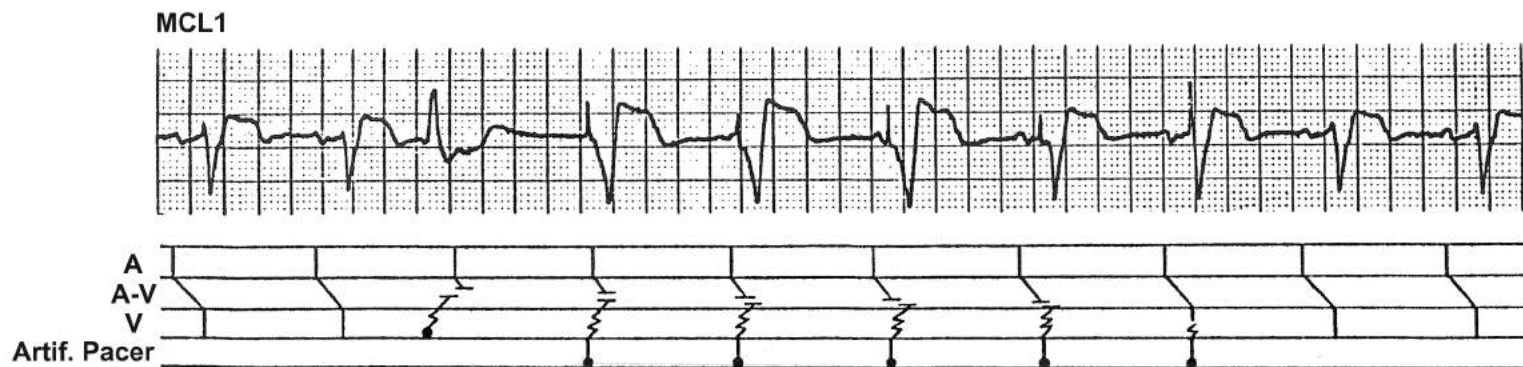These suggest that the QRSs ending distance X are actually AV junctional escape complexes. Since they are all conducted through the normal intraventricular conduction system, the QRS configuration remains constant.





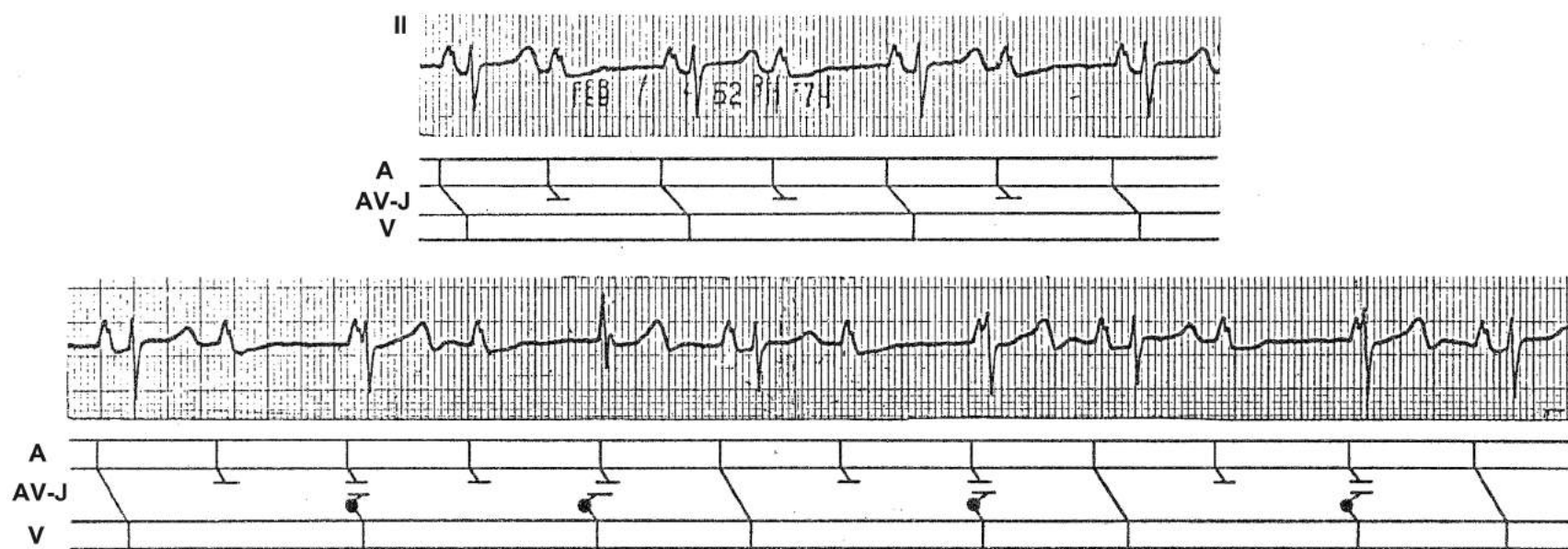
This patient has a several year history of 1° AV block with a PR interval of about 0.40s. When the sinus impulse turns around in the AV junction (due to the dual AV nodal pathway) and reaches the atria, the atria will have recovered from the refractory period because of the long PR interval. They are depolarized retrogradely, resulting in a negative P wave (P2). The sinus node is also reset which allows the AV junctional pacemaker to escape for the subsequent three beats until the P wave occurs early enough to repeat the cycle again (P1). At first glance, P5 and R4 appear to be associated. But the fact that the R3-R4 interval is identical to R1-R2 and R2-R3 intervals indicates that R4 also is a junctional beat. This is an example of AV dissociation in the absence of 3° AV block where the ventricular rate is slower than the atrial rate, yet AV dissociation results.

The primary disorder in this patient is 1° AV block. The other phenomena (retrograde conduction to the atria, resetting of the sinus mechanism, AV junctional escape, and momentary AV dissociation) are all inevitable secondary consequences of this primary disorder. This tracing illustrates the fact that the ECG manifestations of many arrhythmias can be dissected into a primary disorder and secondary responses. Sometimes, these secondary responses are what make the tracing look so complicated.



This patient has an electronic demand pacemaker implanted in the right ventricle. The compensatory pause following a premature beat (the third QRS) allows this demand pacemaker to escape for the subsequent five beats. During this period, the atria are controlled by the uninterrupted sinus mechanism while the artificial demand pacemaker paces the ventricles. Because of the physiologic refractory period of the conduction system, AV dissociation results. This is another example in which the ventricular rate is slower than the atrial rate, yet AV dissociation occurs in the absence of 3° AV block.





A quick glance at the lower tracing might suggest that the P waves and QRSs are unrelated, raising the possibility of complete AV block. But the fact that the QRSs are not occurring regularly is a strong evidence against complete block. As the upper tracing shows, the patient has 2:1 AV block and, when the sinus rate slows down from 90/min (upper tracing) to 80/min (lower tracing)—so the two PP intervals become longer than the junctional escape interval, the pacemaker in the AV junction escapes, resulting in AV dissociation. Then, whenever the P wave occurs at just the right (long enough) R-P interval after one of the junctional beats, the atrial impulse conducts to the ventricle, resulting in a capture beat (ending a shorter R-R interval than the AV junctional escape interval). The primary disorder in this patient is 2:1 AV block and the other phenomena, namely AV junctional escape and AV dissociation, are secondary, obligatory responses.

## P-QRS Relationships in Arrhythmias

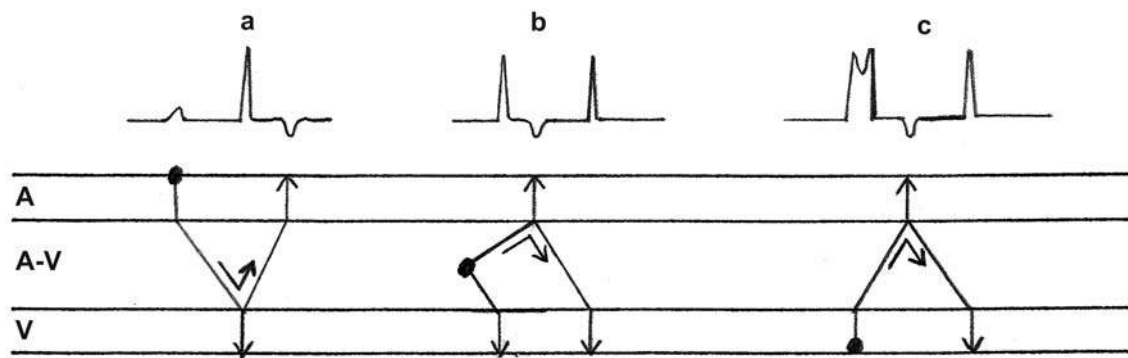
The P-QRS relationships in arrhythmias are largely determined by:

- The physiologic refractoriness of the conduction system or the myocardial tissue.
- The fact that the conduction system carries two way traffic and can transmit the impulse anterograde as well as retrograde.
- The fact that the atrial or ventricular tissue responds to impulses coming from any sources so long as the tissue has recovered from the refractory period.

(See page 92)

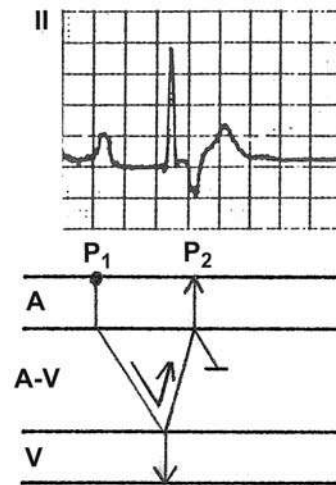
### Reciprocal (Echo) Beats

When an impulse turns around within the AV junction and reactivates the same chambers (either atria or ventricles) it has just activated, a reciprocal (echo) beat results as diagrammed below. The initiating impulse may originate from the sinus node (a), atrium (a), AV junction (b) or ventricle (c). For this phenomenon to occur, dual AV junctional pathways are necessary. The way the ladder diagrams are customarily drawn, the impulse within the AV junction seems to “bounce off” the atrial or ventricular wall, which is the reason why this beat is also called “echo” beat. However, the term reciprocating describes the phenomenon more accurately than the term echo.

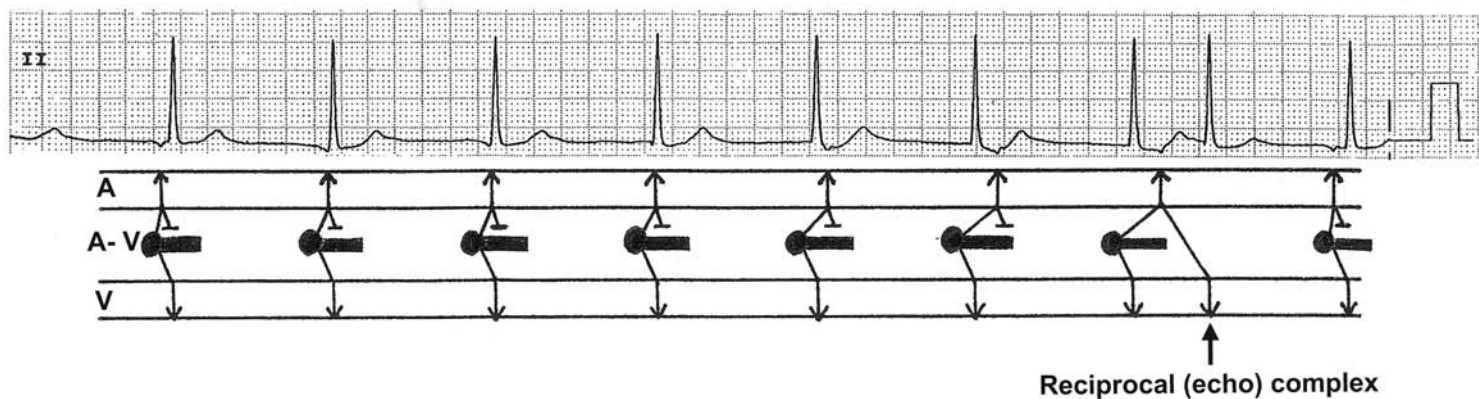


## An Atrial Echo Beat

In this tracing, the P1 is conducted to the ventricle through the slow pathway (note the long PR interval). The impulse travels retrogradely within the AV junction through the fast pathway and by the time it reaches the atria, the atria have recovered from the refractory period (owing to the long PR interval) and are reactivated retrogradely (P2): an atrial echo. This impulse can turn around and reactivate the ventricles and, if the process continues, re-entrant tachycardia can result.

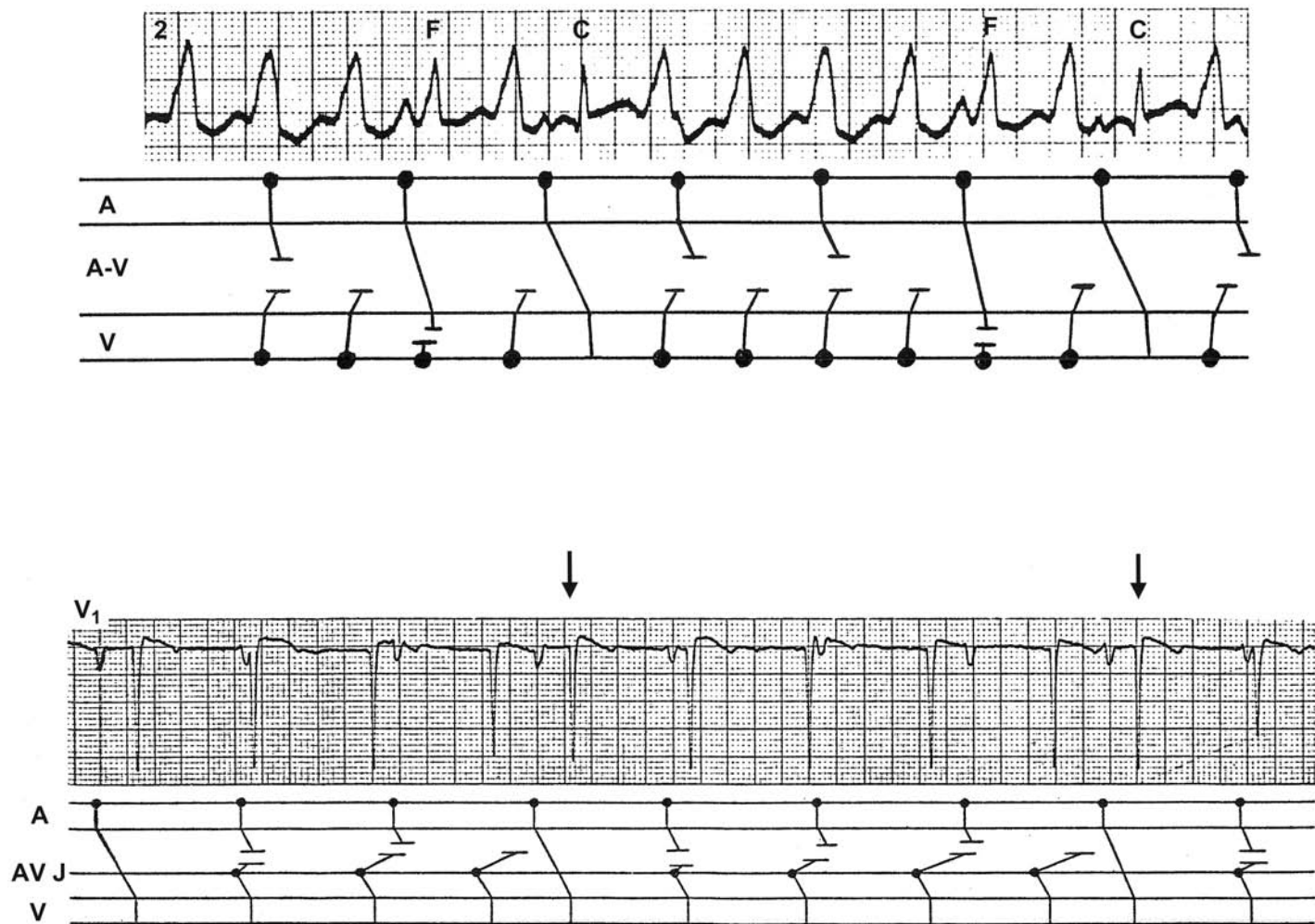


Sinus bradycardia or sinus node dysfunction allows an AV junctional pacemaker to escape with a 1:1 retrograde conduction to the atria. The retrograde conduction to the atria is probably through the fast pathway. The retrograde P waves are present in front of, then within, then after the QRSs with progressively lengthened conduction time. Each time, the impulse turns around within the AV junction and travels—probably through the slow pathway—down towards the ventricle. However, the intraventricular conduction system or ventricular myocardium is refractory and the ventricle cannot be depolarized until the seventh complex when, owing to the long RP interval, the intraventricular conduction system or ventricular myocardium has now recovered from the refractory period and another QRS results (a reciprocal or echo beat).



## Ventricular Capture Beats

During an episode of AV dissociation due to either ventricular or AV junctional rhythm, if an atrial impulse occurs at a time when the conduction system and the ventricular myocardium are not refractory, the impulse will be conducted to the ventricles. In this situation, one may consider that the ventricles are “captured” by the sinus impulse; hence a capture beat. The hallmark of the captured QRS is that it occurs early, compared with cycles of the independent rhythm. The QRSs labeled “C” in the upper tracing of ventricular tachycardia (from Marriott’s *Practical Electrocardiography*) and the QRSs with arrows in the lower tracing are examples of capture beats. The ladder diagrams are helpful in visualizing what is happening.



## Fusion Beats

During an episode of AV dissociation due to ventricular tachycardia, if an atrial impulse captures only part of the ventricular myocardium while the other part is depolarized by the impulse from the ventricular ectopic focus, the resulting QRS is a “fusion” beat (the QRSs labeled “F” in the upper tracing).



## AV Dissociation

AV dissociation is defined as the independent beating of atria and ventricles. The atria are under the control of one pacemaker (mostly sinus node and rarely an ectopic atrial focus) while the ventricles are under the control of another pacemaker (either AV junctional or ventricular focus). Complete (3°) AV block will certainly manifest AV dissociation but AV dissociation can occur without complete AV block.

During sinus (rarely ectopic atrial) rhythm, if a QRS from another source (AV junction or ventricle) occurs close to a P wave so that the QRS and the P wave fall within the physiologic refractory period of each other, the impulse that causes the QRS can't conduct to the atrium and the impulse from the atrium can't conduct to the ventricle. Thus, AV dissociation results in the absence of complete AV block. This may occur for a single beat or more than a single beat.

The following are situations which may result in AV dissociation:

- A. Some cases of:
- AV junctional escape beat or rhythm
  - AV junctional premature beat
  - Accelerated AV junctional rhythm
  - AV junctional tachycardia
  - Ventricular premature beat
  - Accelerated idioventricular rhythm
  - Ventricular tachycardia
  - Ventricular paced rhythm

The prerequisite for AV dissociation to occur in these situations is that the P wave and the ectopic QRS occur close to each other, i.e., within the physiologic refractory period of each other. There need be no complete AV block. Therefore, if a P wave occurs outside of the ventricular refractory period, it will conduct to the ventricle (ventricular capture). If a QRS occurs outside of the atrial refractory period, the impulse will conduct to the atrium (atrial capture). These captures are useful in that they prove the absence of AV block, anterograde or retrograde.

In AV dissociation without AV block, the ventricular rate is slightly faster than the atrial rate. Otherwise, the sinus mechanism would not allow subsidiary pacemakers a chance to manifest. However, this kind of AV dissociation can occur transiently even when the ventricular rate is slower than the atrial rate. For example, if the pause after a VPB or the pause from resetting of the sinus mechanism is slightly longer than the AV junctional escape interval, the AV junctional pacemaker will manifest for several beats resulting in AV dissociation until the sinus impulse catches up with the junctional rhythm (see pages 97 and 108).

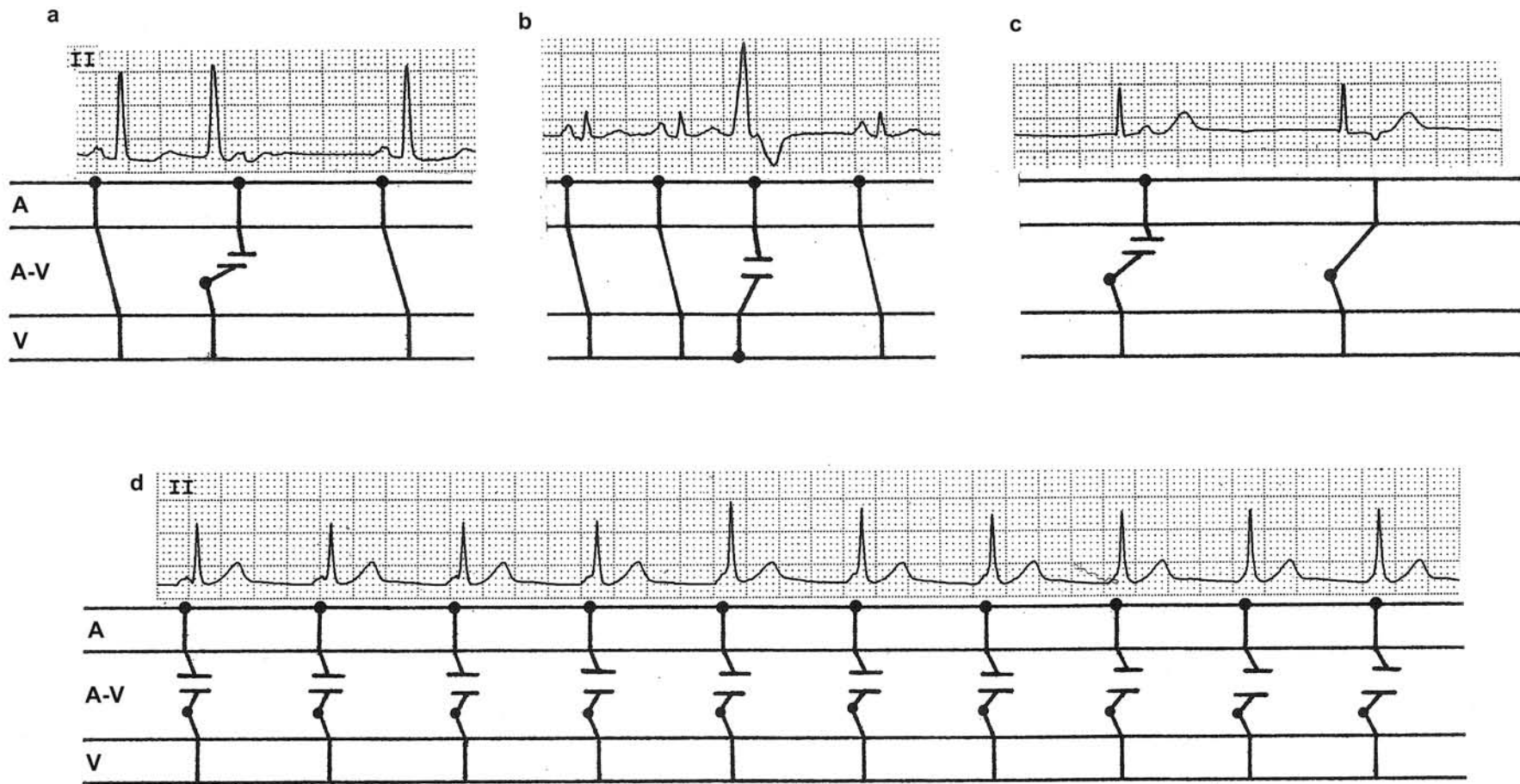
- B. All cases of complete (3°) AV block:

The AV dissociation in this situation is due to the "bridge" connecting the atrium and the ventricle (AV conduction system) being broken. Consequently, no matter how the P wave is timed in relation to the QRS, the impulse won't be conducted to the ventricle.

### Thus:

1. AV dissociation is not synonymous with complete AV block. And, complete AV block should not be called complete AV dissociation, unless one is willing to say "complete AV dissociation resulting from complete AV block," which certainly is redundant. Even then it is not right because one is putting the less important feature (AV dissociation) in front of the more telling feature, complete AV block.
2. AV dissociation merely indicates the independent beating of the atria and the ventricles. It tells nothing about the primary rhythm disorder, which after all is what matters. It is clear that what is important is the fact that the patient is in ventricular tachycardia or accelerated junctional rhythm, not whether the P waves and QRS are dissociated or not. AV dissociation should be viewed as an inevitable secondary response to a primary disorder.

## Examples of AV Dissociation



AV dissociation with a: Junctional premature beat. b: Ventricular premature beat. c: Junctional escape beat. (The second junctional impulse conducts to the atria because the atria have not been occupied by the sinus impulse and are "available"). d: Junctional pacemaker is accelerated to 75/min which happens to be almost identical to the sinus rate and AV dissociation results.

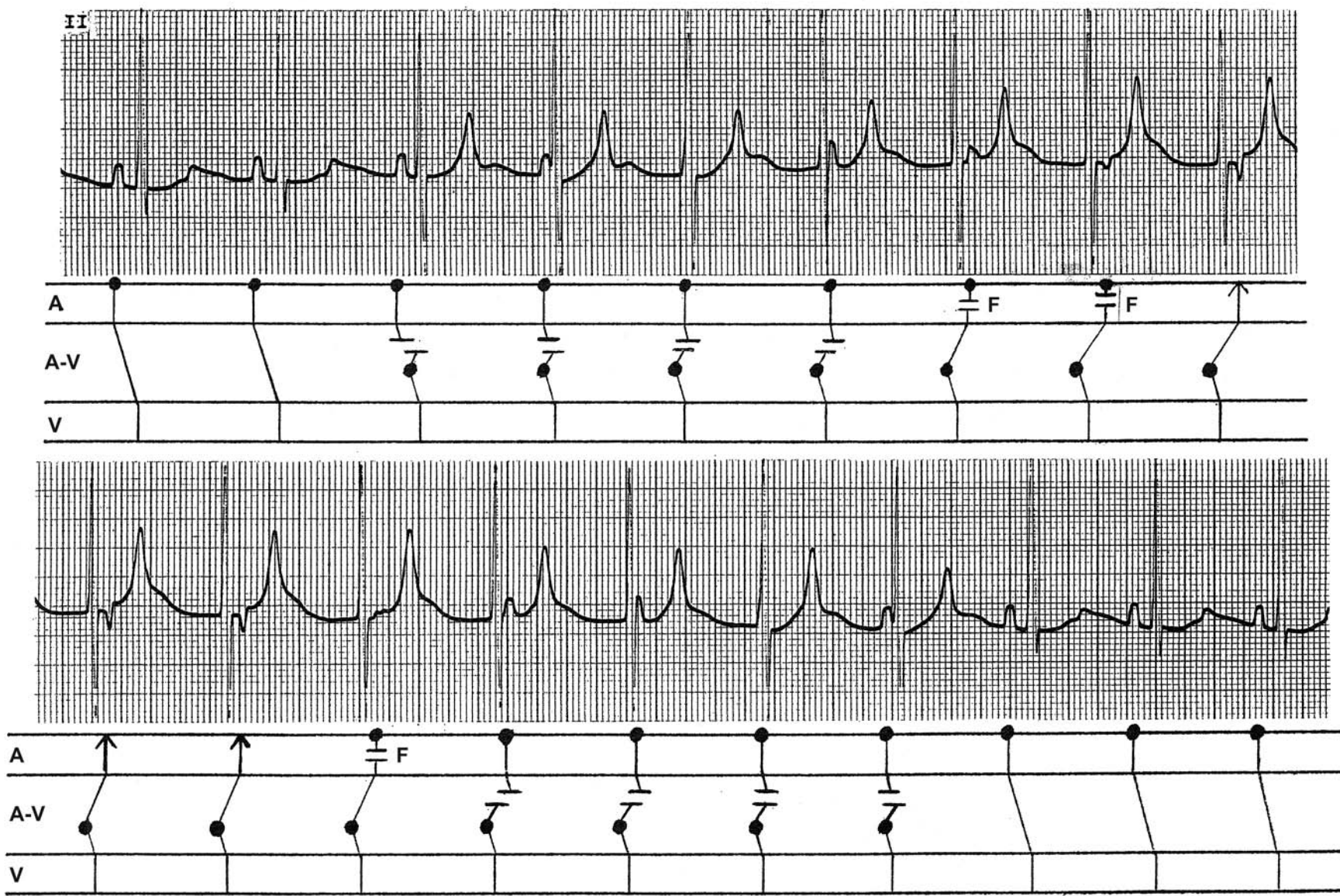### Accelerated AV Junctional Rhythm with AV Dissociation, Atrial Capture and Atrial Fusion (continuous strip)

A good example for visualizing how AV dissociation can occur in the absence of AV block. Sinus rhythm is present at the beginning. The third QRS originates from the AV junction, which occurs slightly before the next sinus beat is due. The impulse from the AV junction cannot conduct to the atrium since the atrial tissue is physiologically refractory because it has just been depolarized by the sinus impulse. The sinus impulse cannot conduct to the ventricle since the AV conduction system is physiologically refractory because it is depolarizing. AV dissociation results. The same situation repeats itself during the subsequent three QRSs. Notice that the P wave gradually falls behind the QRS as the sinus rate gradually slows further. This will eventually allow the AV junctional impulse to conduct to the atrium (atrial capture) resulting in a negative P wave as happens following the last QRS in the upper strip and the first two QRSs in the lower strip. But before the atria are fully captured, the gradually ascending retrograde impulse effects partial capture producing two fusion P waves (F). Thus, two pacemakers (sinus node and AV junctional pacemaker) are competing to occupy the atria and whichever wins the race will occupy the atria.

As the sinus rate speeds up gradually in the second strip, the sinus impulse regains control of the atria resulting in positive P waves but not soon enough to conduct to the ventricles, and the ventricles continue under the control of the AV junctional pacemaker and AV dissociation again results. Eventually, as the sinus rate speeds up further and clearly precedes the junctional impulse, it not only controls the atria, but also is able to conduct to the ventricle—as happens with the last three QRSs.

It is clear that the AV dissociation in the middle of the upper and lower strips happens because the AV junctional pacemaker is accelerated and occurs slightly ahead of the sinus impulse so that the P waves and the QRSs fall within each other's physiologic refractory period. The absence of complete AV block, anterograde or retrograde, is amply demonstrated. The primary disorder in this case is AV junctional acceleration. If it weren't for that, there would have been perfectly normal sinus rhythm. AV dissociation and retrograde conduction to the atria are obligatory responses of the conduction system to the primary disorder. Sorting out the *primary* disorder and *secondary* responses will allow more logical treatment of the condition. The important question is why the AV junctional pacemaker in this patient is accelerated—it could be due to digitalis intoxication, myocardial ischemia or infarction, etc.

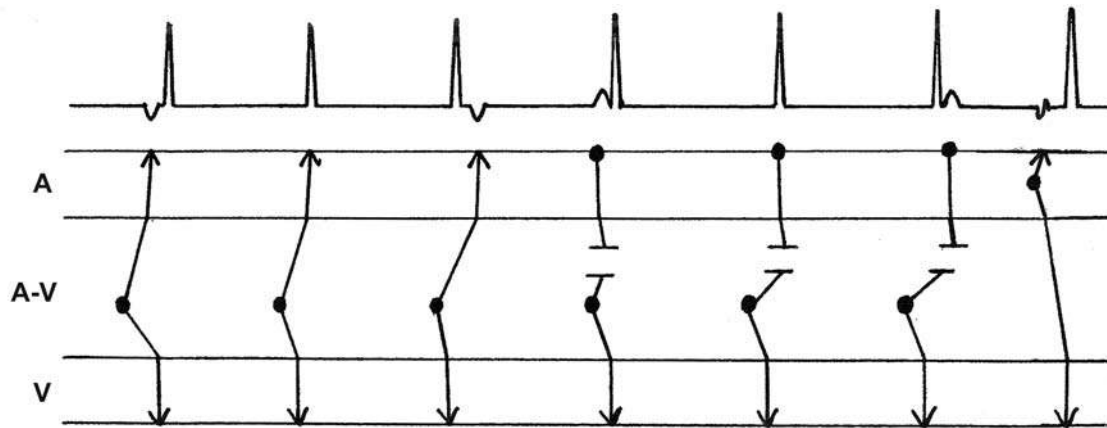






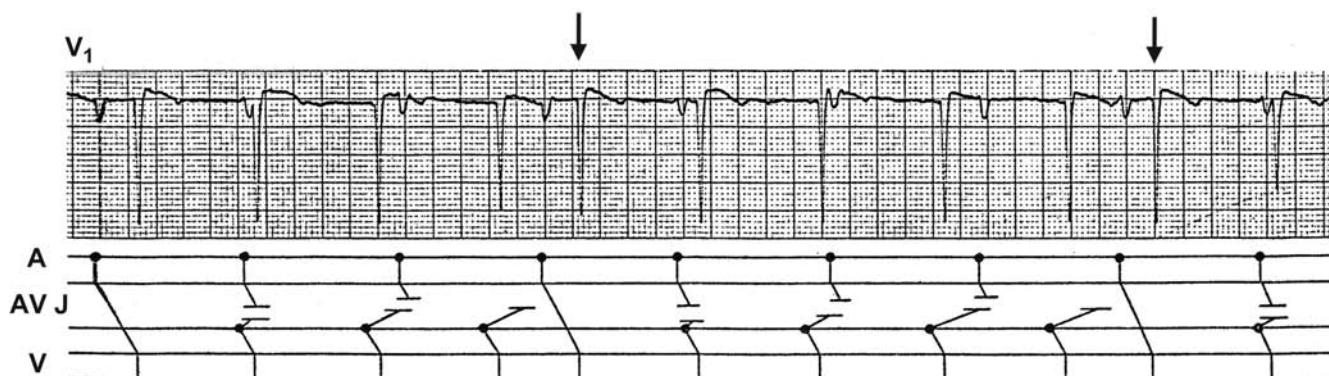
## A Ladder Diagram of AV Junctional Complexes

The first three junctional impulses are conducted retrogradely to the atria, resulting in a negative P wave in front, hidden within, or after the QRS. This happens because the atria are not yet activated by the sinus impulse and are “available” to the junctional impulse. With the next three junctional impulses, the atria are depolarized by the sinus impulse. The result is AV dissociation with a positive P wave visible in front of, hidden within, or after the QRS. Thus, a junctional beat will always manifest in one of these six ways in terms of the P-QRS relationship. The last QRS is conducted from an atrial premature impulse and this QRS occurs with a shorter R-R interval than other QRSs, which is the hallmark of a “capture” beat or “ventricular capture.” This capture beat proves that there is no AV block.



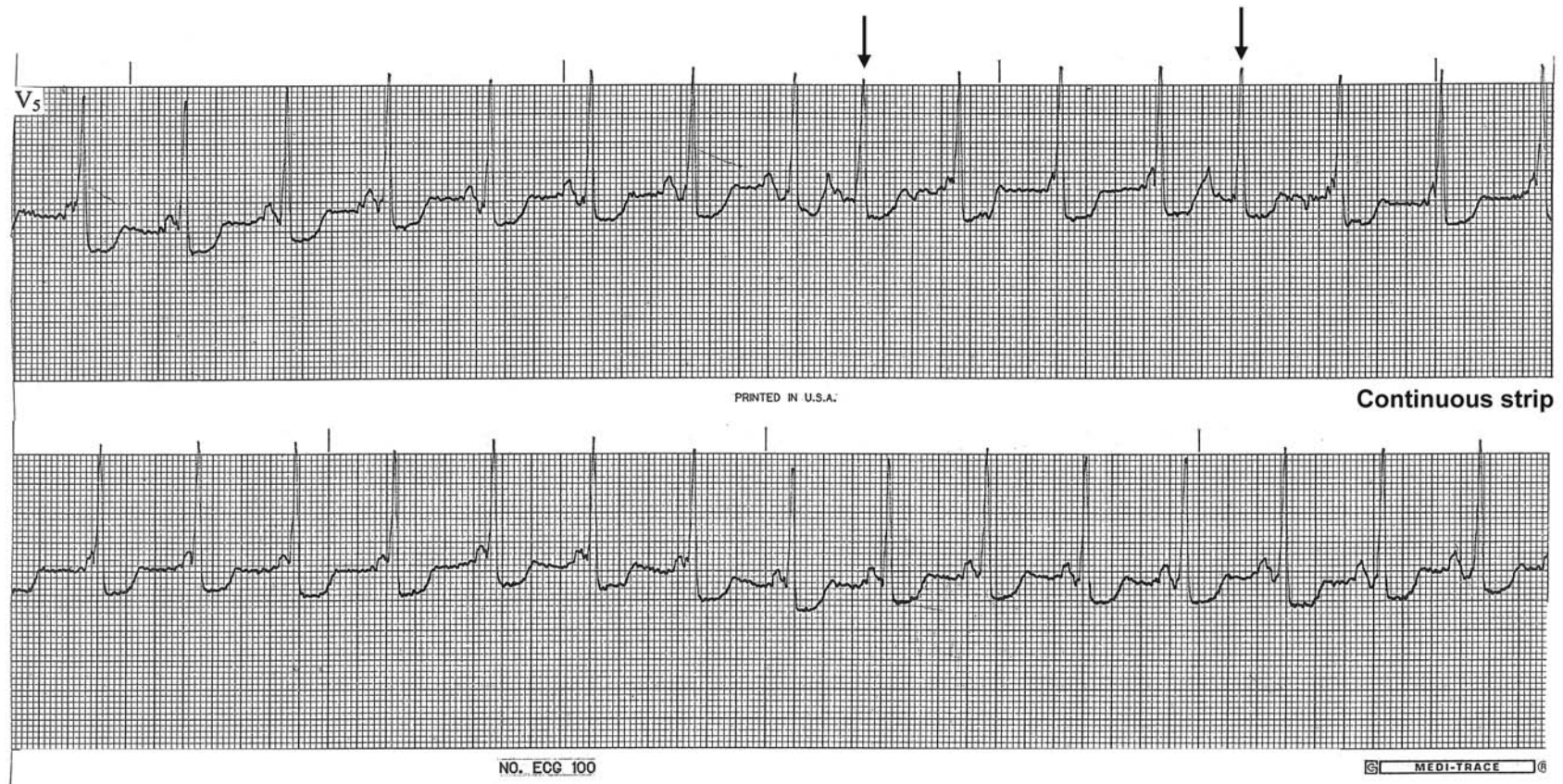In the tracing below, the pacemaker in the AV junctional tissue is accelerated and fires at approximately 70/min. The sinus rate is slower than this and AV dissociation results. When the P wave occurs at the right time, the impulse conducts to the ventricle, resulting in a capture beat (↓). This kind of AV dissociation is also called interference dissociation. The word interference in this situation is used differently by different schools. One school uses the term to imply that the capture beats are interfering with the regularity of the junctional rhythm. Another school uses the term to imply that two pacemakers are interfering with each other's impulse propagation by rendering the conduction system or myocardial tissue physiologically refractory. Ironically, then, the capture beats which make the rhythm “interfered” according to one school are the only complexes that are not interfered according to the other school.

The primary disorder in this tracing is AV junctional acceleration, which may be due to digitalis intoxication, myocardial ischemia or infarction, etc. AV dissociation may be more eye-catching, but is merely a secondary, obligatory response of the conduction system to the primary disorder.



## Isorhythmic AV Dissociation

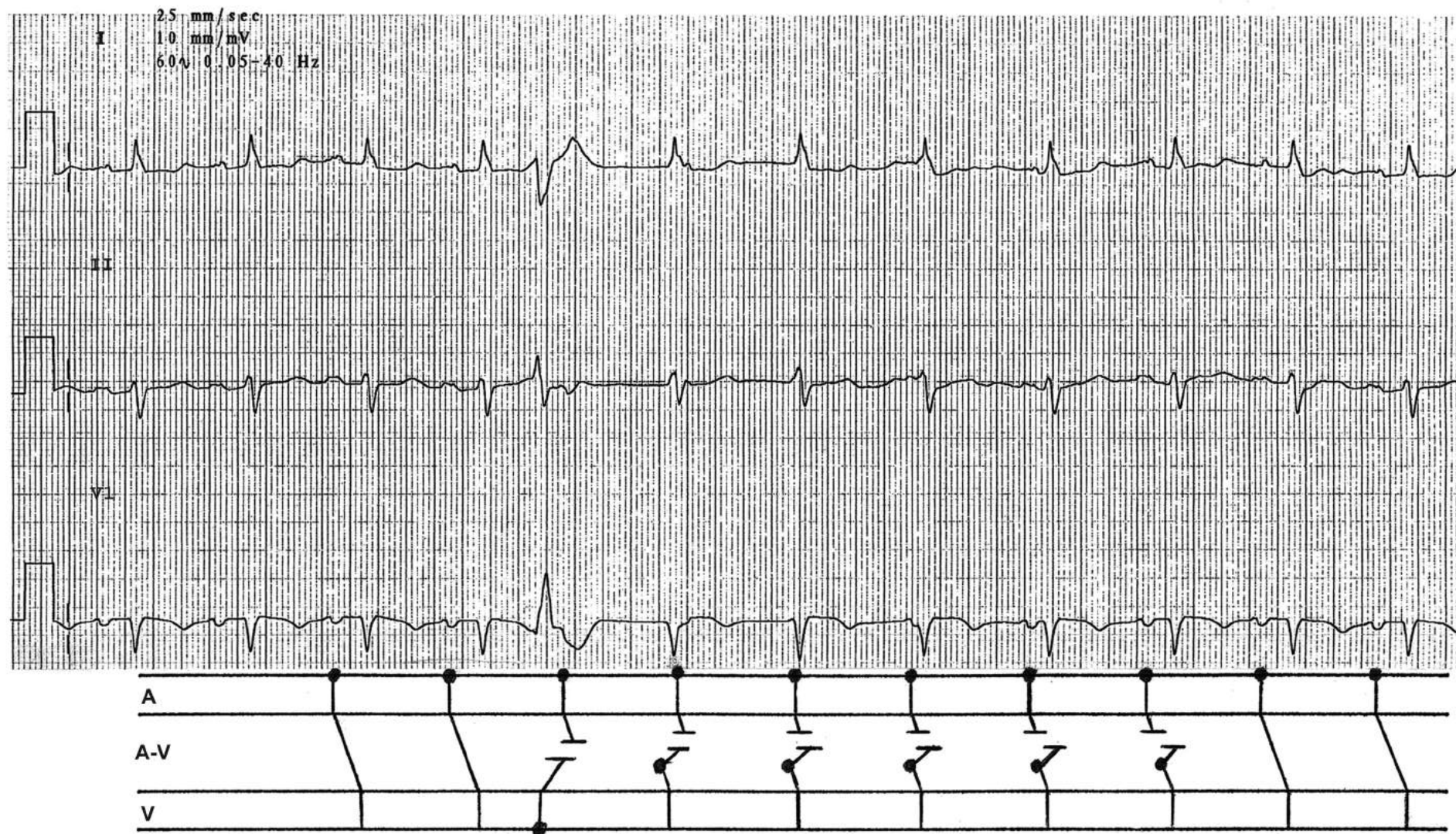
In the case of AV dissociation resulting from accelerated junctional rhythm, if the AV junctional rate is approximately the same as that of the sinus node, the atria and ventricles will beat, independent of each other, at almost the same rate. This situation is called “isorhythmic” AV dissociation and is seen in the first half of the second strip. Most interference AV dissociations are isorhythmic after all. In the upper strip, two APBs conduct to the ventricles (↓) resulting in a shorter R-R interval (capture beats). These captured beats prove that there is no AV block.





### Transient AV Dissociation Due to the Pause Following a VPB

The compensatory pause following a VPB allows an accelerated junctional rhythm to manifest for 5 beats. During this period, the atrial and junctional impulses occur close together within the physiologic refractory periods of each other, and AV dissociation results. Note that the sinus rate is slightly faster than the junctional rate, indicating that the junctional rate does not have to be faster than the sinus rate for AV dissociation without AV block to occur.

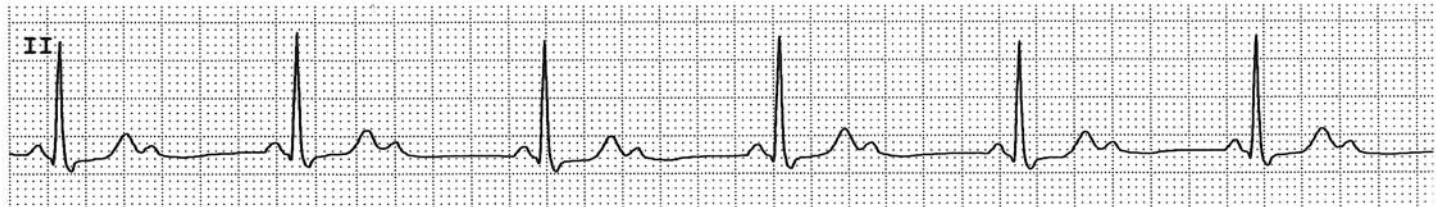
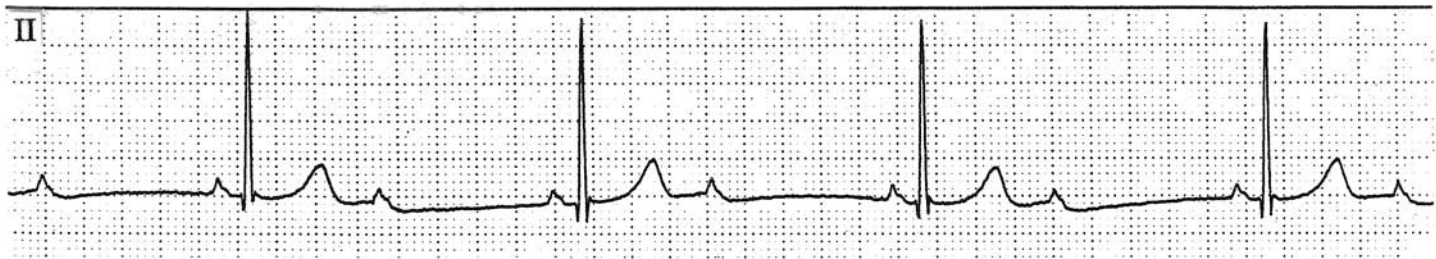


## Ventriculophasic Sinus Arrhythmia

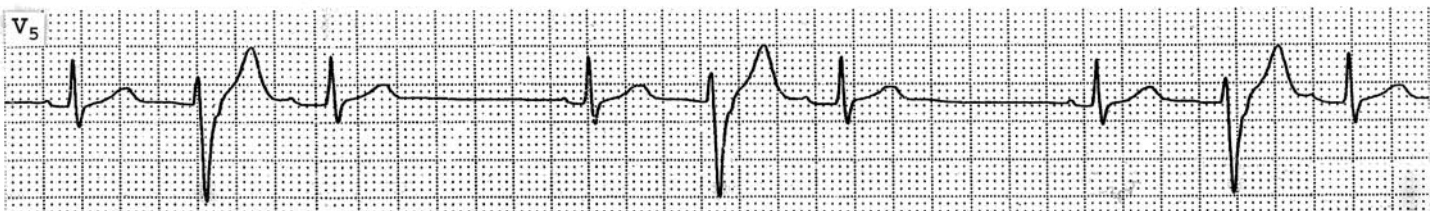
In patients with complete AV block or 2:1 AV block, it is frequently observed that the P-P intervals which encompass a QRS complex are shorter than the P-P intervals which do not. This condition is known as ventriculophasic sinus arrhythmia. It occurs in about 30-40% of cases of complete AV block. Ventriculophasic atrial arrhythmia during PAT with 2:1 AV conduction is more specific for digitalis intoxication.

The following tracings from two different patients exhibit ventriculophasic sinus arrhythmia. 2:1 AV block is evident in both tracings. Note that the P-P intervals which contain a QRS complex are shorter than the P-P intervals that do not.



## Ventriculophasic Sinus Arrhythmia with Interpolated VPBs

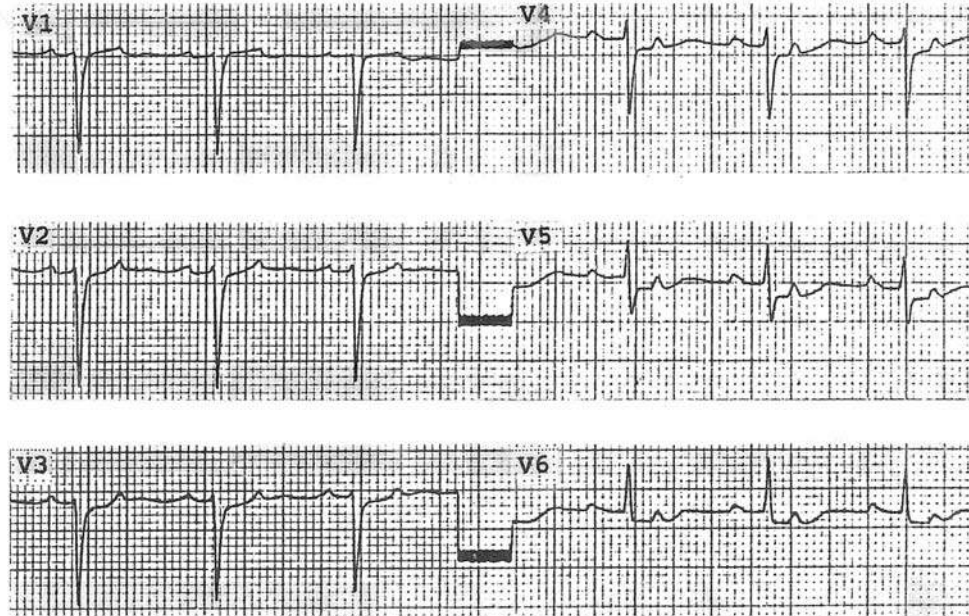
Note that the P-P intervals that contain a VPB are shorter than the P-P intervals that do not.



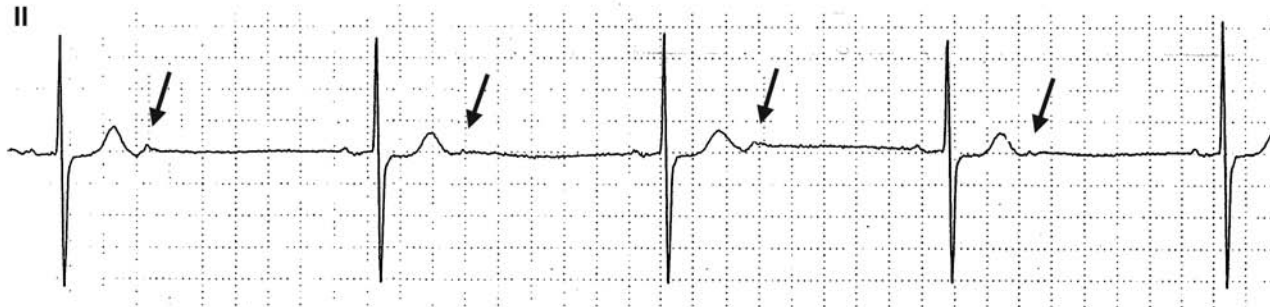


## Atrial Tachycardia with 2:1 AV Block and Ventriculophasic Atrial Arrhythmia

Two P waves are present between the QRSs (see V4, 5 and 6 especially). The P-P intervals that encompass a QRS are slightly shorter than the P-P intervals that do not and the tracing is therefore compatible with PAT with 2:1 AV block and ventriculophasic atrial arrhythmia. Another possibility is that this is a case of non-conducted atrial bigeminy, i.e., alternate P waves are premature P waves that are not conducted to the ventricles due to the refractory period. The two P waves have slightly different morphologies favoring the latter possibility.



An example of non-conducted atrial bigeminy (↓). Note that the two P waves between the QRSs look different and the P-P interval difference is too great for ventriculophasic sinus arrhythmia.

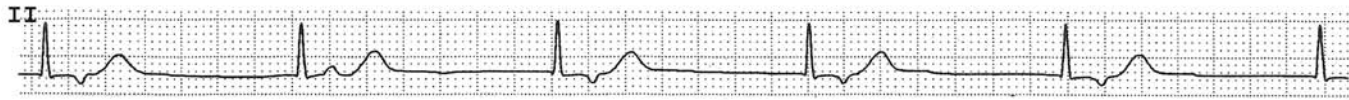


Thus, during a regular rhythm, if there are two P waves between the QRSs, and:

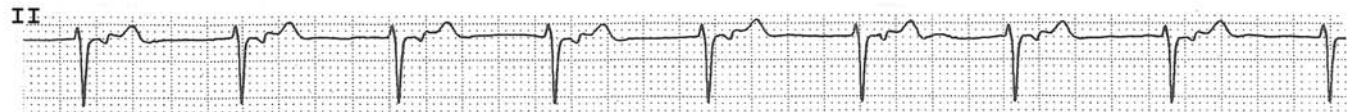
- a. the P waves occur regularly, it is 2:1 AV block.
- b. the P-P intervals that encompass a QRS are shorter than the P-P intervals that do not, and
  - i. the two P waves have identical morphology, it is ventriculophasic sinus or atrial arrhythmia.
  - ii. the two P waves have different morphologies, it is non-conducted atrial bigeminy. Usually in this situation, the P-P interval difference is more marked than in condition (i).

## Retrograde Atrial Conduction

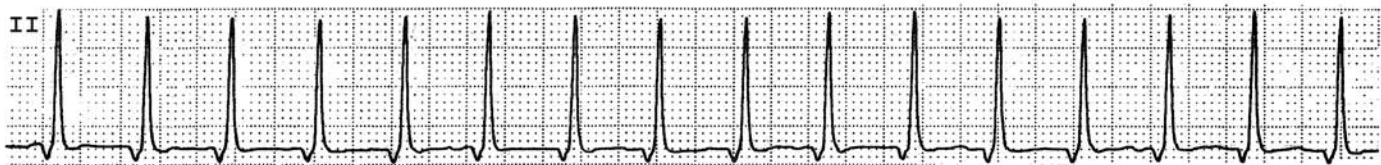### AV junctional escape rhythm with 1:1 retrograde conduction to atria



### Accelerated AV junctional rhythm with 1:1 retrograde conduction to atria

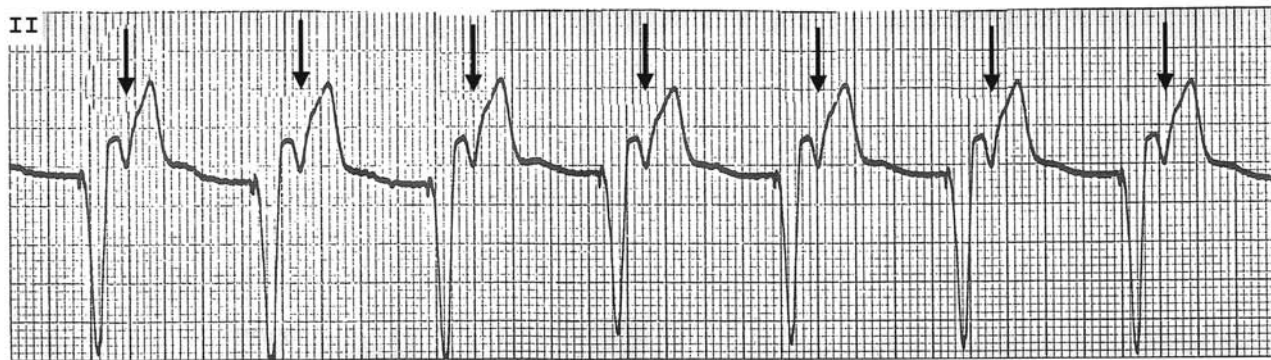


### A-V junctional tachycardia with 1:1 retrograde conduction to atria (see the negative P wave in front of each QRS)

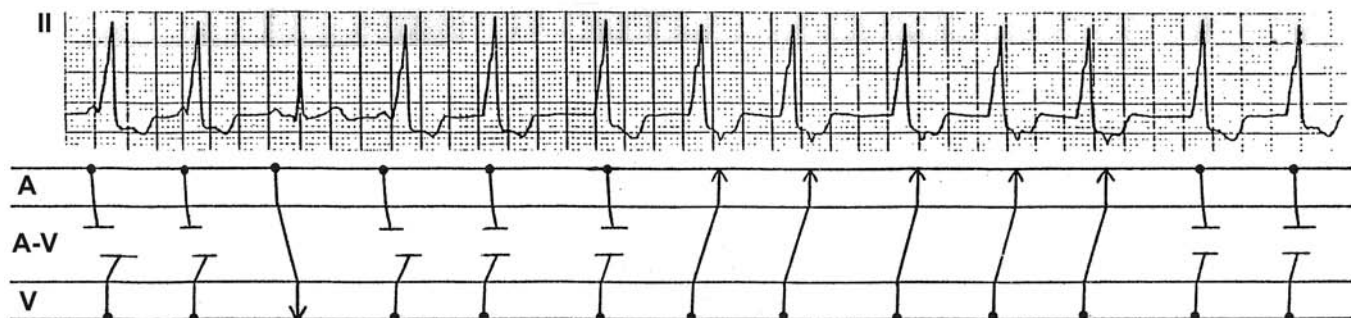


## Ventricular Pacing with 1:1 Retrograde VA Conduction

Every pacer induced QRS is followed by a retrograde P wave (↓). About 15-20% of these patients develop pacemaker syndrome.

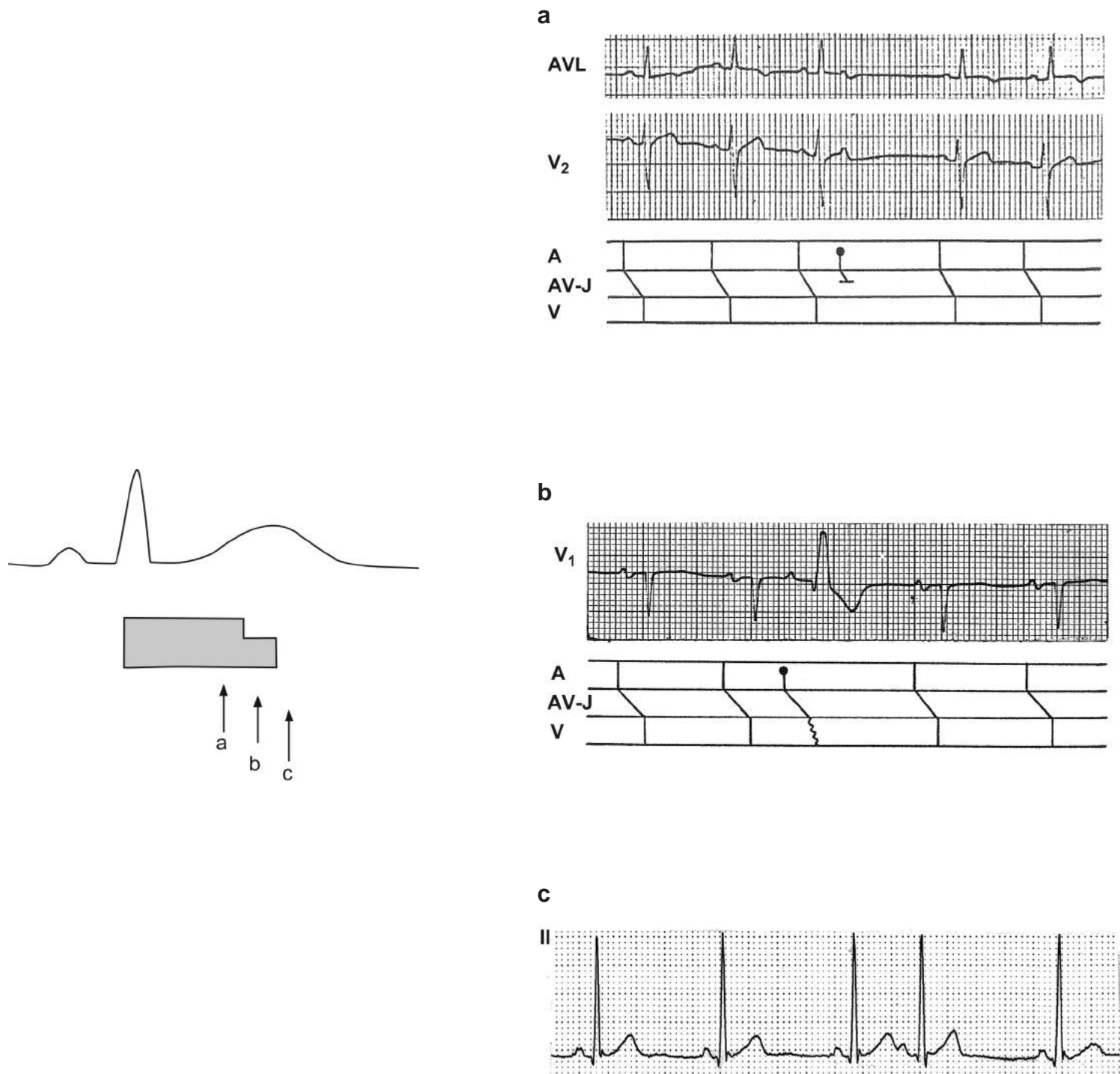


Accelerated idioventricular rhythm with AV dissociation at times and 1:1 retrograde VA conduction at other times and one capture beat, all in one tracing as diagrammed.





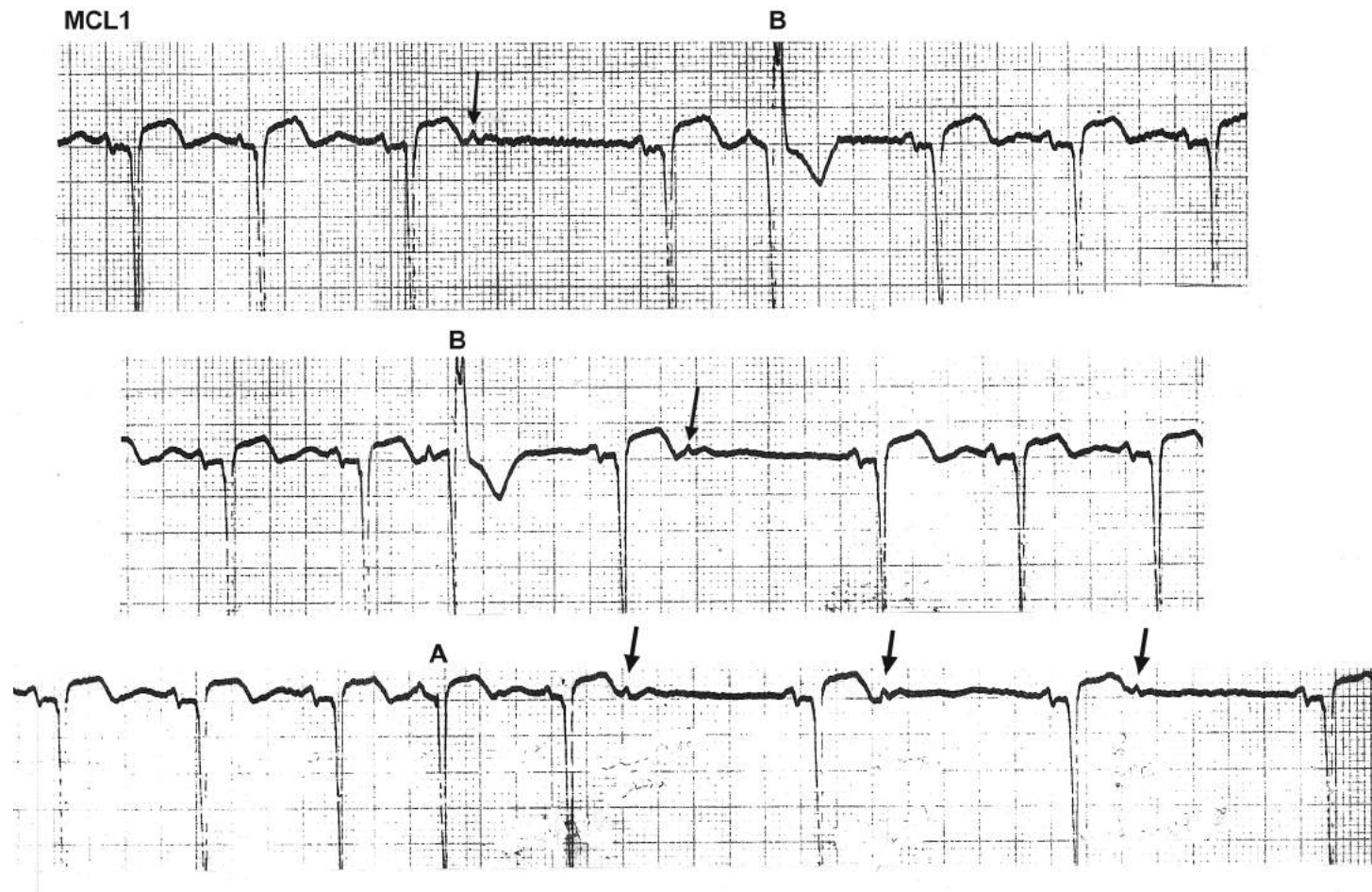
## Atrial Premature Beats



Every QRS is followed by a refractory period and the shaded area in the above drawing depicts that refractory period. As depicted, part of the intraventricular conduction system (e.g. one bundle branch) has a longer refractory period and the other part (e.g. the other bundle branch) has a shorter refractory period. If an atrial premature impulse occurs at **point c** when the whole intraventricular conduction system has recovered from the refractory period, it will be conducted normally (tracing c). If a premature atrial impulse occurs at **point a** when the AV node or intraventricular conduction system is refractory, the impulse will not be conducted to the ventricles resulting in a non-conducted APB (tracing a). If a premature atrial impulse occurs at **point b** when one bundle branch is still refractory and the other bundle branch has recovered from the refractory period, the impulse will conduct thru the recovered bundle branch bypassing the refractory bundle branch, resulting in a differently (aberrantly) conducted QRS (tracing b). Thus, aberrant conduction results simply because two bundle branches have different length of refractory period.

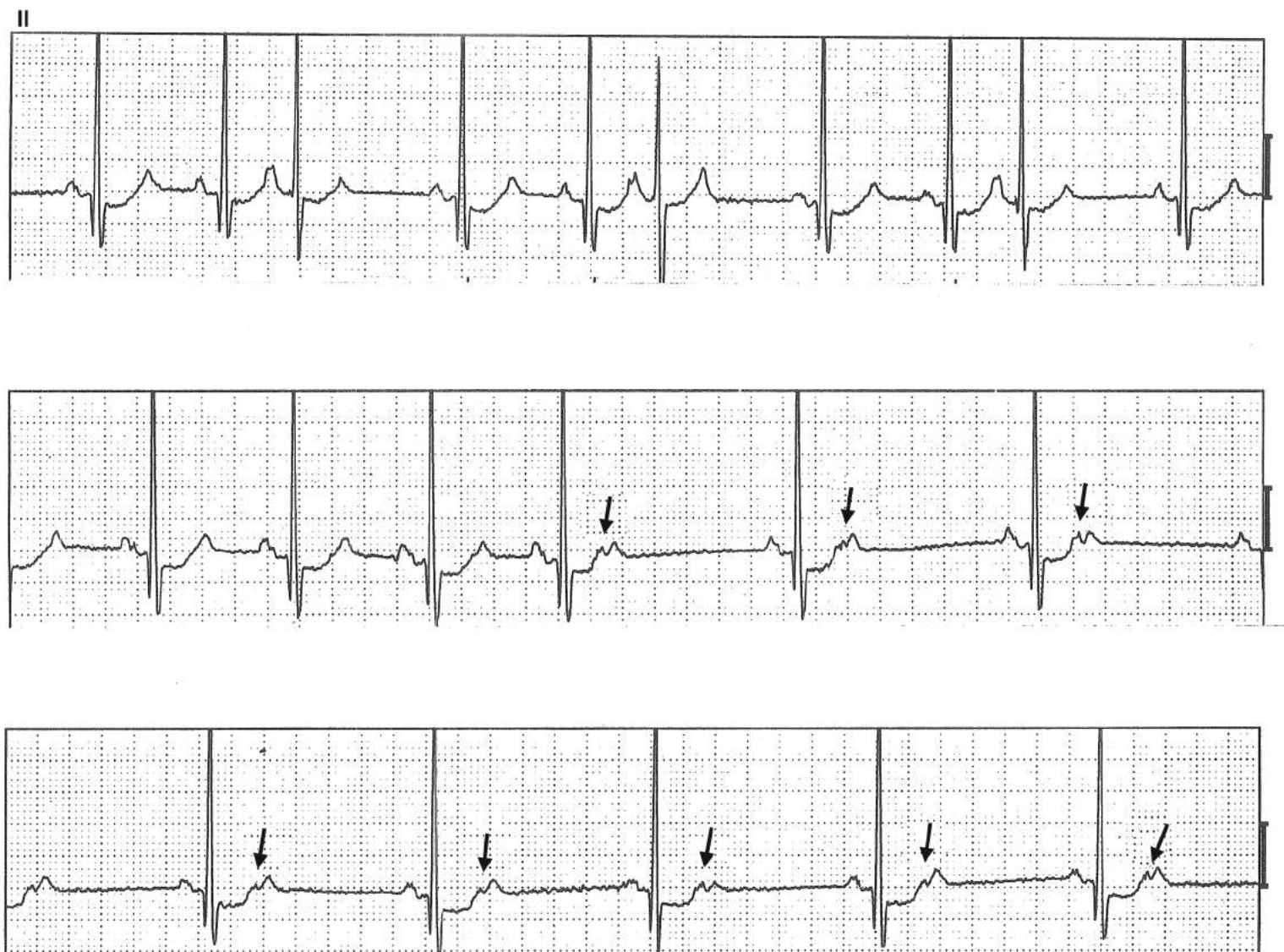

## Various Manifestations of PACs



The tracings contain frequent APBs. One of them is normally conducted (A), two are aberrantly conducted (B), and some are not conducted to the ventricle at all (↓), resulting in pauses.

## Various Manifestations of PACs

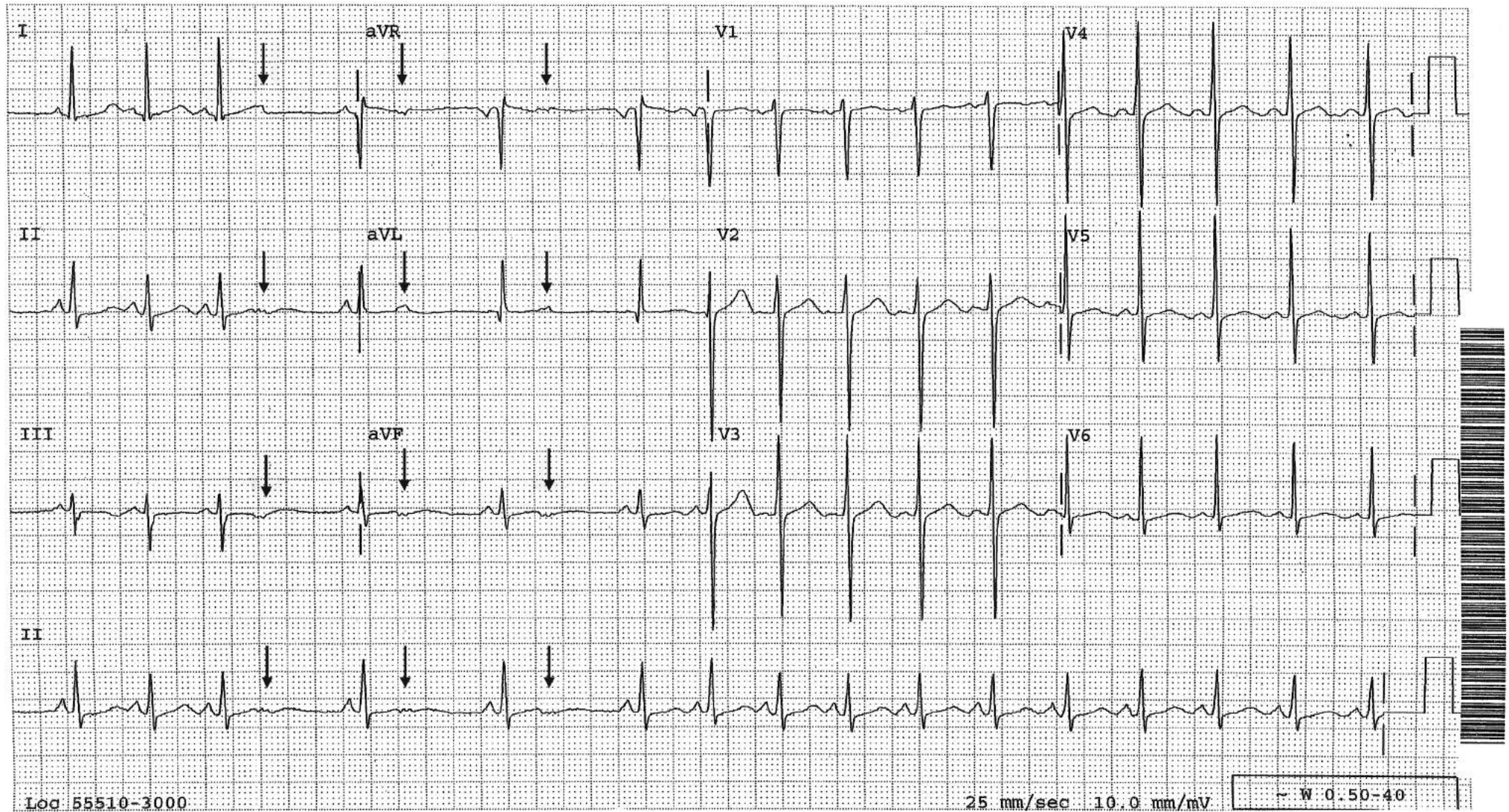


Frequent PACs are present in the upper tracing. Non-conducted atrial bigeminy ( $\downarrow$ ) causes pauses, which simulate sinus node dysfunction (middle tracing) and sinus bradycardia (lower tracing).



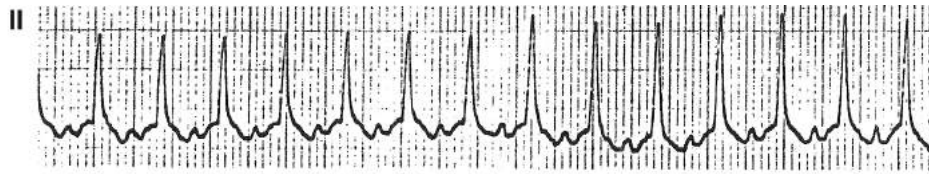
## Non-Conducted Atrial Bigeminy Simulating Sinus Node Reentrant Tachycardia or 2:1 SA Block

The rate changes suddenly with a P wave of the same morphology in front of each QRS complex, suggesting sinus node re-entrant tachycardia. But then, the longer cycle is exactly two shorter cycle lengths, suggesting 2:1 SA block. However, on careful examination of the longer cycles, there is a P wave (↓) after the QRS complex that occurs prematurely and is blocked; hence, a brief episode of non-conducted atrial bigeminy.

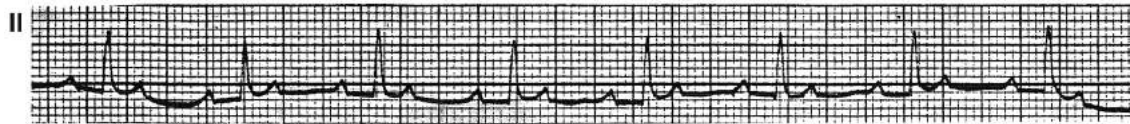




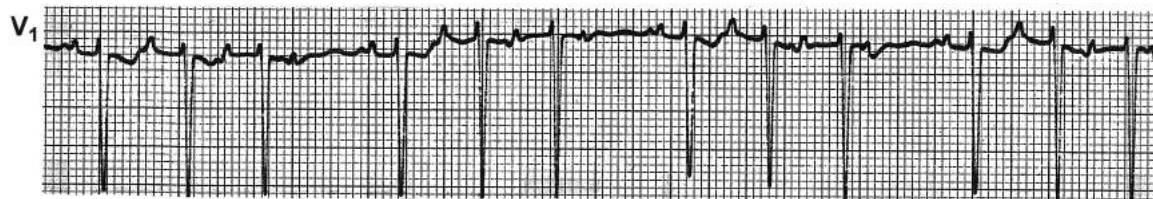
## Atrial Tachycardia



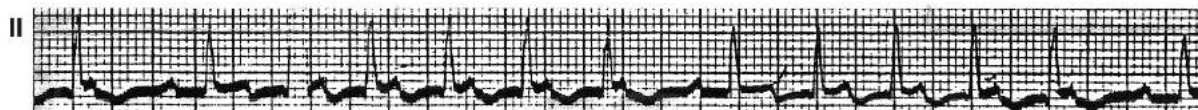
PAT with 1:1 AV conduction. Positive P waves are readily recognizable.



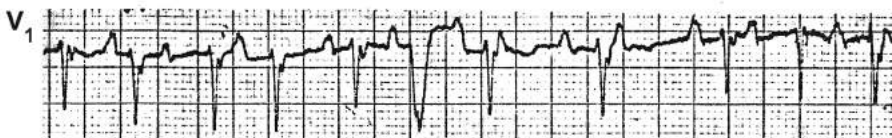PAT with 2:1 AV conduction.



PAT with Wenckebach phenomenon.

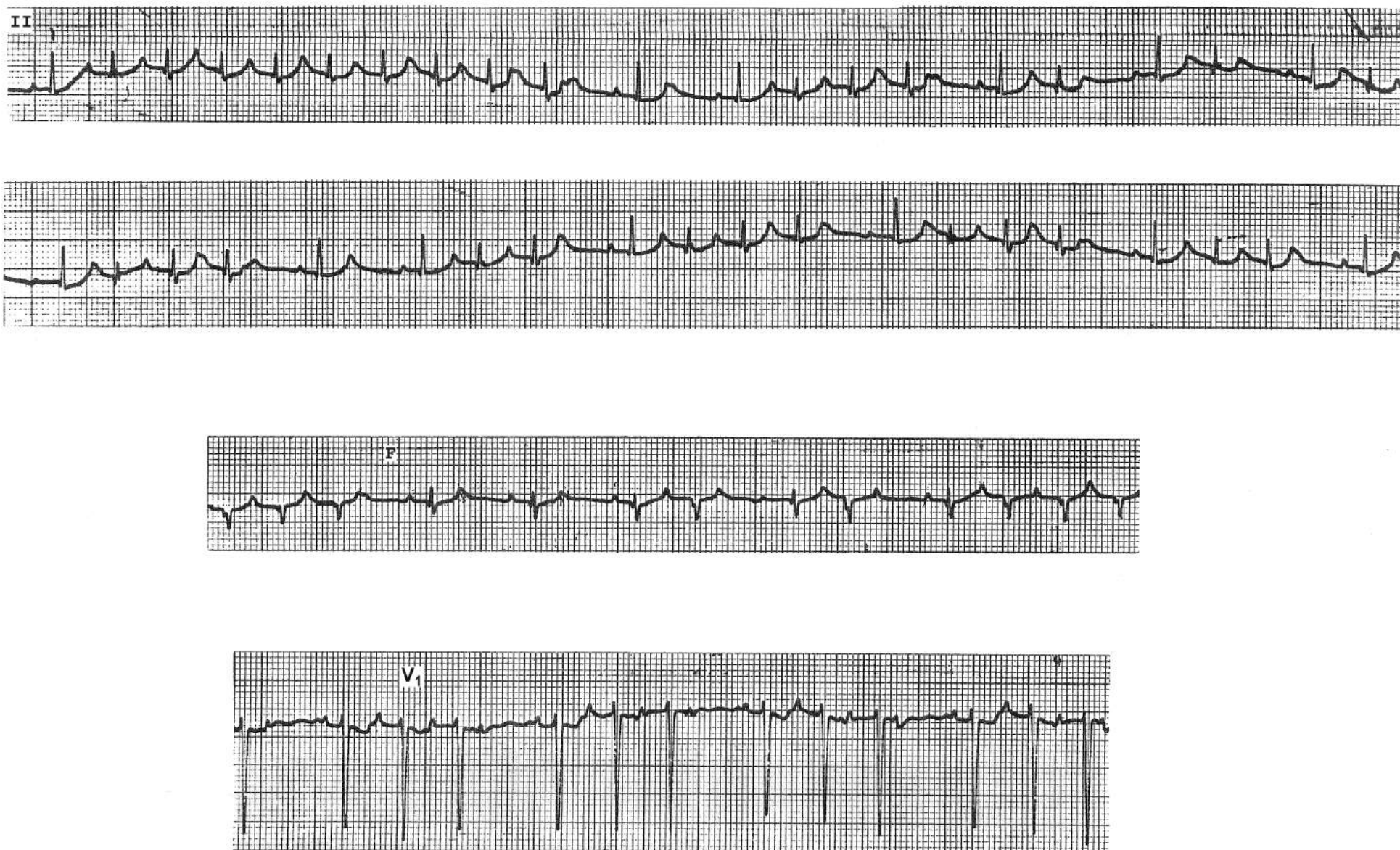

PAT with Wenckebach phenomenon.



Multifocal atrial tachycardia. Note irregularly irregular PP intervals and changing P wave morphology.

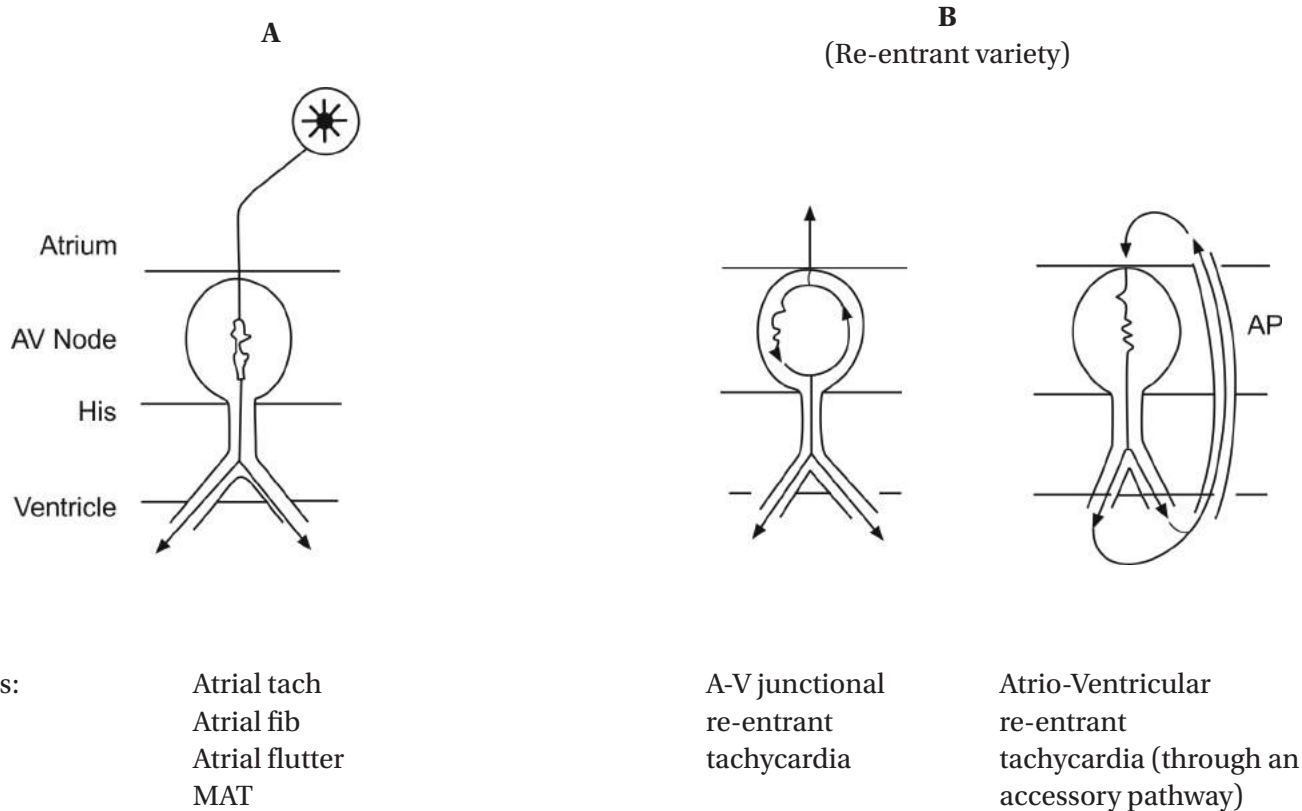
## PAT with Wenckebach Phenomenon



The distinction between PAT and MAT is that if the PP intervals are regular, it is PAT and if they are irregular, it is MAT. This tracing is an example of PAT with AV Wenckebach phenomenon.



## Role of the A-V Node in Various Supraventricular Arrhythmias and Its Implication in Their Treatment



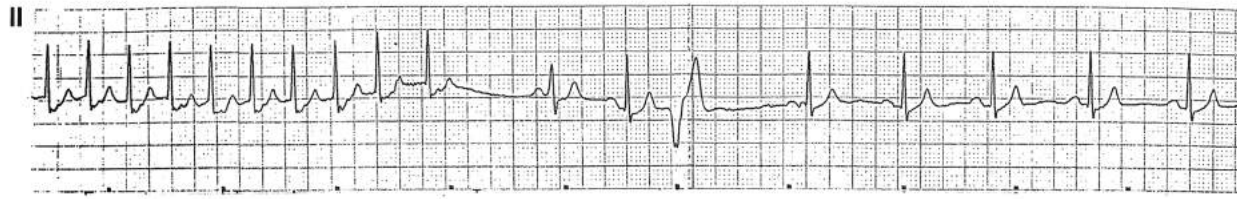Role of the A-V node: to transmit impulse to the ventricles

to compose the re-entry circuit entirely or partially

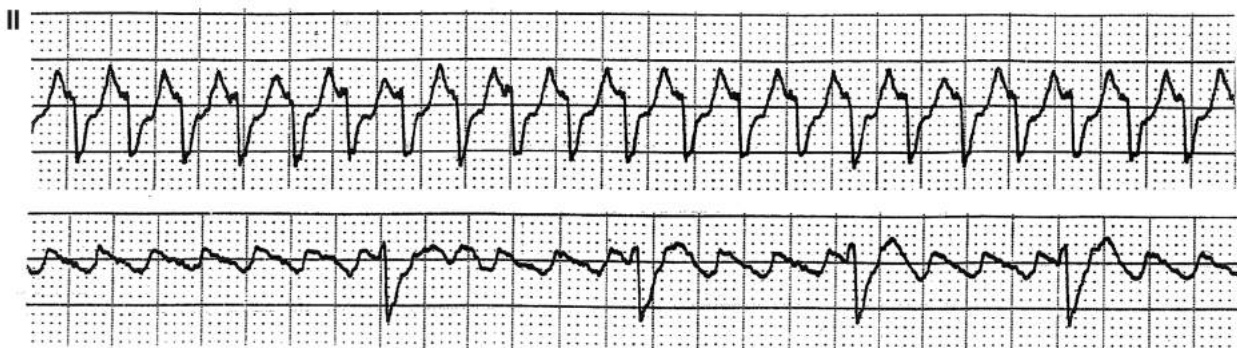
- A-V blocking maneuvers or drugs (e.g. digitalis,  $Ca^{++}$  channel blockers, B-blockers, adenosine) can interrupt the re-entry circuit and terminate the rhythms in B. They do not, however, convert the rhythms in A; rather, they will slow down the ventricular rate of rhythms in A (except digitalis in MAT).
- Type Ia, Ic or III antiarrhythmic agents (procainamide, quinidine, disopyramide, flecainide, propafenone, sotalol, amiodarone, ibutilide) can convert the rhythms in A (except MAT) to NSR.
- Some atrial tachycardias are due to atrial re-entry and behave like the rhythms in B.



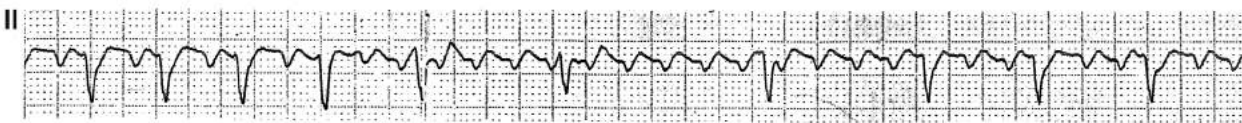
## Effects of Adenosine in Various Supraventricular Tachyarrhythmias



This narrow complex tachycardia at a rate of 160/minute is effectively terminated with adenosine given intravenously. This proves that the rhythm is a reentrant variety (either atrioventricular reentrant tachycardia utilizing an accessory pathway or AV nodal reentrant tachycardia). Adenosine in this case is diagnostic as well as therapeutic.



Narrow complex regular tachycardia at a rate of 240/min is present in the upper strip. With adenosine, the ventricular rate slows and atrial flutter at a rate of 240/minute is effectively revealed. This proves that the rhythm in the upper strip is atrial flutter with 1:1 AV conduction. Even though adenosine does not convert atrial flutter to sinus rhythm, it is useful in revealing the underlying atrial rhythm by inducing more AV block.

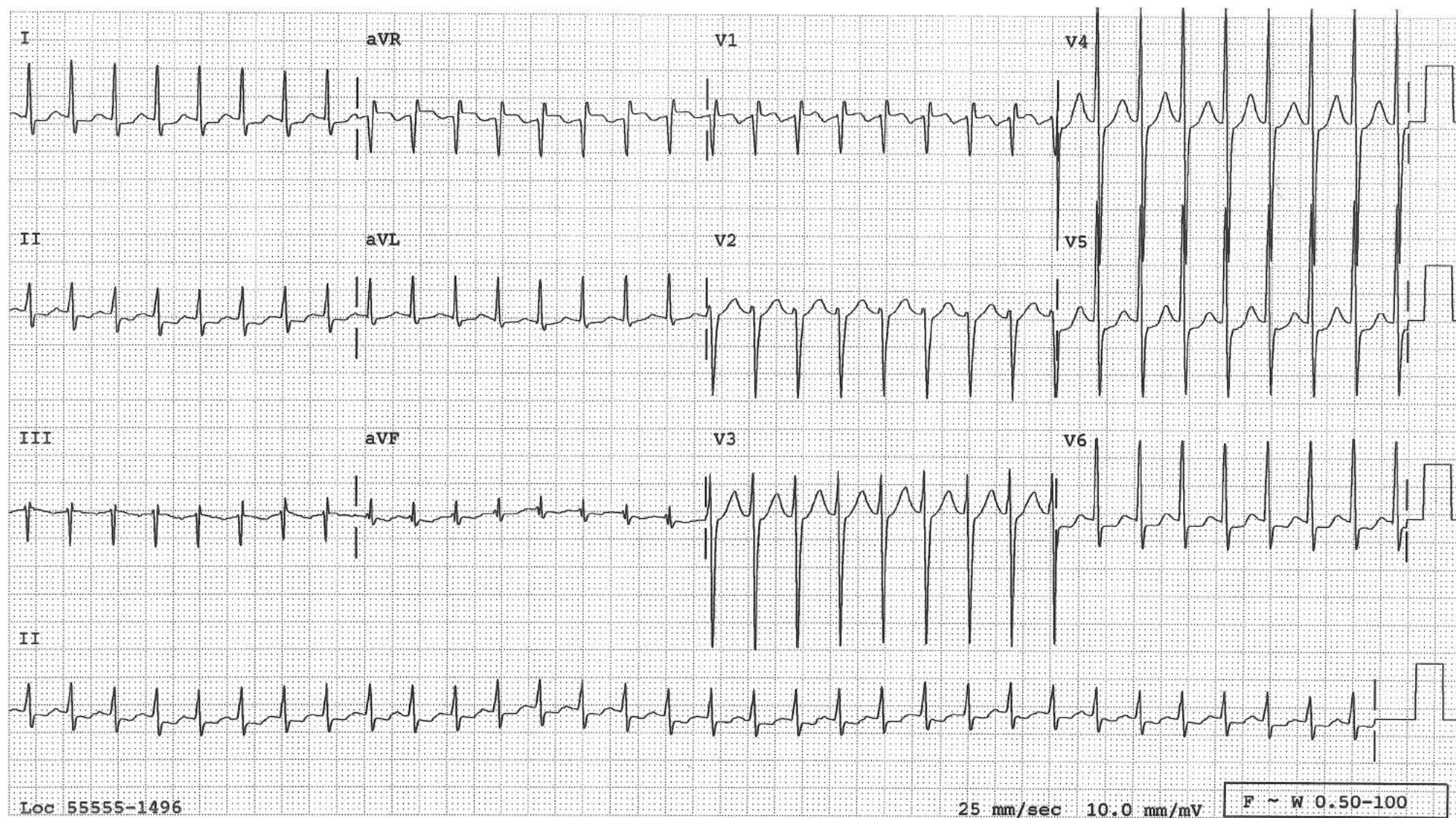


Narrow complex regular tachycardia at a rate of 130/min is present at the beginning of the strip. In the latter part of the strip, adenosine induces more AV block, effectively revealing atrial flutter waves and proving that the rhythm in the initial portion of the strip is atrial flutter with 2:1 AV conduction.



## Supraventricular Tachycardia (SVT)

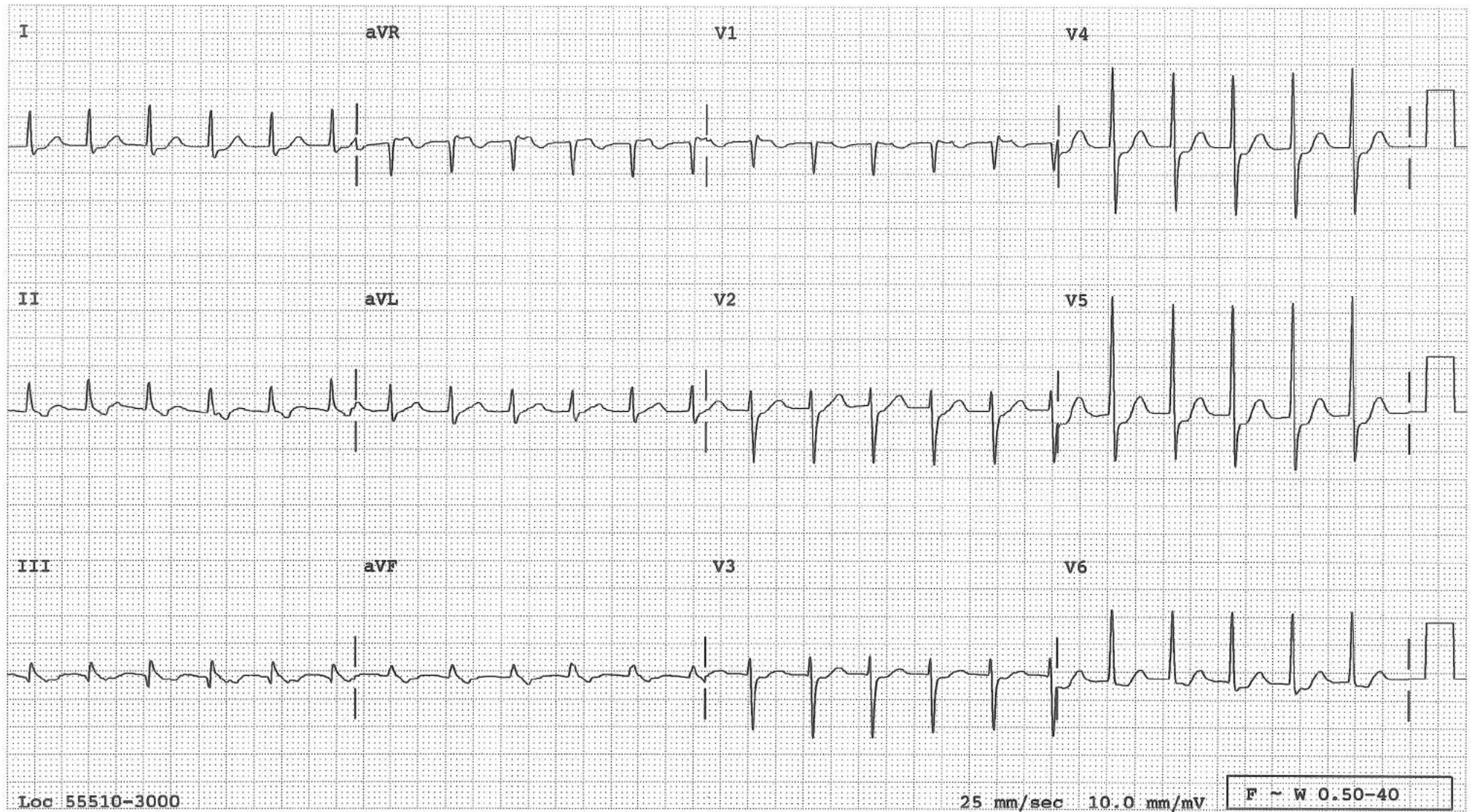
This tracing displays a narrow QRS tachycardia with no recognizable P-waves since they occur within the QRS. This tracing is taken from a patient with WPW syndrome during orthodromic re-entrant tachycardia, i.e. anterograde conduction through the AV node and retrograde conduction to the atria through the accessory pathway. That is why the QRSs are narrow without delta waves.





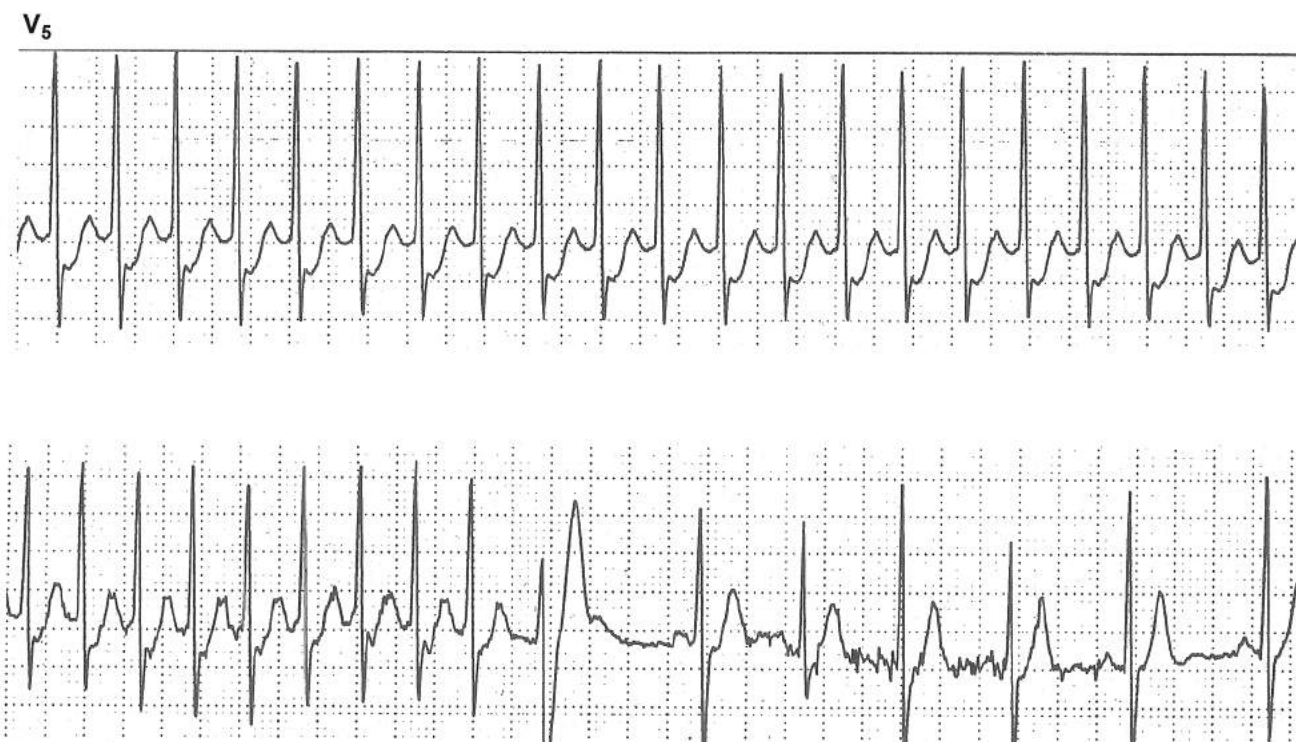## SVT

This tracing displays a narrow QRS tachycardia at a rate of 138/minute. In the inferior leads, the QRS is followed by a negative blip, most likely reflecting a retrograde P wave. This suggests either AV junctional re-entrant tachycardia, atrio-ventricular re-entrant tachycardia using an accessory pathway, or AV junctional tachycardia with 1:1 retrograde conduction to the atria.





## ST Depression During SVT

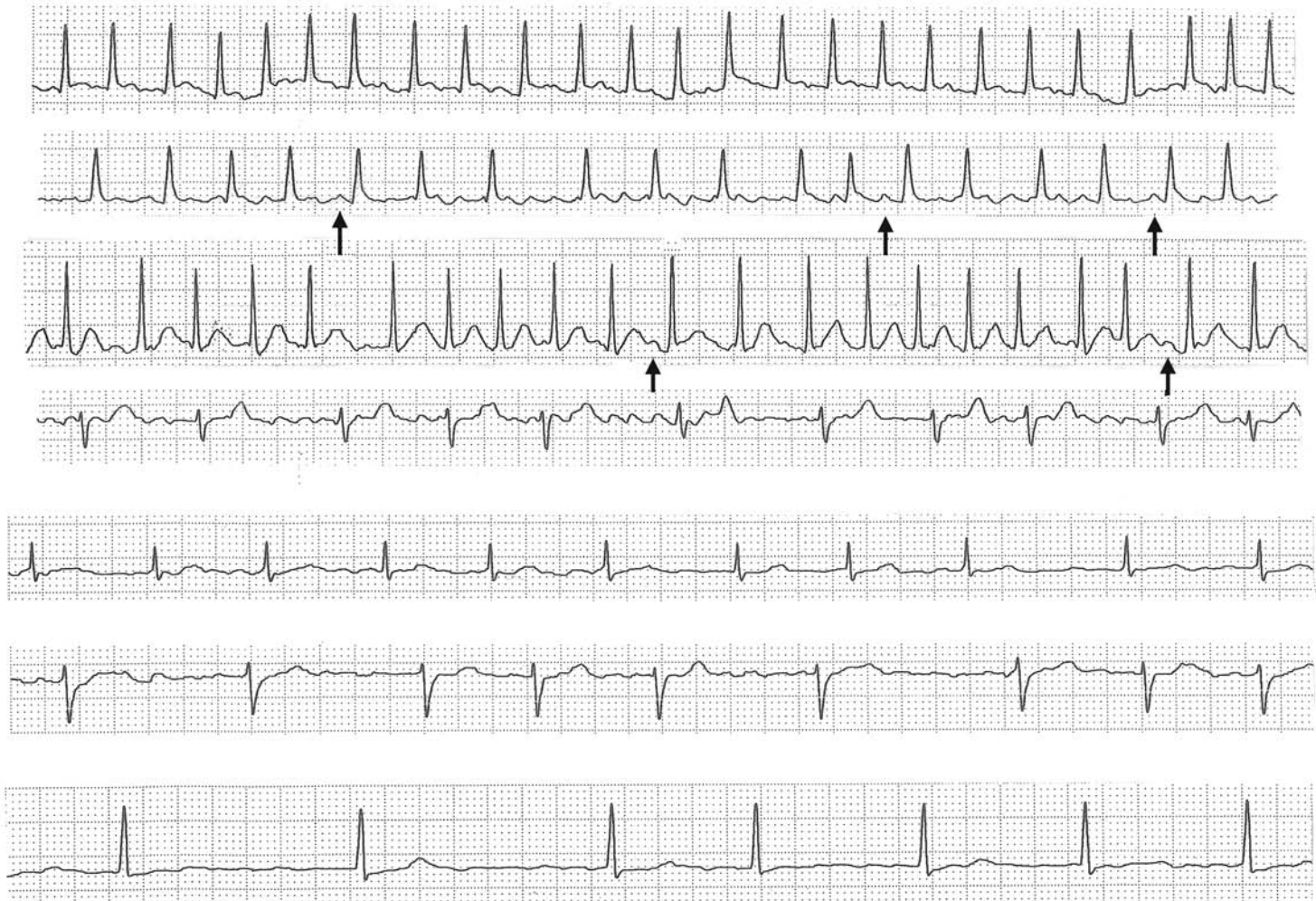


Marked horizontal ST depression is present during SVT. Tachycardia may cause myocardial ischemia, resulting in ST depression, but SVT without myocardial ischemia can also cause ST depression. Given the fact that the very first QRS after conversion to NSR reveals no ST depression, the ST depression in this case is not due to myocardial ischemia. Myocardial ischemia can not come and go from one beat to the next.

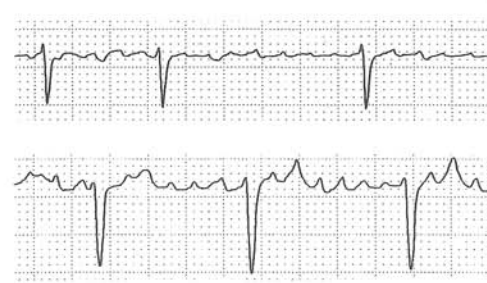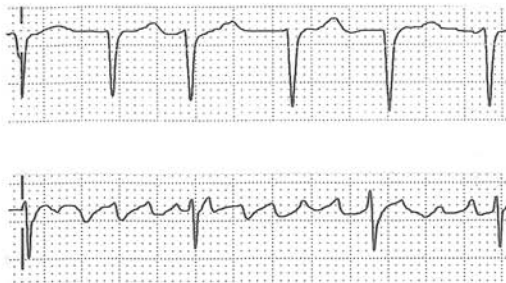## Atrial Fibrillation

Atrial fibrillation is an irregularly irregular atrial rhythm with no organized P waves. The impulse originates from a focus in the atrium, more often near one of the pulmonary veins, which is broken into multiple wavelets of electrical fronts, colliding with each other within the atria—fibrillation. The AV junction receives impulses from the adjacent atrial tissue at a rate 350-600/min. Due to the physiologic refractory period, the AV junction transmits only some of these impulses resulting in QRS complexes that occur irregularly at a rate ~ 140-180/min. Fibrillating atria cause small irregular baseline undulation of variable amplitude on ECG called fibrillatory (f) waves. These f waves are best seen in V1 and may be barely visible, “fine” or “course”. If a sizeable f wave occurs at just the right time in front of a QRS complex, it may simulate a sinus P wave (↑). If f waves have enough amplitude and occur reasonably regularly but not quite like well-organized flutter waves, the rhythm can be called flutter-fibrillation. Examples of atrial fibrillation from different patients are shown below.

II



V<sub>1</sub>

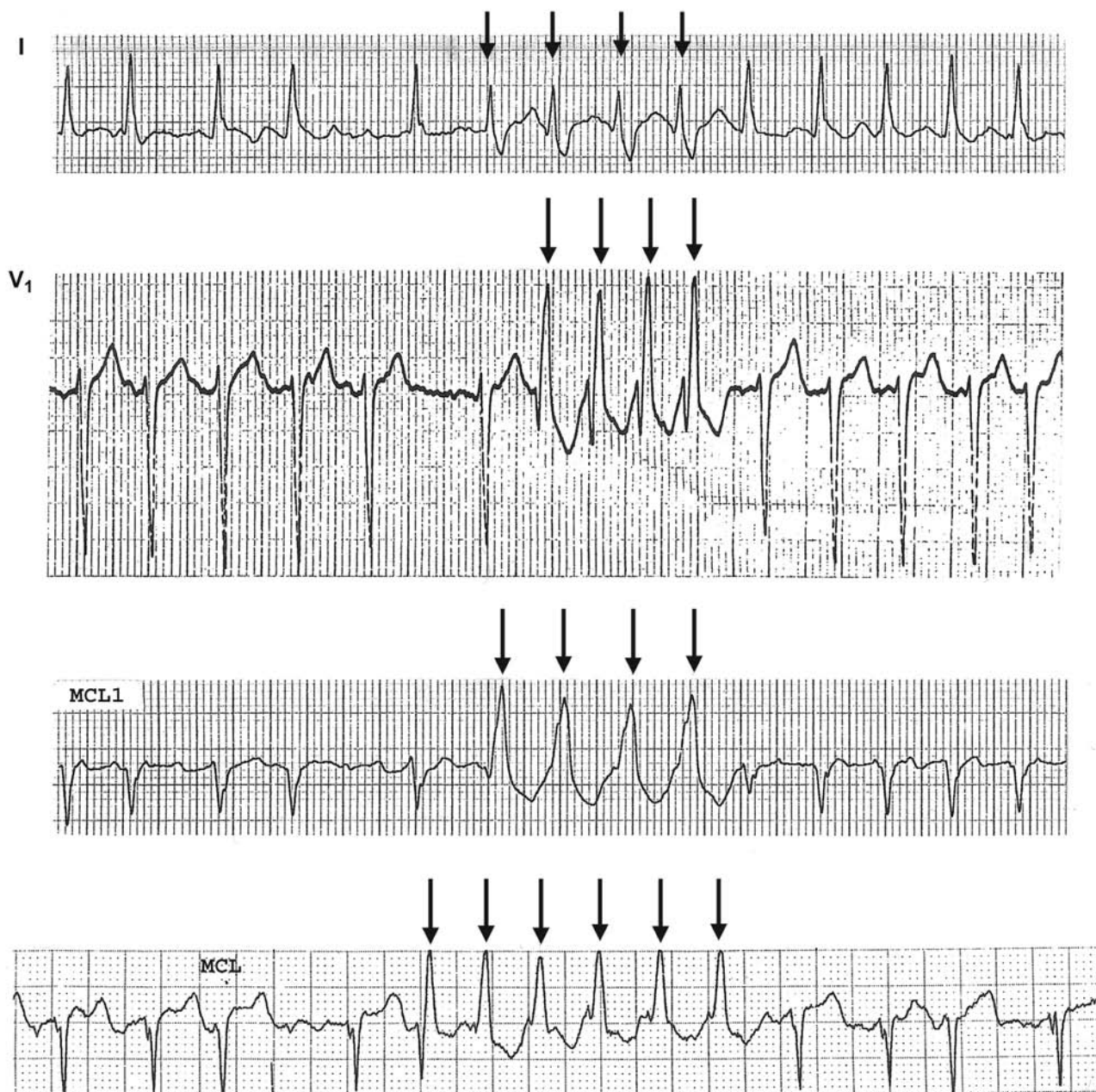




## Atrial Fibrillation and Aberrant Conduction

If an atrial impulse passes through the AV junction and reaches the ventricle when part of the intraventricular conduction system (often the left bundle branch) has recovered from the refractory period while another part (often the right bundle branch) is still refractory, the impulse will travel only through the part that has recovered, bypassing the part that is still refractory. This results in aberrant conduction (↓) which is more likely to happen if the impulse occurs following a longer preceding R-R interval (Ashman's phenomenon), since the length of the refractory period is proportionally related to the preceding R-R interval.

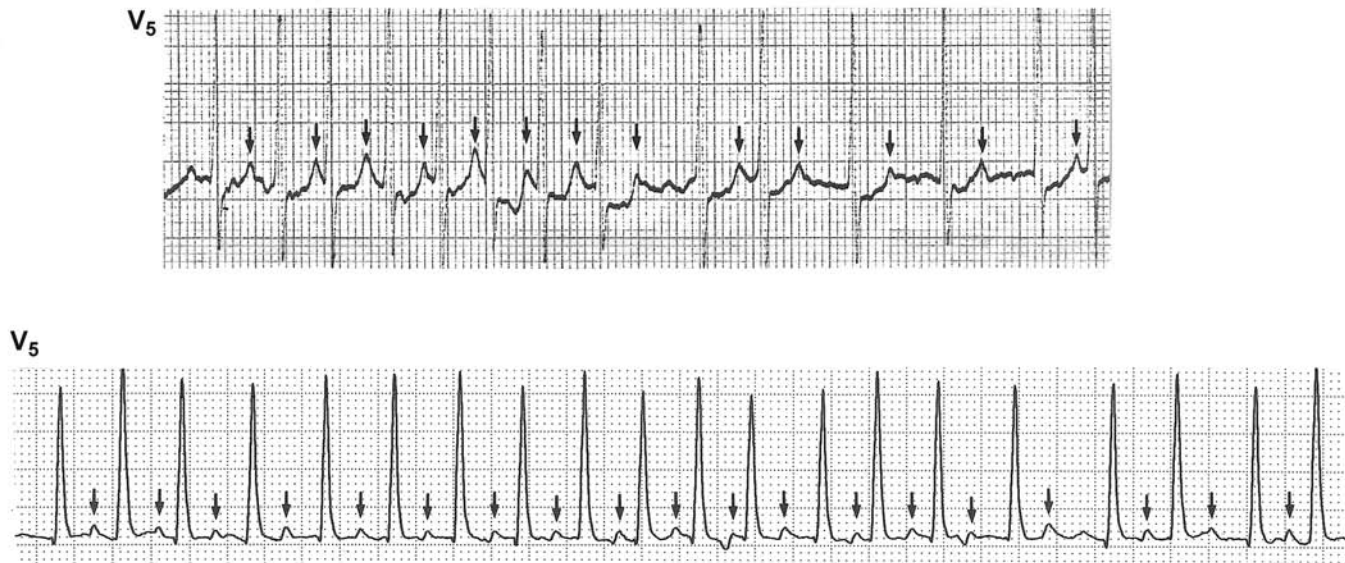
If there are runs of these aberrantly conducted complexes, the tracing can appear to show runs of ventricular tachycardia. At times, it is virtually impossible to differentiate them.



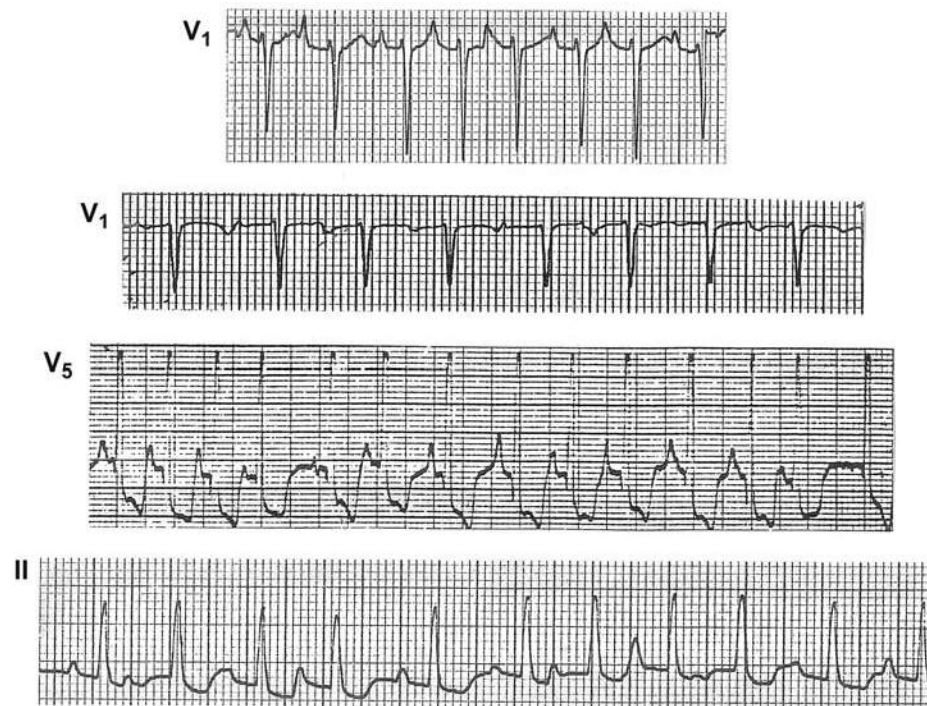


## Atrial Fibrillation Simulating Multifocal Atrial Tachycardia

During atrial fibrillation, if T waves (↓) are pointed, they may simulate P waves, and the tracing can be mistaken for multifocal atrial tachycardia. Note that these blips maintain a fixed relationship to the *preceding* QRS, not to the following QRS. Conversely, MAT may simulate atrial fibrillation if the P waves are inconspicuous in certain leads. Note that both rhythms are irregularly irregular.

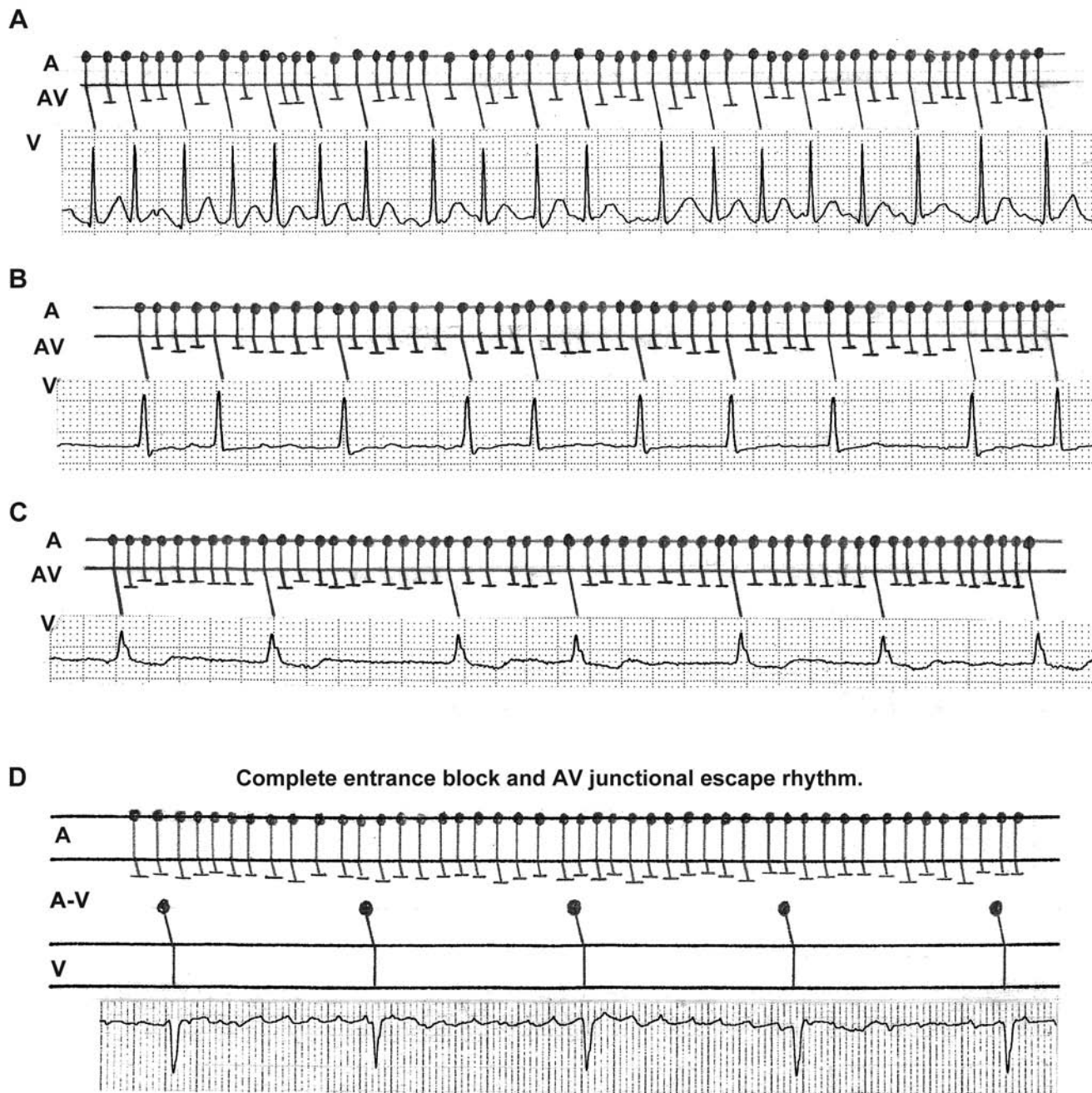


Examples of MAT for comparison. The blips (P waves) do not maintain a fixed relationship to the preceding QRS.



## AV Conduction During Atrial Fibrillation

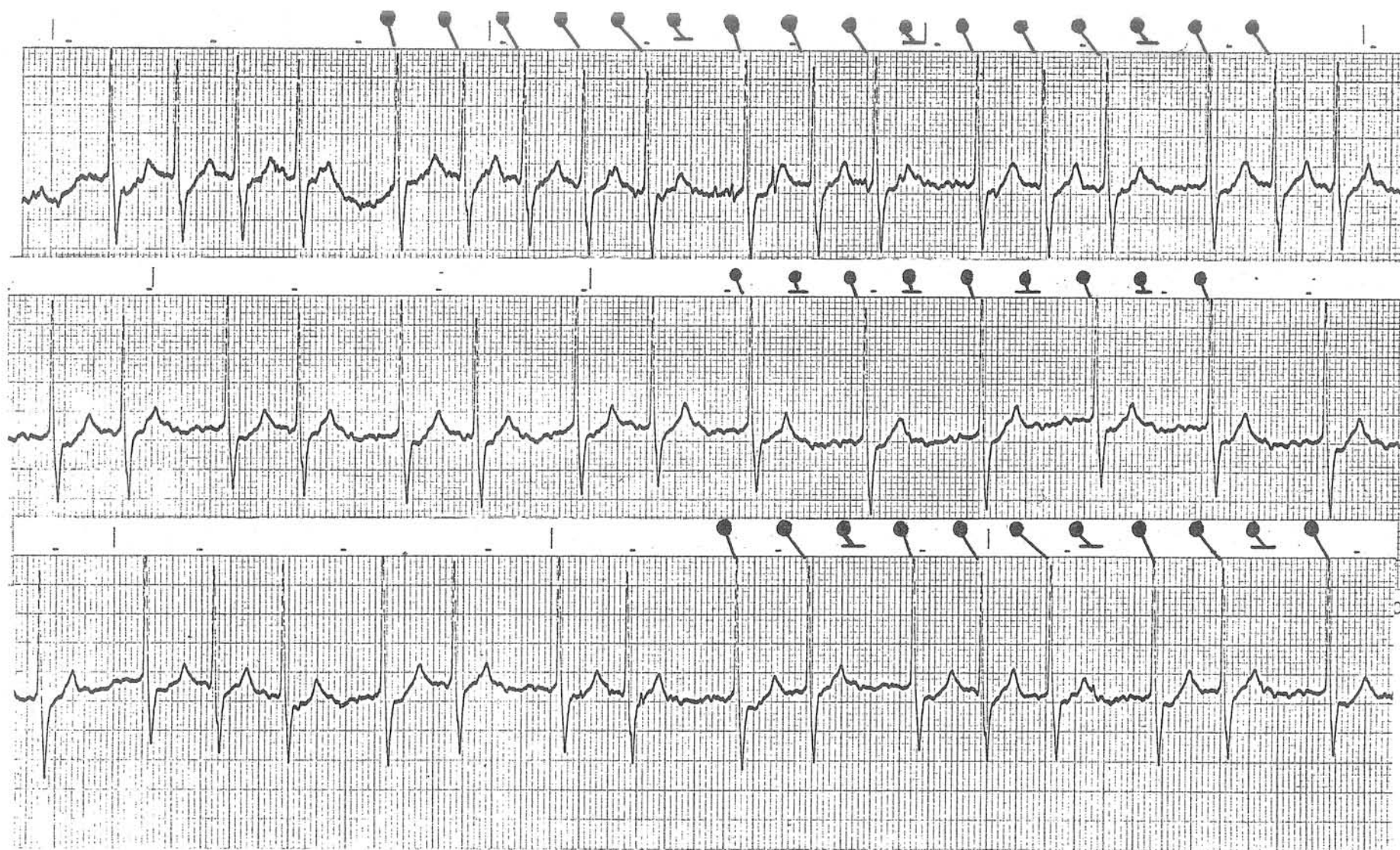
In atrial fibrillation, the atria do not undergo an organized depolarization but many wavelets of electrical fronts collide with each other within the atria. The AV junction receives impulses from the adjacent atrial tissue at a rate of approximately 400/min. Due to the physiologic refractory period, the AV junction can transmit only some of these impulses, resulting in QRSs that occur irregularly at a rate of approximately 140-180/min (tracing A). AV blocking agents or the patient's own vagal tone can cause more AV block and the ventricular rate slows down (tracings B and C). With too much AV block, none of the atrial impulses enter the AV junction (complete entrance block) and AV junctional escape rhythm takes over (tracing D). (Note that the narrow QRSs occur regularly at a slower rate). If this is induced by digitalis, and if the serum digitalis level rises further, the next step in digitalis intoxication is AV junctional acceleration and exit block. (See the case on the next page).





## Atrial Fibrillation, Complete Entrance Block, Junctional Tachycardia and Exit Block

This patient is in atrial fibrillation. In the latter part of the middle strip, the QRSs occur regularly, which is highly unusual for atrial fibrillation. In other parts of the tracing, there are group beatings or a bigeminal rhythm which again are unusual during atrial fibrillation. What is happening in this patient is shown below in the diagram. The patient is in complete entrance block (no atrial impulse is getting into the AV junction) and the ventricle is driven by AV junctional tachycardia at a rate of about 150/minute. This impulse from the AV junction is conducted to the ventricles with Wenckebach periodicities of 6:5, 4:3, 3:2, or 2:1 conduction ratios (exit block). This tracing is strongly indicative of digitalis intoxication inducing complete entrance block to the AV junction, acceleration of the AV junctional pacemaker, and exit block from this AV junction.

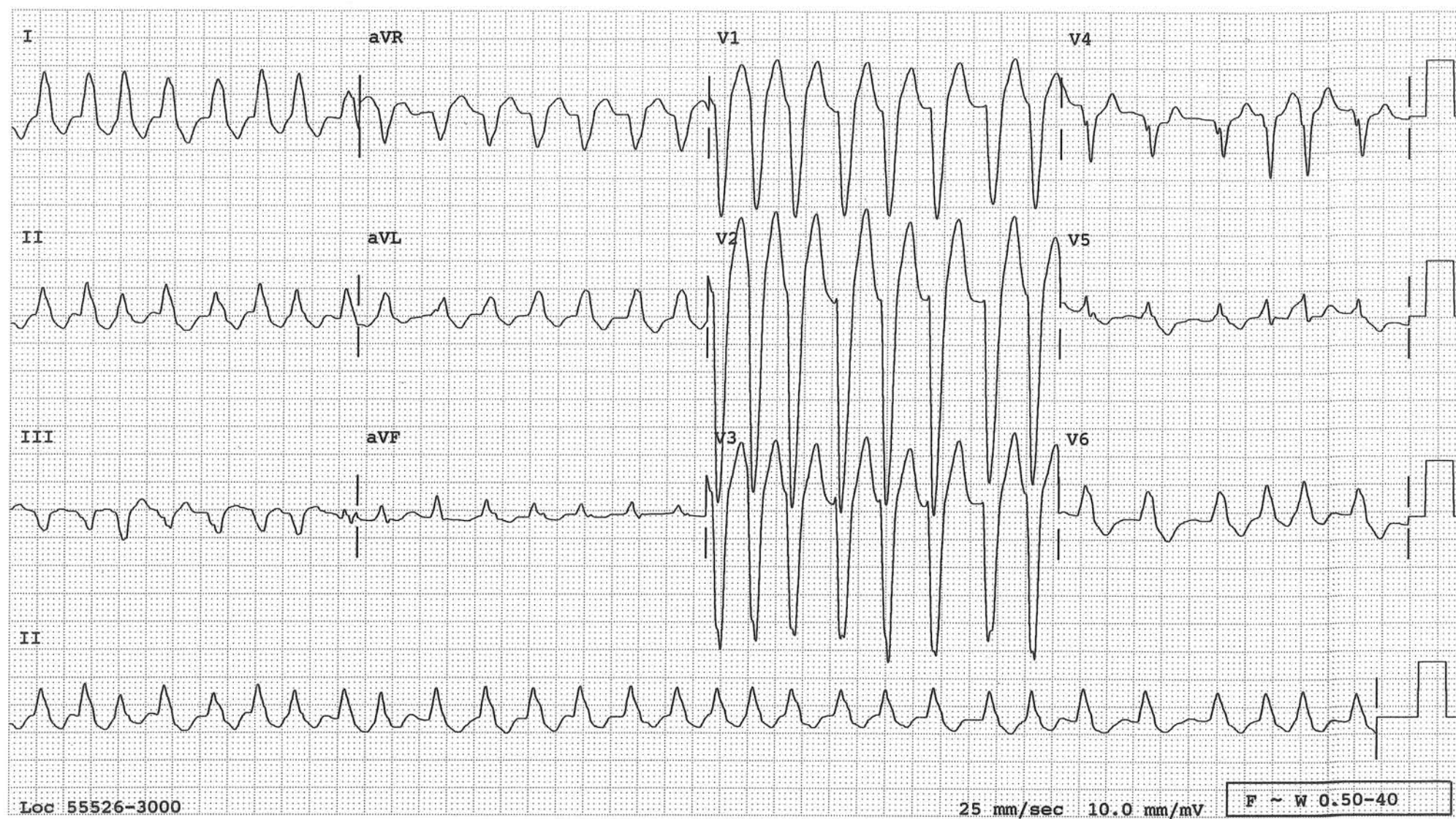


hp HEWLETT-PACKARD 9270-0544



## Atrial Fibrillation in a Patient with LBBB

This tracing is taken from a patient with known LBBB, who developed atrial fibrillation. Such a tracing can be mistaken for ventricular tachycardia. Comparison with an old tracing is useful in this situation. This degree of irregularity favors atrial fibrillation, though ventricular tachycardia is not always perfectly regular.





## Atrial Flutter

Atrial tachycardia with continuously and regularly undulating ECG baseline is called atrial flutter. It turns out that this is a macroreentrant atrial tachycardia. The circus movement of the electrical front, most often around the tricuspid annulus, is continuous without a pause which is the reason for the continuously and regularly undulating baseline without an isoelectric interval in-between (flutter waves). This continuous undulation, which is the necessary and sufficient condition for the diagnosis of atrial flutter, manifests more often as the baseline regularly sloping up, then sloping down (sawtooth pattern) or less often as regularly occurring “domes”. In most cases of typical atrial flutter, the circus movement proceeds counterclockwise and the flutter (F) waves are seen primarily in inferior leads. In right precordial leads, especially in V1, there are discrete, normal appearing atrial deflections with an isoelectric interval in-between as in focal atrial or sinus tachycardia. If the circus movement proceeds clockwise, which happens rarely, these findings are reversed, i.e. discrete atrial deflection in inferior leads and continuous undulation in V1.

Ordinarily the atrial rate in atrial flutter is close to 300/min. But it can slow down to ~200/min easily with antiarrhythmics or if the right atrium is dilated. The physiologic refractory period of the AV junction is such that the AV junction cannot transmit 300 impulses per minute, but may be able to transmit every other impulse (2:1 AV conduction), resulting in a ventricular rate of ~150/min.

When the AV conduction ratio is 2:1, the F waves are not easily recognizable, making the diagnosis of atrial flutter difficult. That is when lead V1 becomes useful, which often reveals two discrete atrial deflections for each QRS complex. If these atrial deflections occur regularly at a rate of ~300/min, one can be assured that the F waves are present in the inferior leads whether they are recognized or not, because atrial rate of ~300/min occurs only in atrial flutter. The atrial rate in other supraventricular arrhythmias seldom exceeds ~250/min. If the atrial rate is slower, the rhythm is atrial flutter if the baseline continuously undulates in inferior leads. In other supraventricular rhythms, there are discrete atrial deflections with an isoelectric baseline in-between even in inferior leads. In V1, however, there are discrete P waves in either case. Thus, the diagnosis of atrial flutter is made either by regular atrial rhythm at a rate close to 300/min whether the F waves are identified or not, or by continuously undulating baseline regardless of the atrial rate. Other useful clues are: (1) “paralleling” of the slopes, i.e. the upslopes of the sawtooth pattern parallel with each other; so do the downslopes. (2) the peak to peak or the valley to valley of the F waves march out.

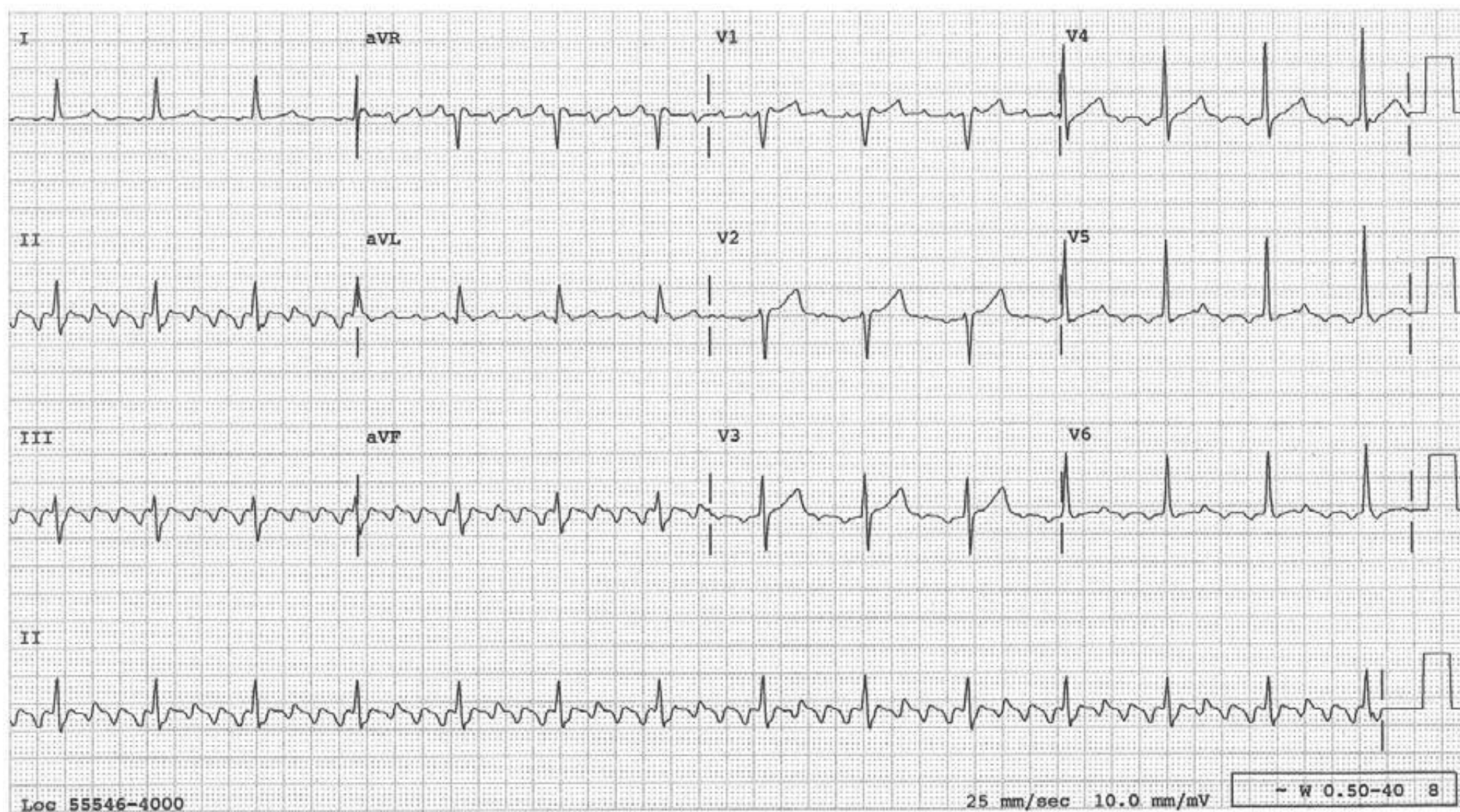
When one is still not certain of the diagnosis, AV blocking maneuvers or drugs can be used to induce more AV block and reveal the underlying atrial mechanism. If the maneuvers are not effective, adenosine is the drug of choice since it acts quickly and briefly. These maneuvers or drugs, however, do not convert atrial flutter. If one wants to convert the rhythm pharmacologically, ibutilide is the drug of choice.

In atrial flutter, the AV conduction ratio is usually fixed and the QRS complexes occur regularly. Occasionally, the conduction ratio varies resulting in an irregularly irregular rhythm, as in atrial fibrillation or multifocal atrial tachycardia. The AV conduction ratio can be an even or odd number.

The reentry circuit in typical atrial flutter traverses the inferior vena cava—tricuspid isthmus, which provides an easy target for radiofrequency catheter ablation. Since the advent of this ablation technique, it is now clinically more useful to classify atrial flutter into “isthmus dependent” and “non-isthmus dependent”.

## Atrial Flutter with 4:1 AV Conduction

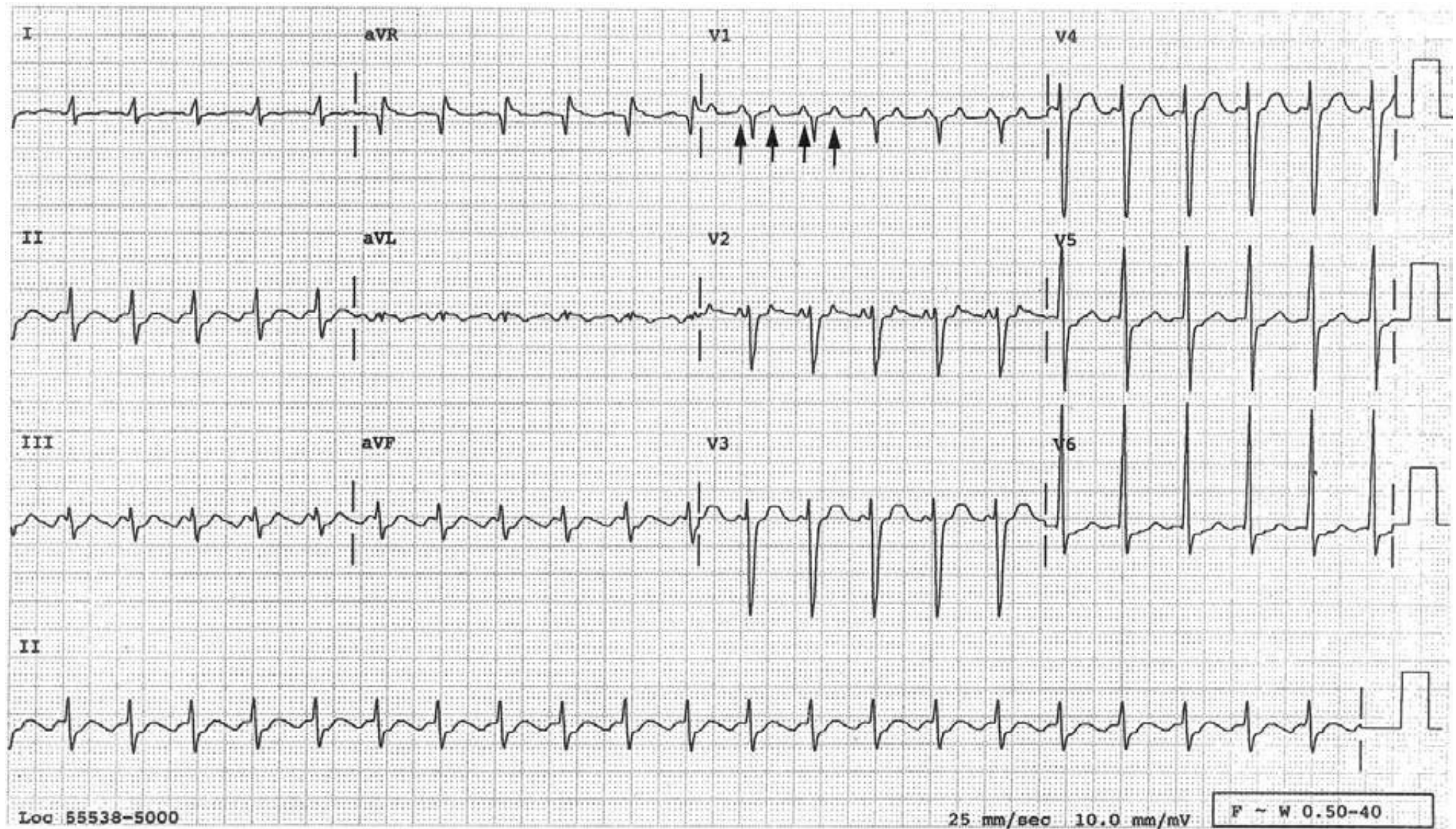
As a rule, the sawtooth pattern of flutter waves is primarily seen in the inferior leads. In V1, the atrial deflections are separated by an isoelectric baseline as in this case.





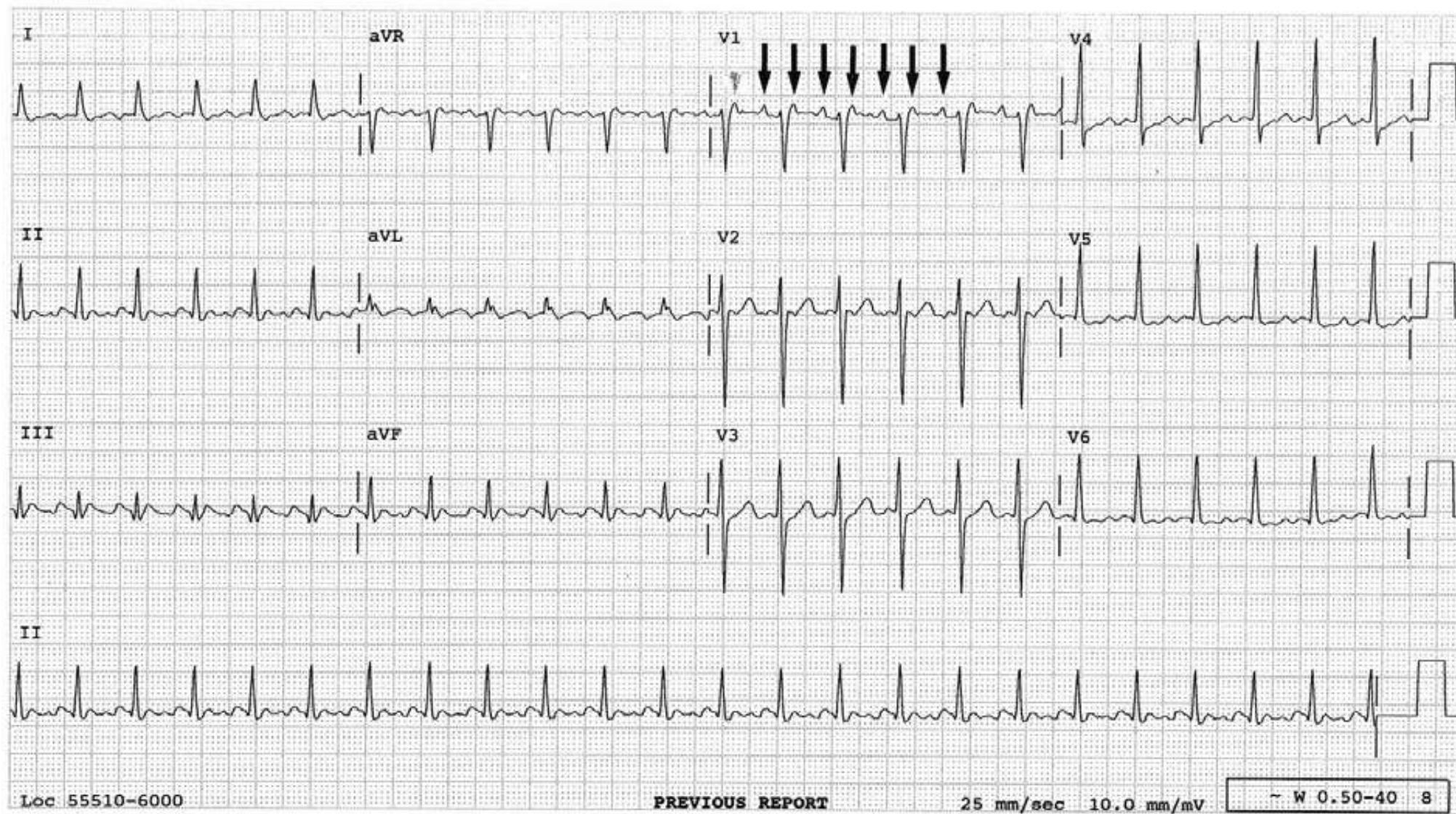
## Usefulness of $V_1$ in the Dx of Atrial Flutter

Even though it is not lead  $V_1$  which customarily reveals the “saw tooth” pattern, it can be extremely useful in revealing two atrial deflections for each QRS. When the atrial rate is right, that is anywhere from 180 to 350, one should look for the “saw tooth” pattern in the inferior leads and arrive at the correct diagnosis.



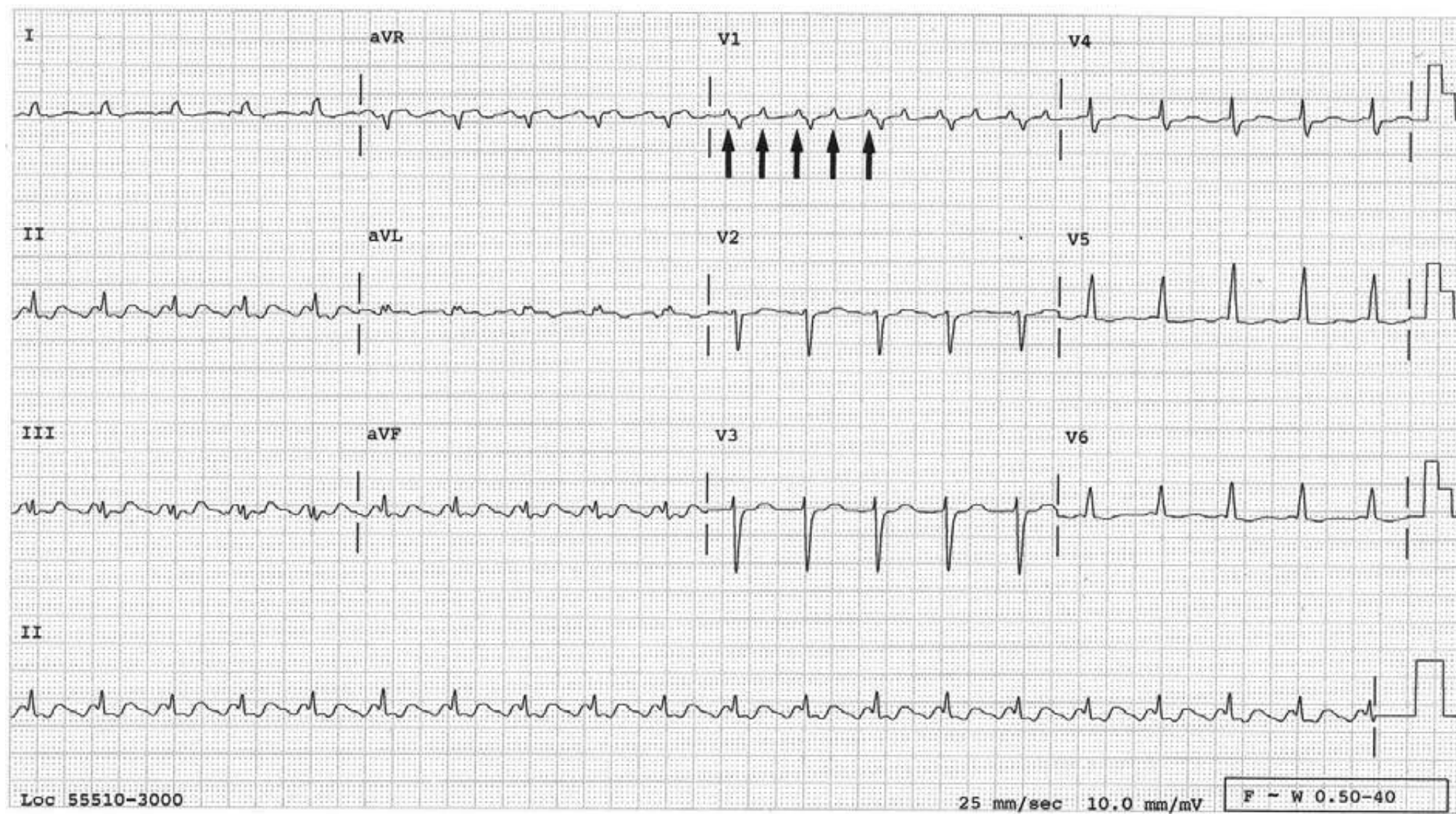


Two atrial activities (↓) between the QRSs in V1 help make the diagnosis of atrial flutter.



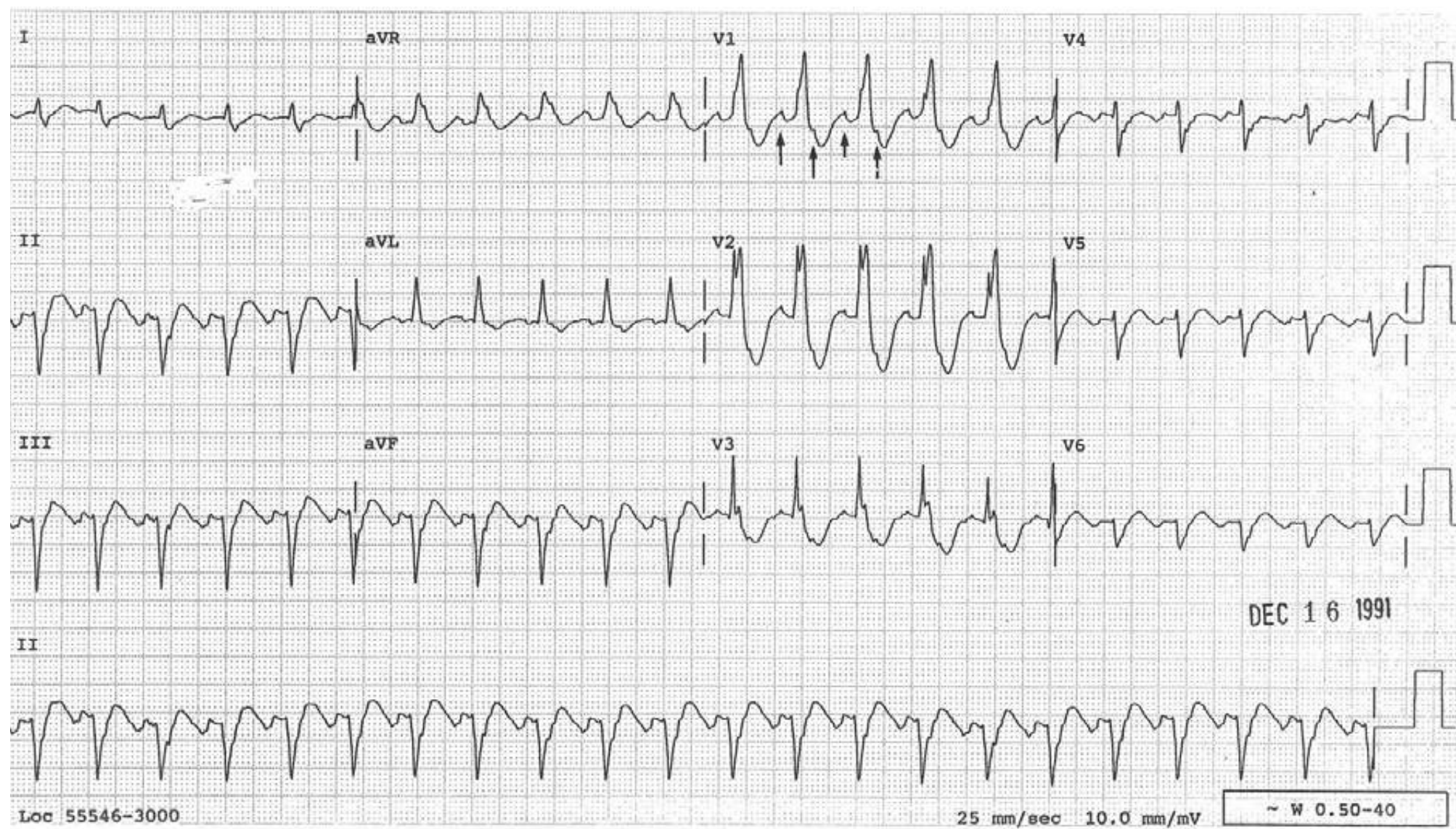


Two atrial activities ( $\uparrow$ ) between the QRSs in  $V_1$  help make the diagnosis of atrial flutter.



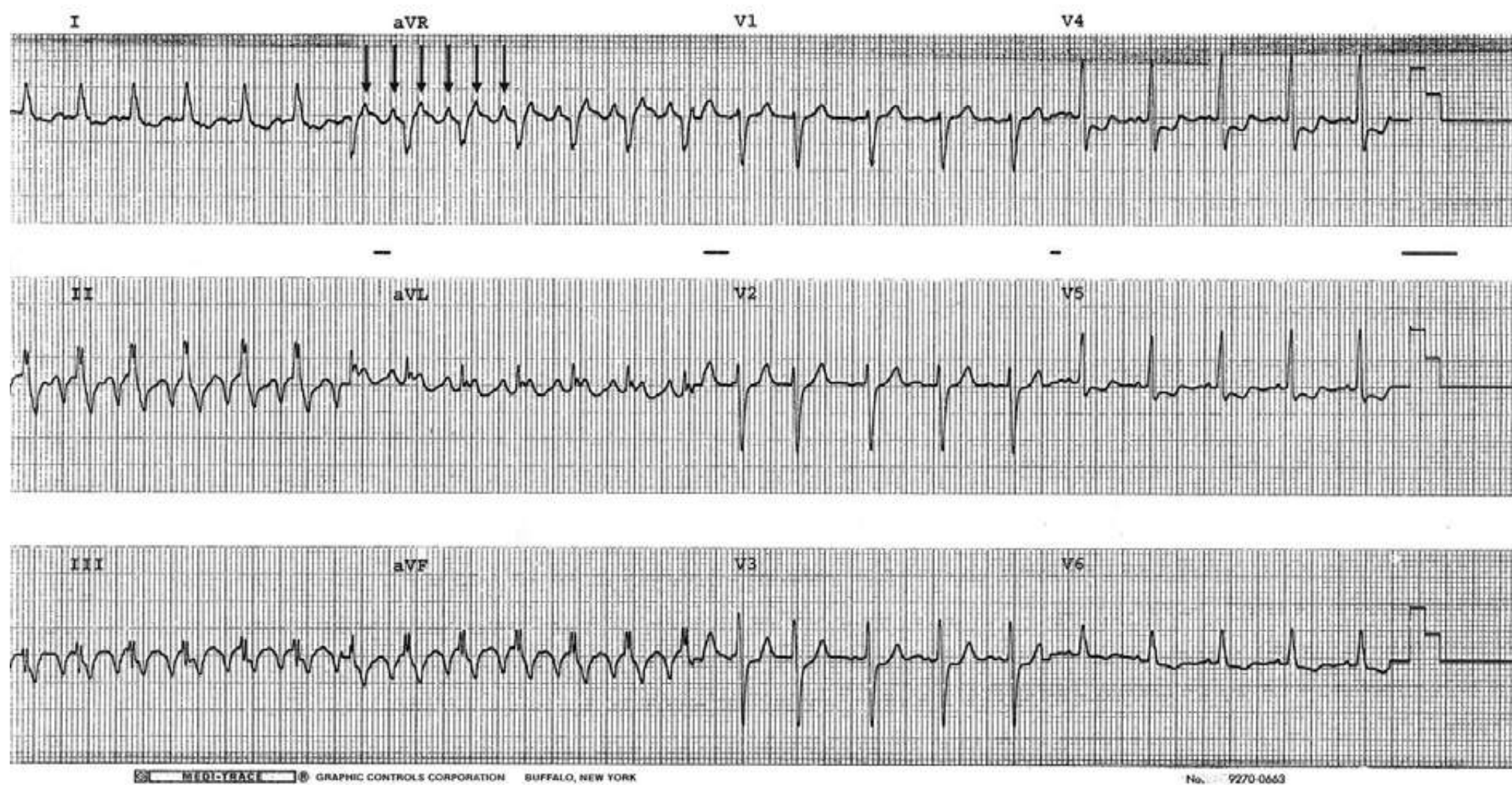


Two atrial activities ( $\uparrow$ ) between the QRSs in  $V_1$  help make the diagnosis of atrial flutter.



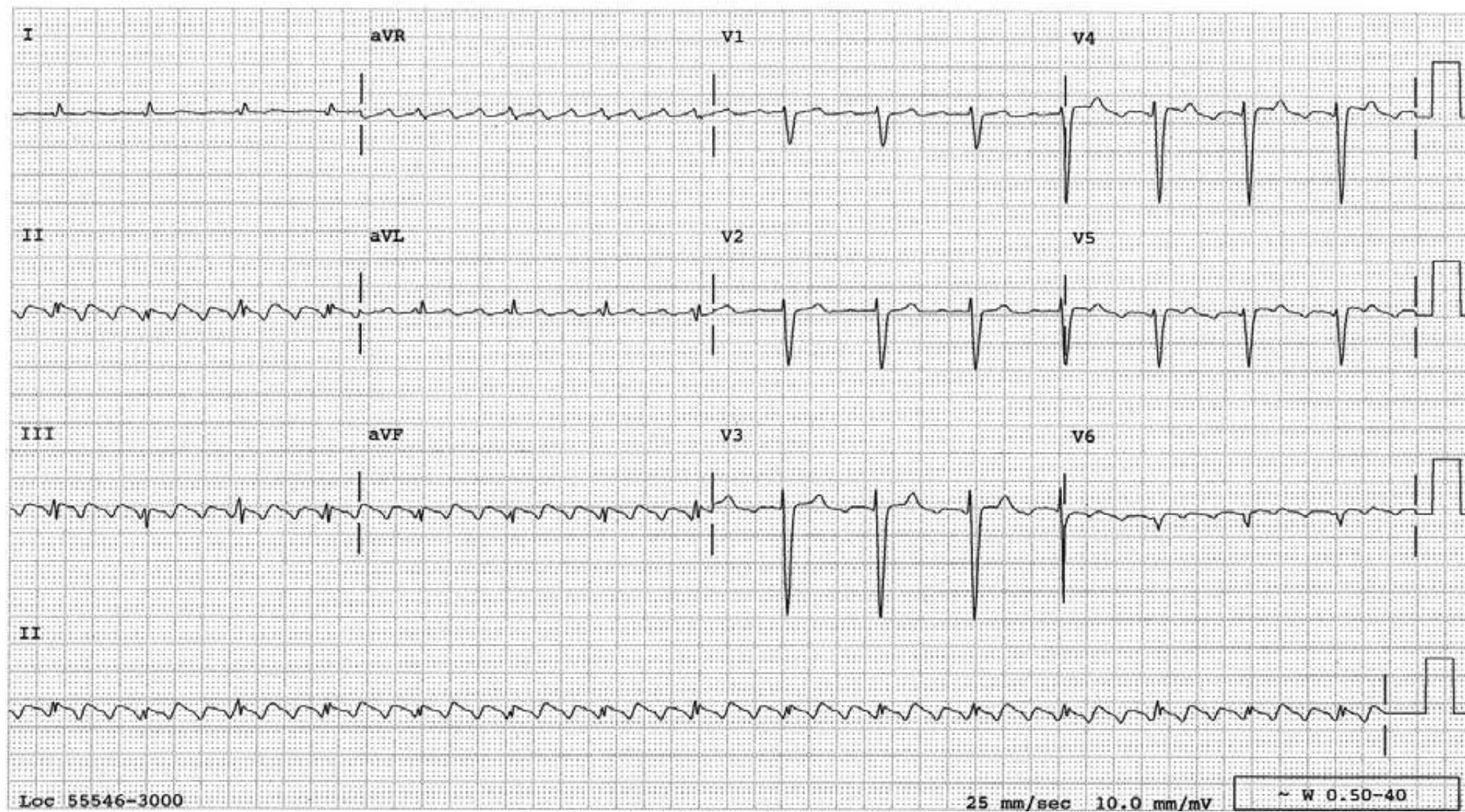


Atrial flutter in which lead aVR is particularly useful in revealing two atrial activities (↓) between the QRSs, helping us to look for and recognize the “domes” of the flutter waves in the inferior leads.





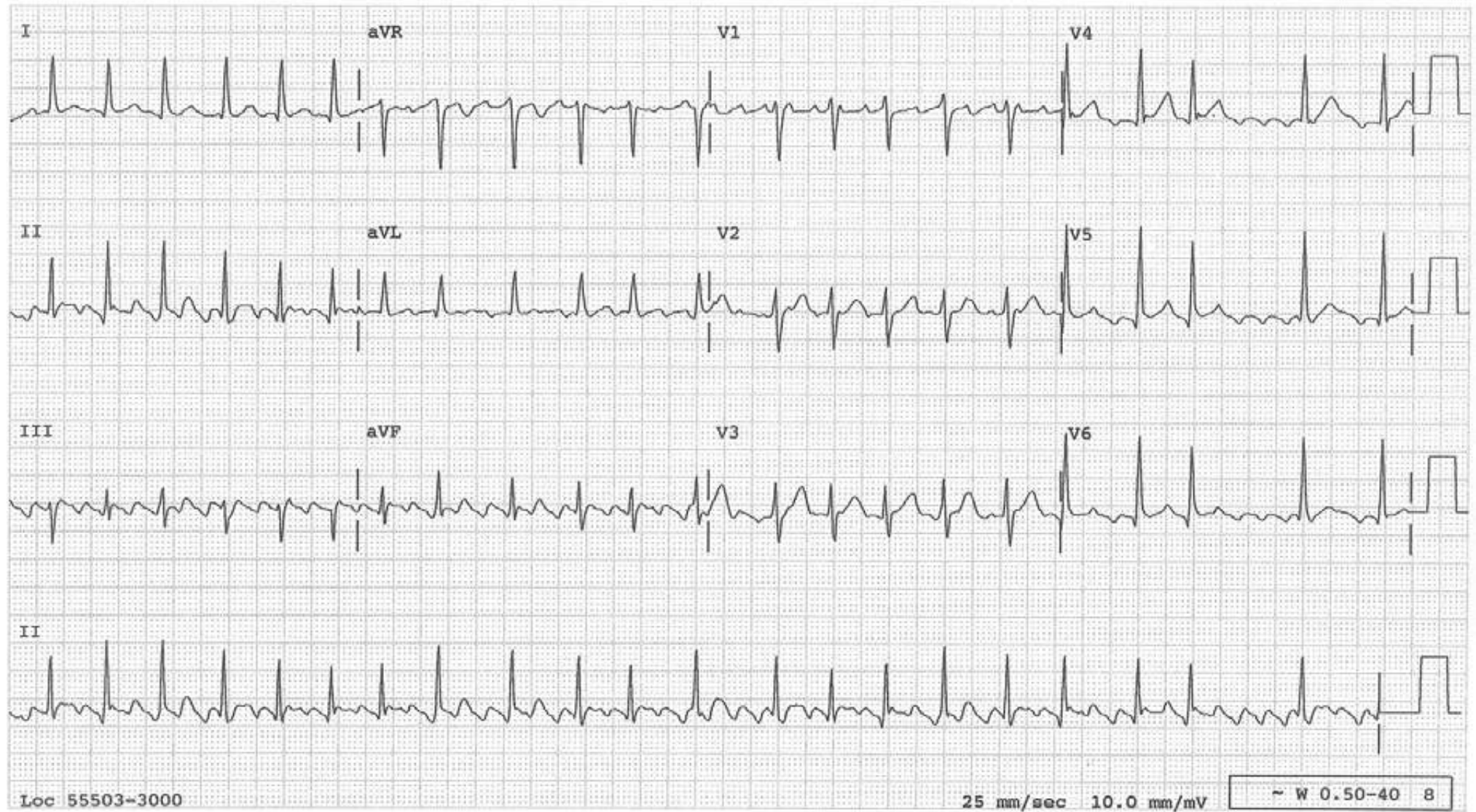
## Atrial Flutter with 3:1 AV Conduction





## Atrial Flutter with Variable AV Conduction Ratio

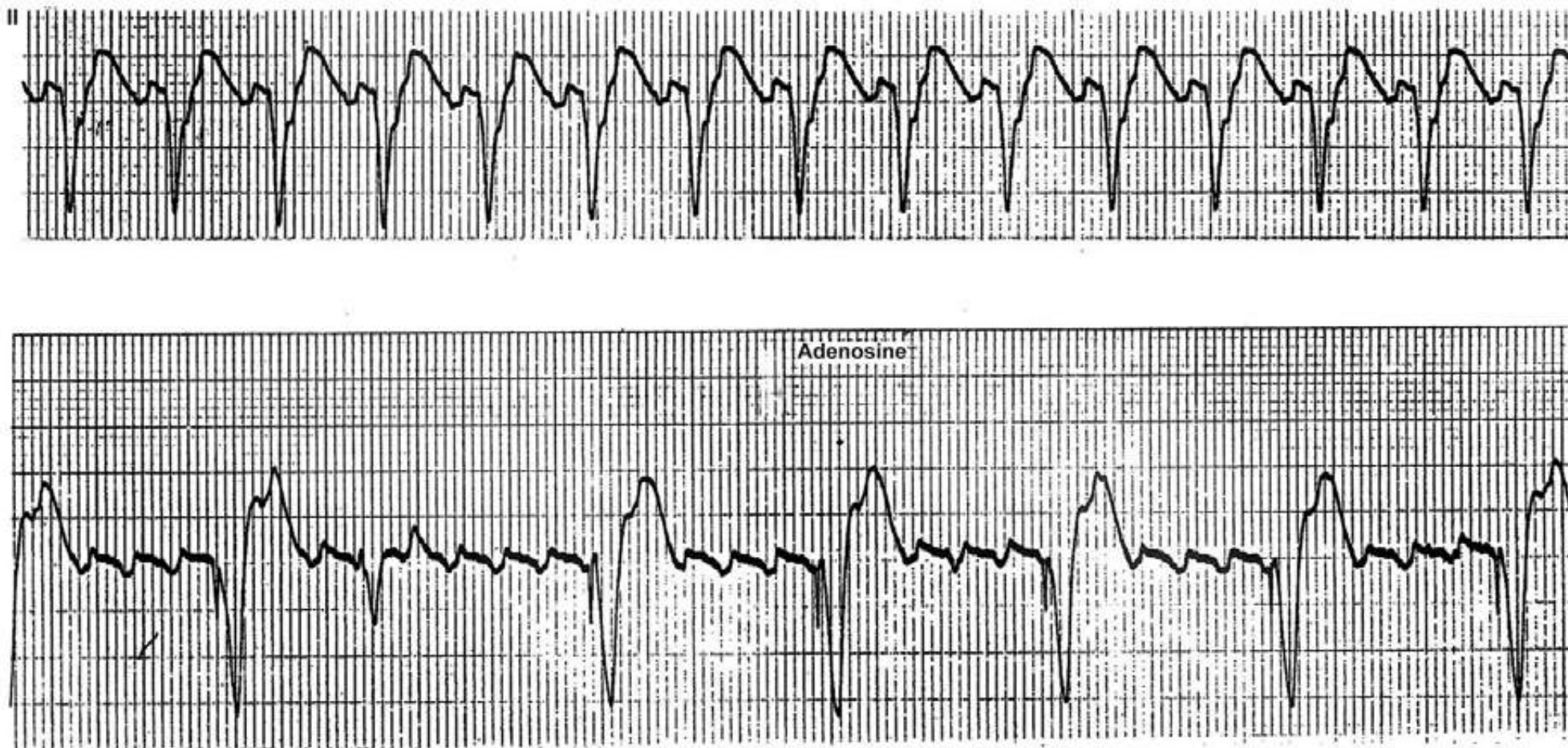
In atrial flutter, there is usually a fixed AV conduction ratio such as 2:1, 3:1, 4:1 etc. That is why the QRSs occur regularly. Occasionally, when the AV conduction ratio varies, an irregularly irregular rhythm results as in this case.





### The Effect of Adenosine in Atrial Flutter

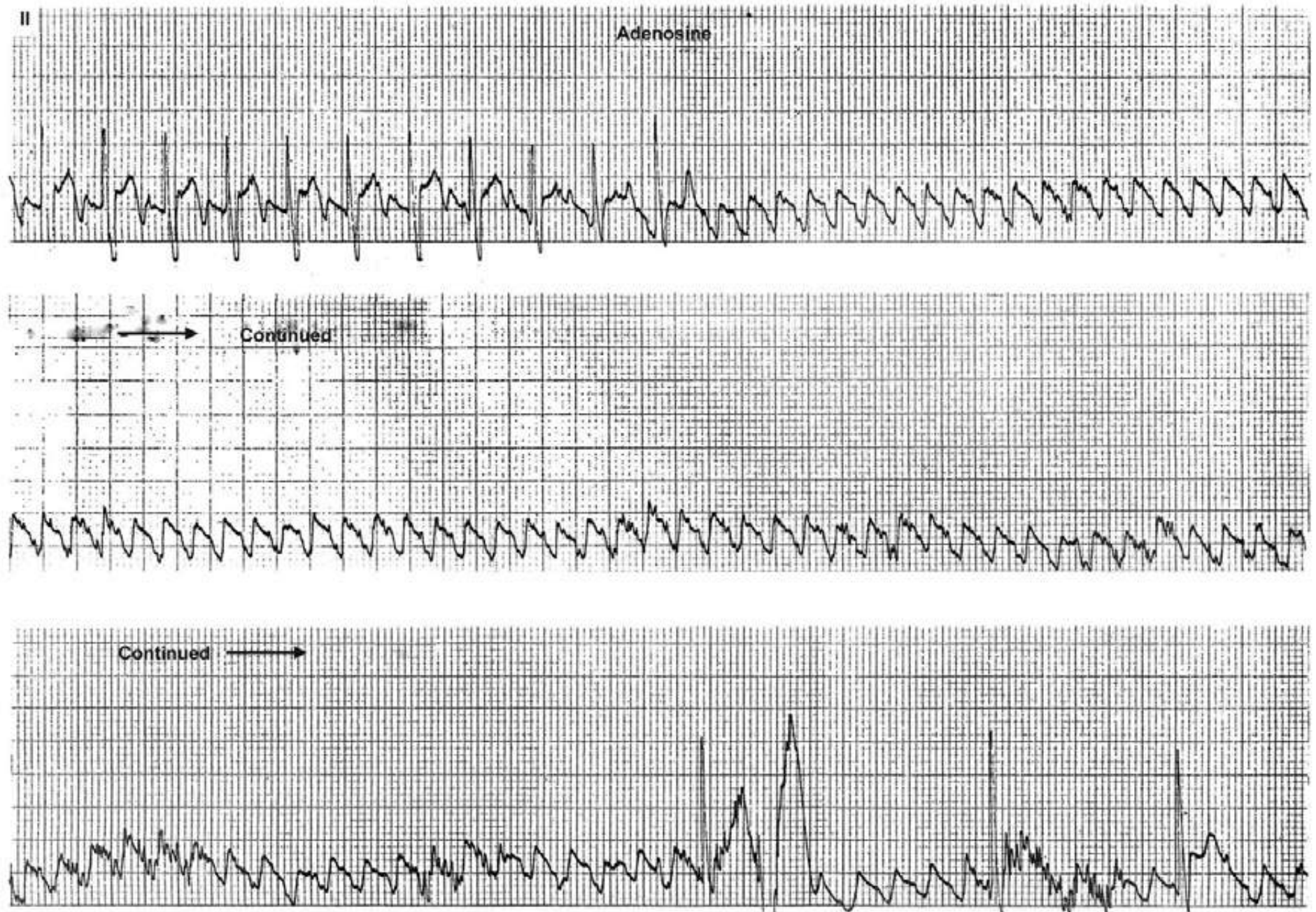
The upper tracing shows a regular tachycardia at a rate of 130/min. It is not clear what the rhythm is. In the lower tracing, adenosine causes AV block and intact flutter waves are revealed (the QRSs are electronically paced).





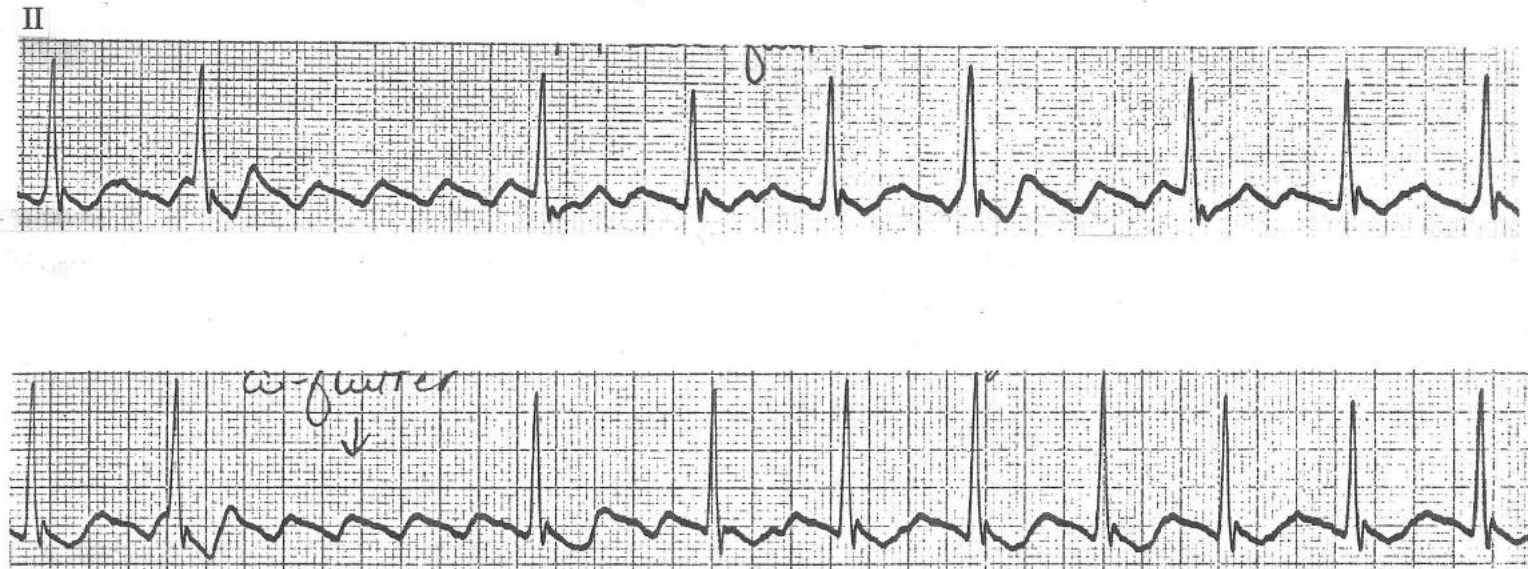
## The Effect of Adenosine on Atrial Flutter

A prolonged AV block may occur at times, as in this case. Adenosine almost always causes varying degrees of pauses, and patients don't like it. Note that it induces AV block, but does not convert the rhythm to sinus.



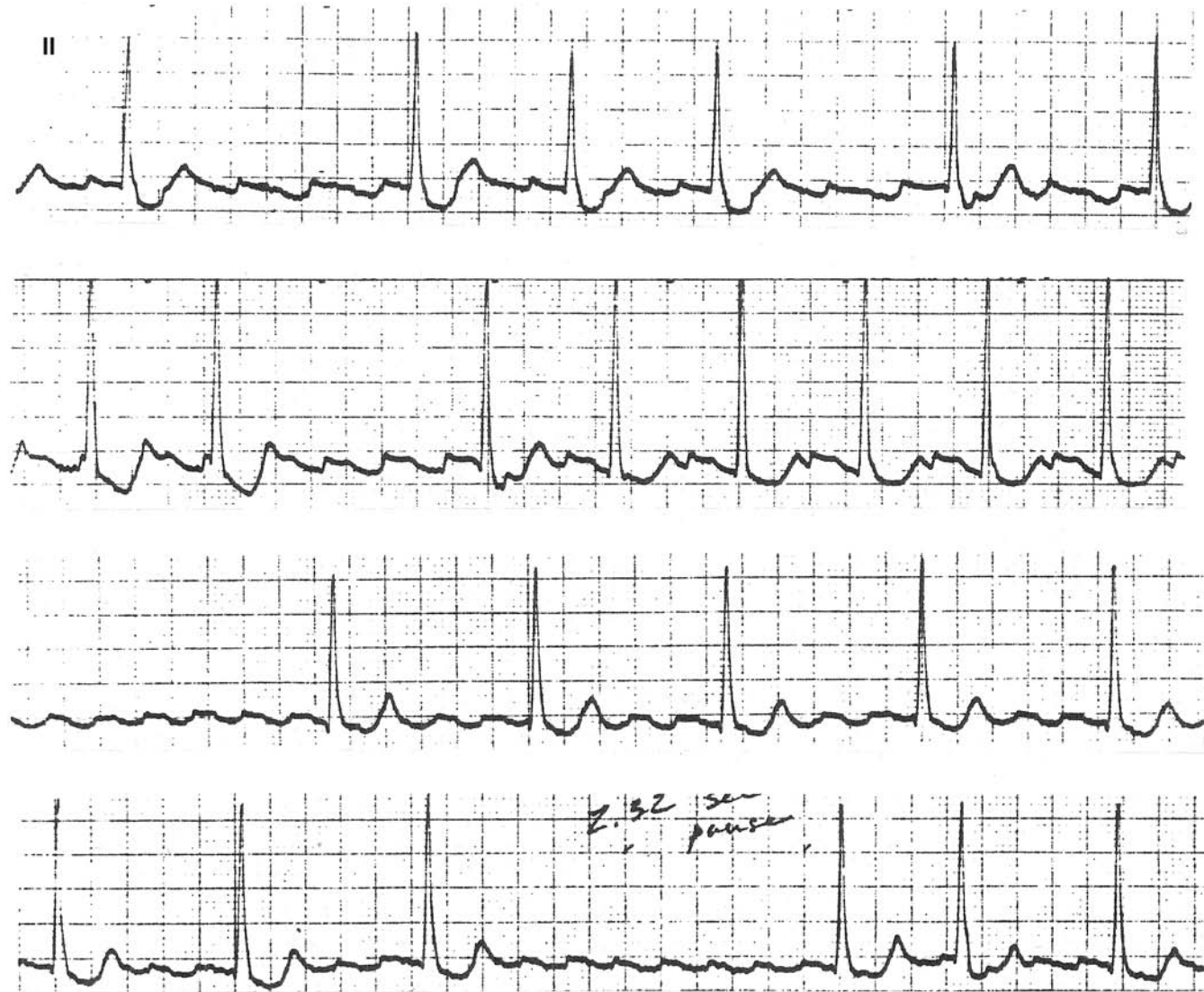

Slow Atrial Flutter (180/min) from a Patient on Quinidine



## Slow Atrial Flutter

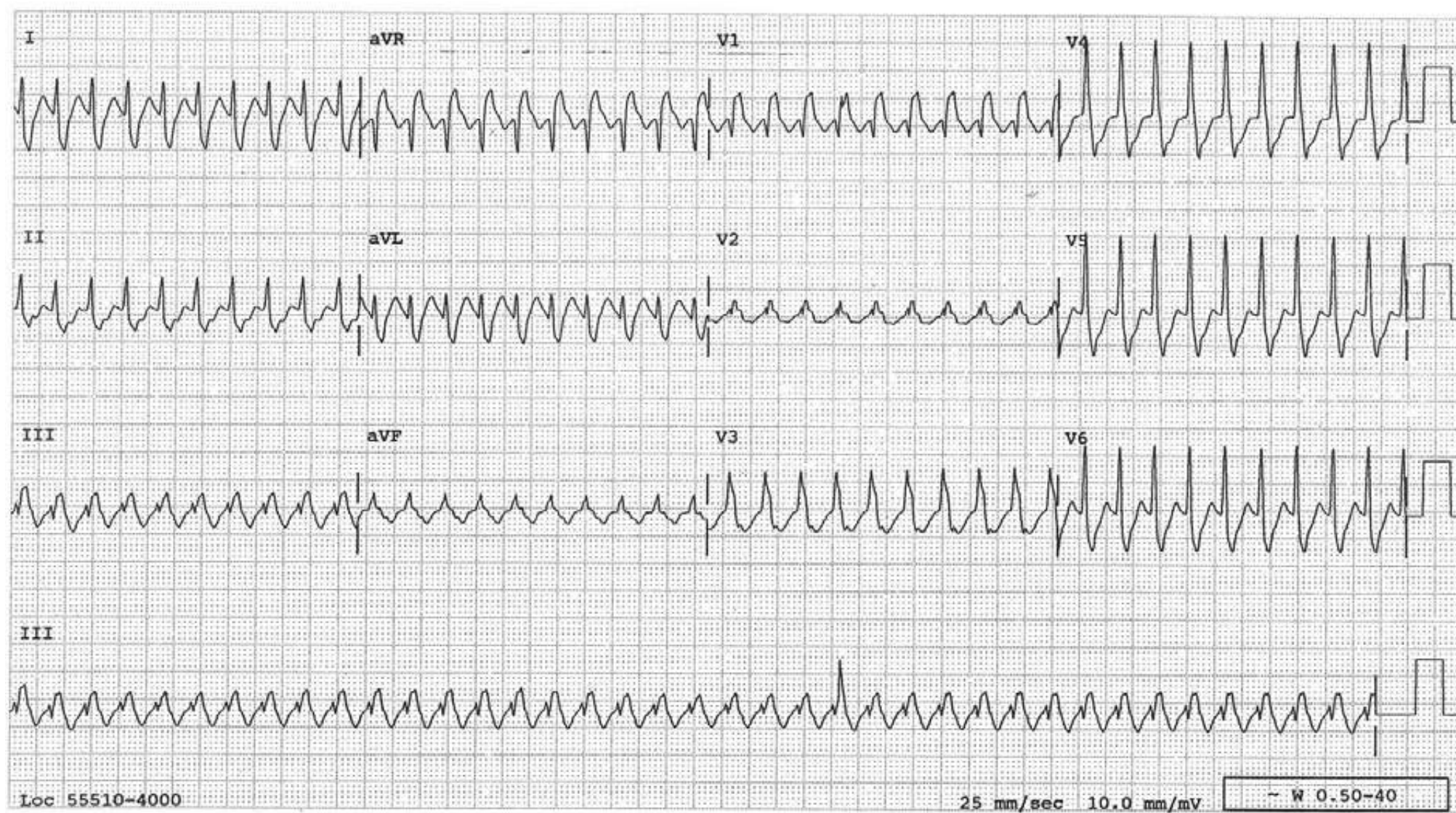
The atrial flutter rate is slow at 150/min while the patient is on procainamide. It gradually speeds up to 230/min as the procainamide effect wears off. This is not atrial tachycardia because the baseline continuously slopes up, then slopes down. In atrial tachycardia there is an isoelectric baseline between the discrete P waves, even in lead II.





### Atrial Flutter with 1:1 Conduction to the Ventricle

This is a proven case of atrial flutter with 1:1 conduction to the ventricle at a rate of 232/min, a rate too fast for this right bundle branch and aberrancy of RBBB-type results.

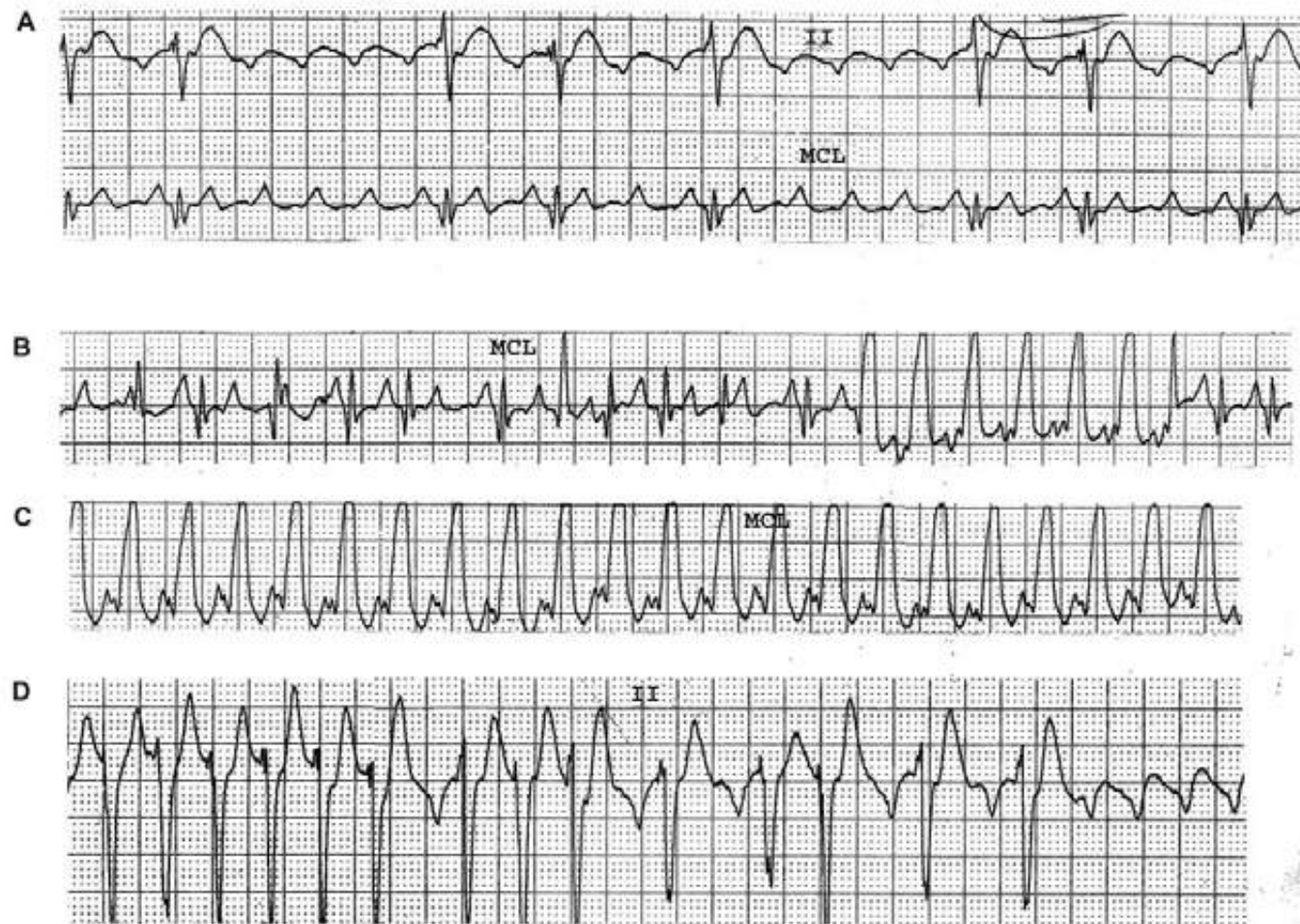




## Atrial Flutter with 1:1 AV Conduction

Atrial flutter at an atrial rate of 210/min with variable AV conduction is evident in strip A. In strip B, the AV conduction ratio decreases and, near the end of the strip, it becomes 1:1 at a ventricular rate of 210/min. This rate is too fast for the intraventricular conduction system and aberrant ventricular conduction results. Strip C reveals steady 1:1 AV conduction. In strip D, the conduction ratio increases and intact flutter waves are again revealed at the end, confirming that the atrial flutter at a rate of 210/min continues throughout.

The atrial rate in atrial flutter is usually about 300/min. The AV junction, due to the physiologic refractory period, is not able to respond 1:1 at this rate, but is able to respond 2:1, resulting in a ventricular rate of about 150/min. Antiarrhythmic agents, especially type I agents, are well known to slow down the flutter rate. Along the way, the flutter rate may become slow enough for the AV junction to conduct 1:1 and the ventricular rate becomes 240, 220, or 200/min, etc. The patient who tolerates the ventricular rate of 150/min reasonably well may not tolerate these faster ventricular rates. That is the danger of starting these antiarrhythmic agents in patients with atrial flutter as an outpatient.

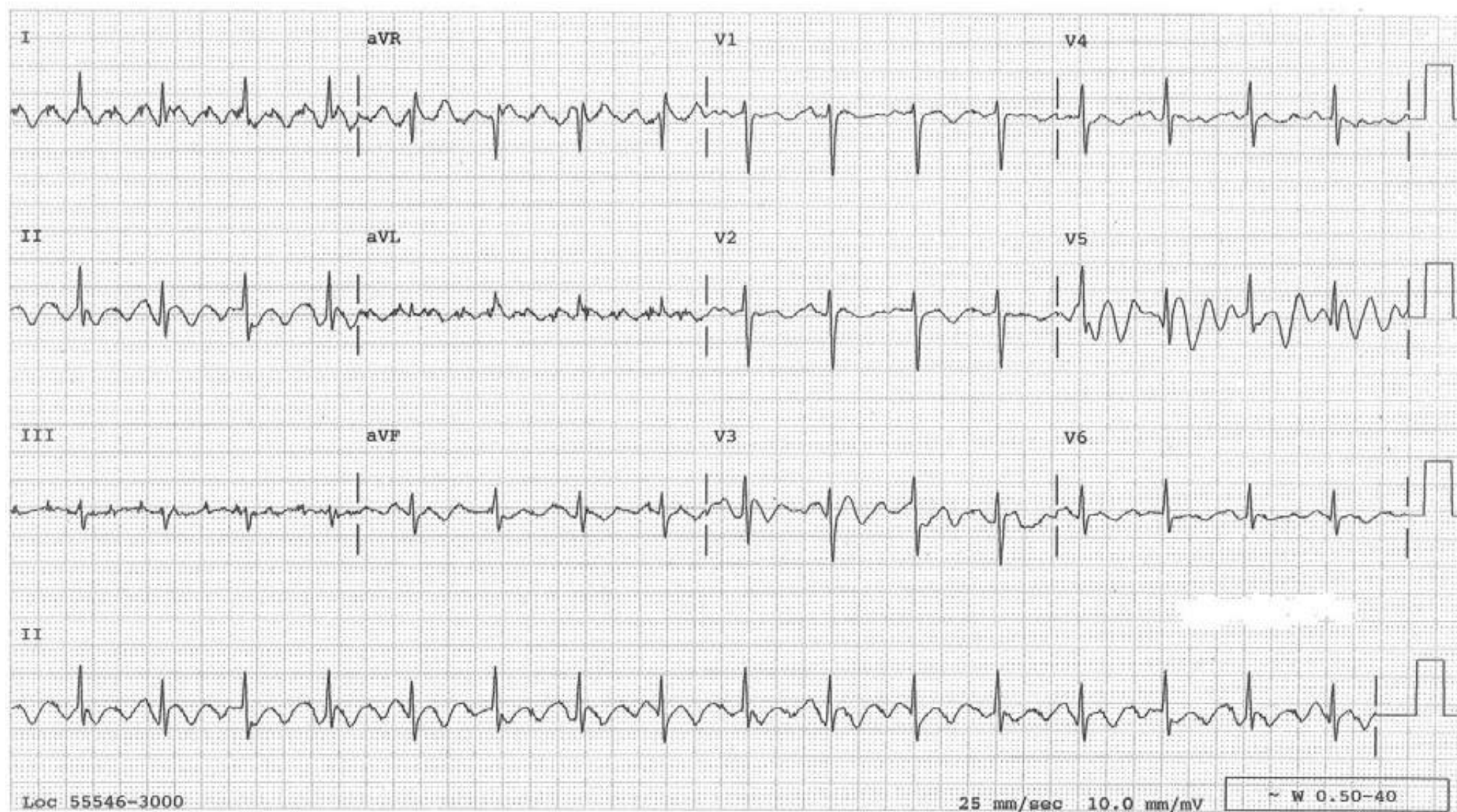

## Artifact Simulating Atrial Flutter

Regular narrow QRS rhythm at a rate of 97/minute. Lead I makes one think strongly of atrial flutter. However this is an example of muscle tremor simulating atrial flutter.

The clues:

1. The “flutter” wave is present in the wrong lead. Typically it should be present in the inferior leads, not in lead I.
2. The QRSs occur regularly indicating that, if this were atrial flutter, there is a fixed AV conduction ratio and in that case, the flutter wave should maintain a fixed temporal relationship to the QRS, which is not the case here.
3. The findings in V5 do not look like atrial flutter waves.

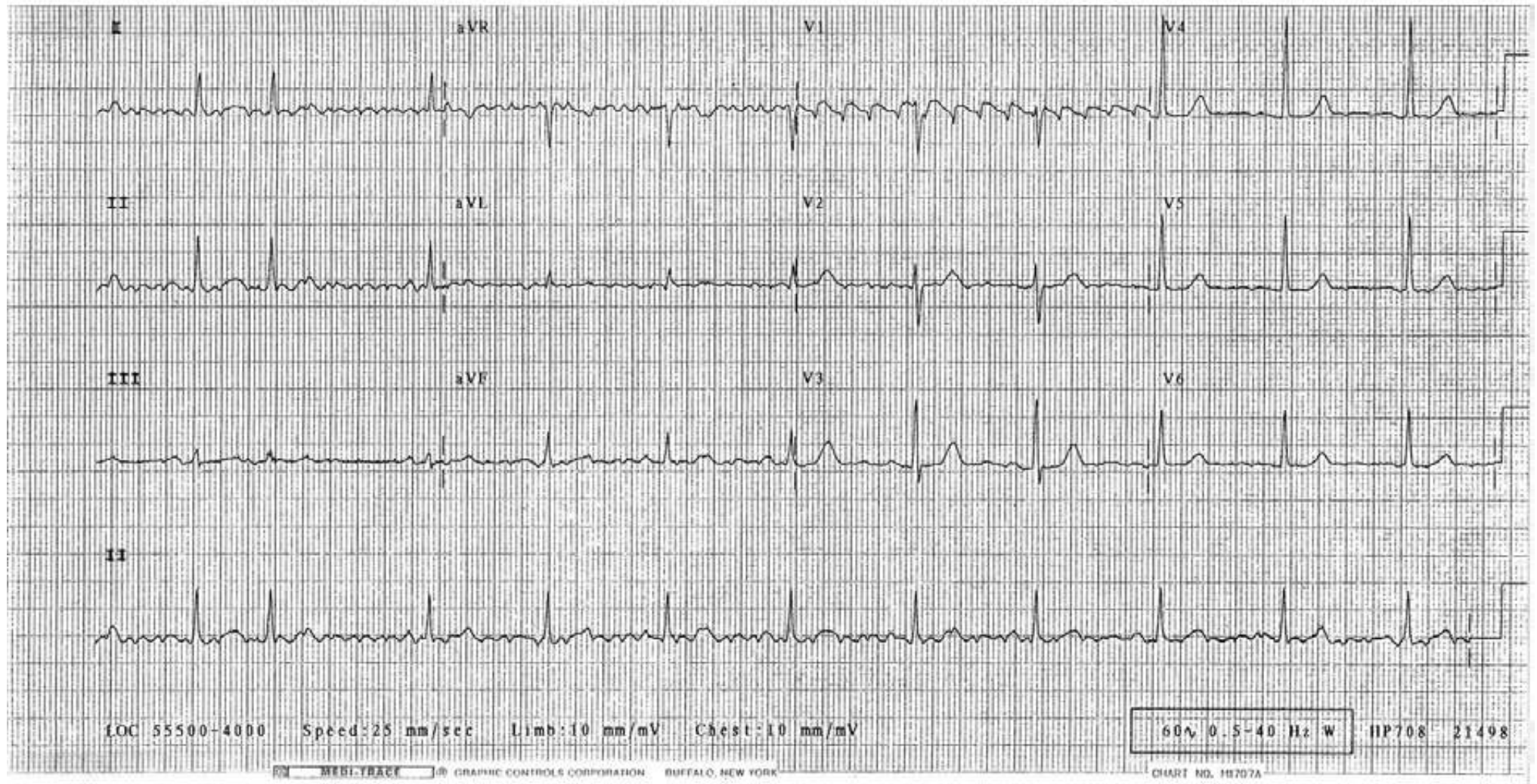




## Artifact Simulating Atrial Flutter

Muscle tremors may cause waves that simulate the “saw tooth” pattern of atrial flutter, and this is such an example. The clues to the correct diagnosis are:

- The “saw tooth” pattern is in the wrong lead; typically it is present in the inferior leads, only rarely in V1.
- Sinus P waves are recognizable in leads III and V3.
- The QRSs occur regularly (except the 2<sup>nd</sup> one, which is an APB), indicating that, if this is atrial flutter, there is a fixed AV conduction ratio of 4:1 or 5:1. In that case, the flutter wave should maintain a fixed temporal relationship to the QRS, but the flutter-like waves in this tracing do not.



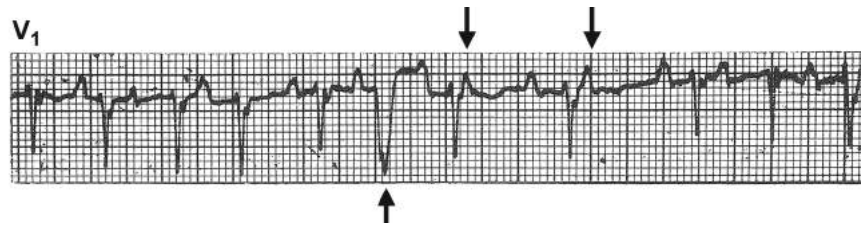


## Multifocal Atrial Tachycardia

The essential features of multifocal atrial tachycardia (MAT) are discrete P waves of changing morphology, an atrial rate greater than 100/min and irregular PP intervals, hence, changing PR and R-R intervals. It can be considered that every beat in MAT is a PAC originating from different foci. Often, the P waves are inconspicuous and MAT may simulate atrial fibrillation. However, in contrast to atrial fibrillation, digitalis is usually not effective in slowing the ventricular response in MAT. Continued incremental use of digitalis may result in fatal arrhythmias. Therefore, it is important to distinguish MAT from atrial fibrillation.

Important aspects of MAT are:

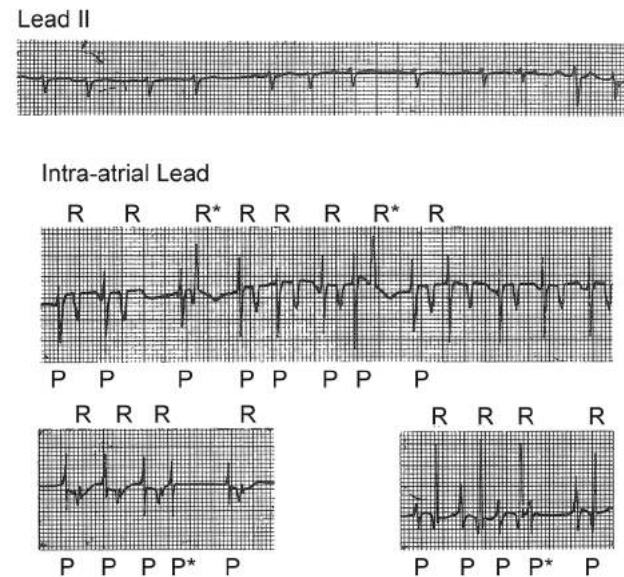
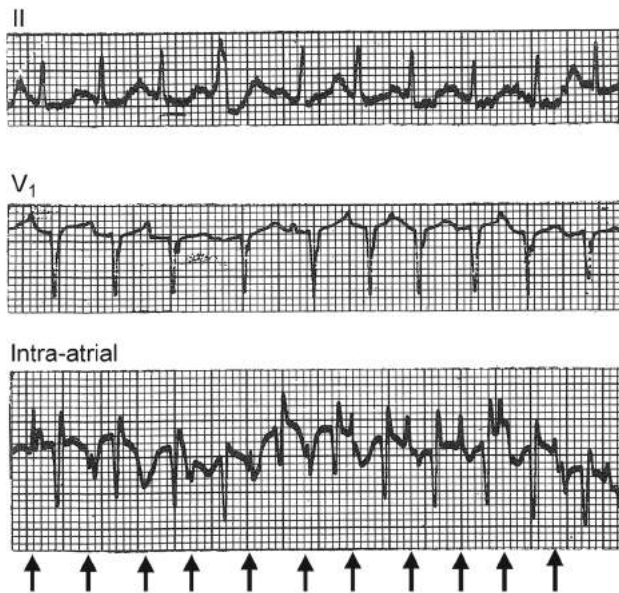
- Occurs in any stressful medical conditions, but most often in patients with acute respiratory distress (29 out of 36 cases in one series).
- Not a manifestation of digitalis intoxication.
- A simulator of atrial fibrillation.
- Unstable rhythm which often precedes and/or follows atrial fibrillation or atrial flutter (16 out of 36 cases).
- High in-hospital mortality (33%) reflects the seriousness of the underlying conditions.
- Digitalis is usually not effective in slowing the ventricular response.
- An electric shock to the precordium does not convert the rhythm.
- Treatment should be directed towards the underlying conditions.
- Beta-blockers, verapamil, or diltiazem are effective in slowing the atrial rate, and hence, the ventricular response.
- MgSO<sub>4</sub> is known to convert the rhythm to sinus occasionally.



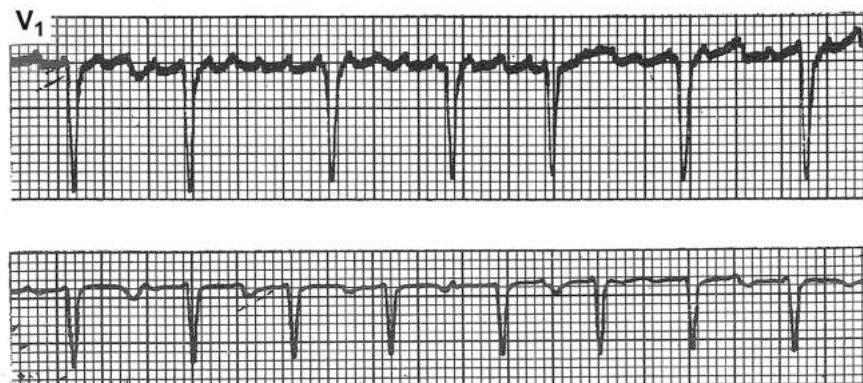An example of MAT characterized by P waves of changing morphology occurring at irregular intervals. This in turn results in changing PR and RR intervals. Usually each atrial depolarization is conducted to ventricles. Occasionally, atrial depolarization occurs very early when atrioventricular conduction system is refractory and results in a nonconducted atrial beat (↓) or in aberrant ventricular conduction (↑).

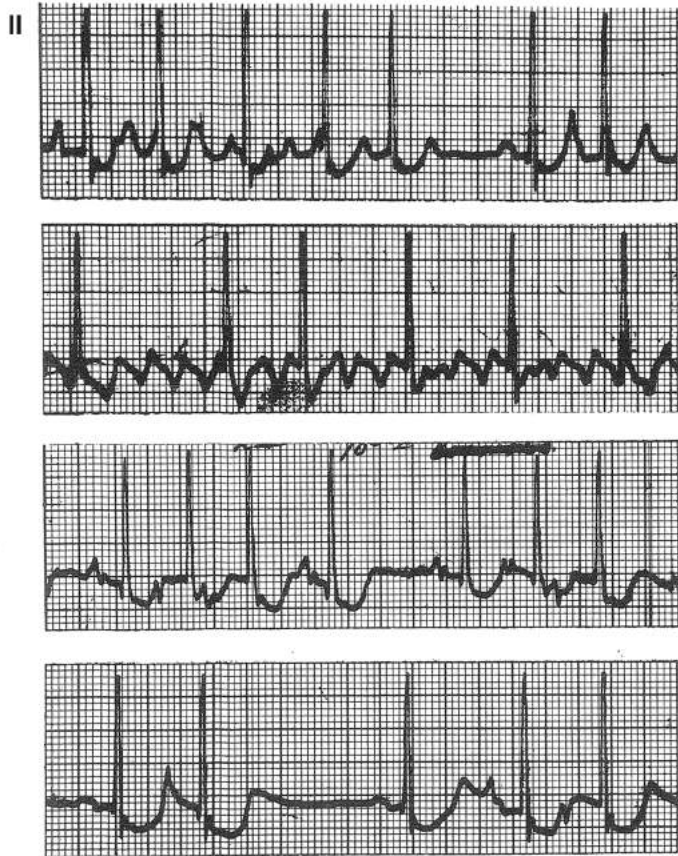
P waves are inconspicuous in lead II and are barely discernible in lead  $V_1$ . Right atrial electrogram clearly demonstrates atrial activity (arrows) in front of each QRS.

P waves are inconspicuous in lead II of this patient. Right atrial electrogram in same patient clearly demonstrates atrial activity in front of each QRS. R\* indicates aberrantly conducted beats, P\*, nonconducted P waves.



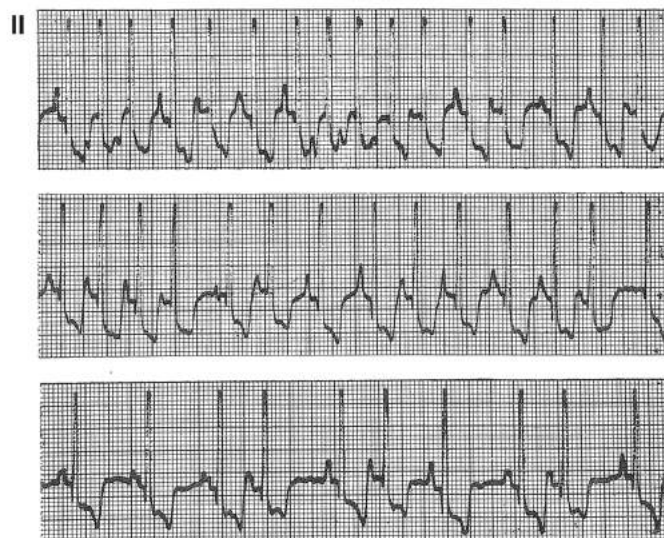
Atrial fibrillation in the upper tracing is followed by MAT (lower tracing).





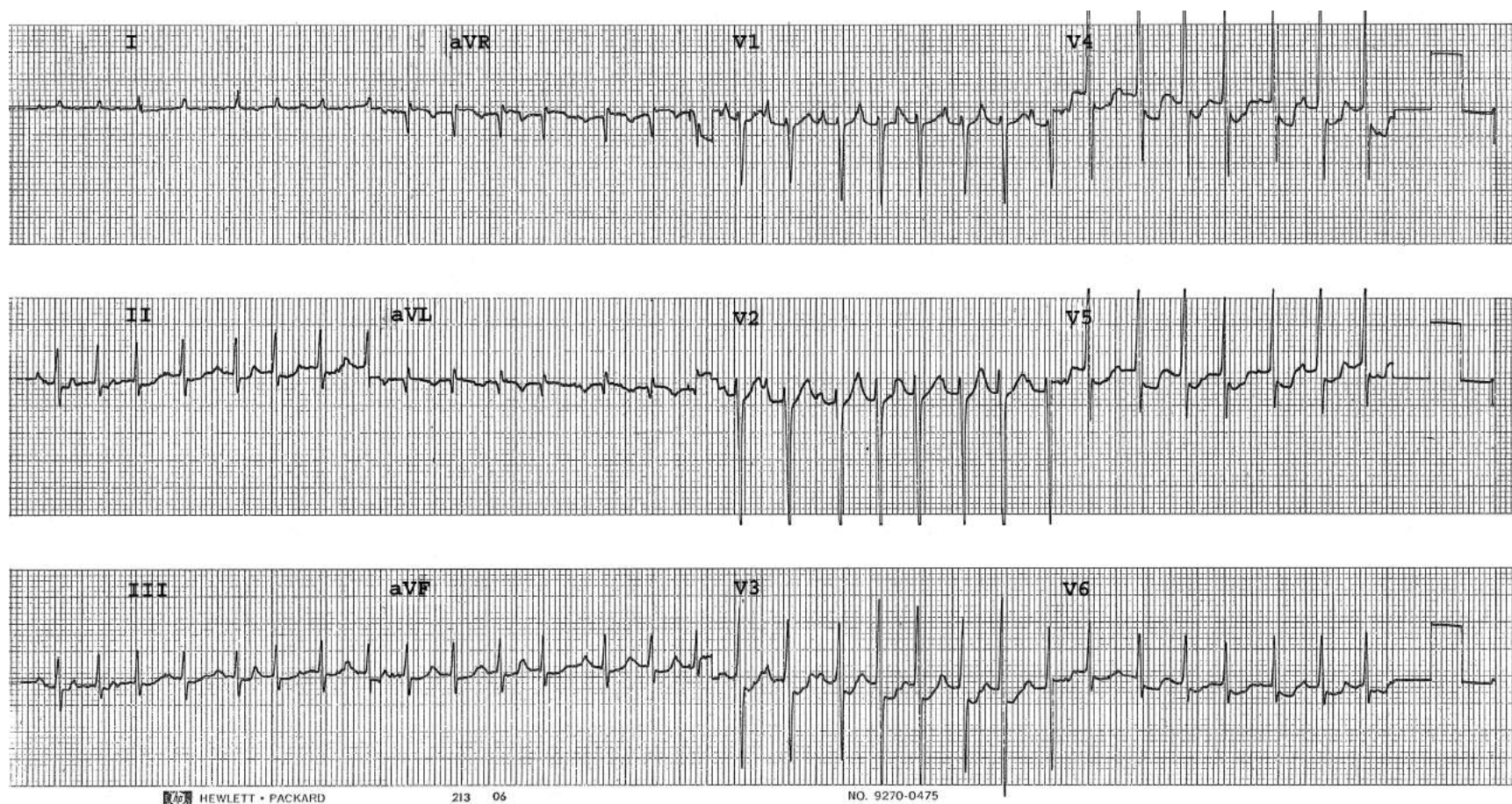
MAT (1st and 3rd tracings) preceded and followed atrial flutter (2nd tracing) in this patient. Propranolol was given orally and average atrial rate decreased from 150/min to 100/min.

Characteristic response of MAT to propranolol given orally. Average atrial rate decreased from 190/min to 150/min and then to 110/min within an hour





An example of MAT where the P waves are clearly identifiable in V1 and in a few other leads, but in some leads such as V4 or V5, the tracing certainly simulates atrial fibrillation.



## Ventricular Premature Beats (VPBs or PVCs)

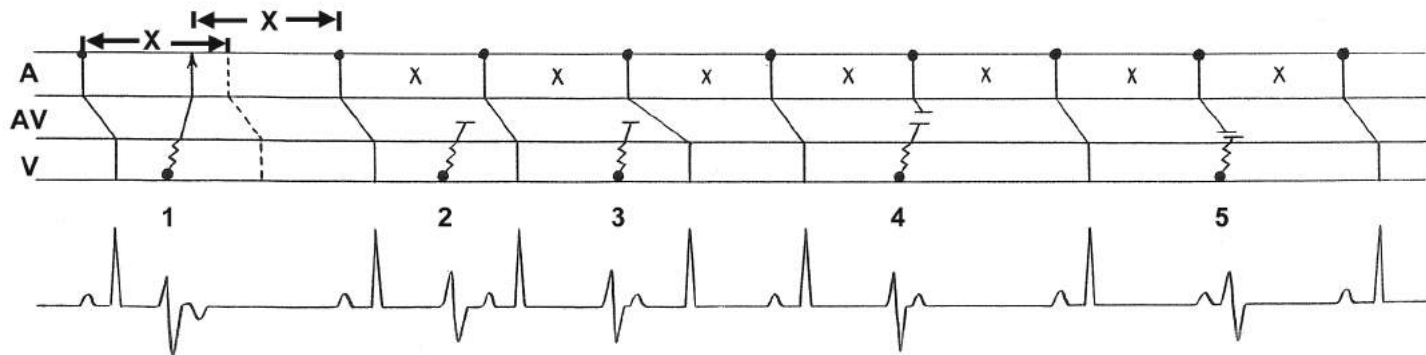
**VPB 1:** A VPB can occur very early, as long as the ventricular tissue has recovered from refractoriness. The impulse from this VPB conducts retrogradely to the AV junction, then to atria, resulting in a negative P wave. Moreover, this retrograde impulse depolarizes the sinus node and resets the sinus mechanism. The next sinus impulse occurs X distance (sinus cycle) after the retrograde depolarization. This VPB is accompanied by a compensatory pause, but it is less than a full compensatory pause (shorter than two basic cycle lengths).

**VPB 2:** The impulse from this VPB is blocked on its way to the AV junction. It does not retrogradely depolarize the atrial tissue. Rather, the atria are depolarized by the regularly occurring sinus mechanism and the impulse conducts to the ventricle in the usual manner. This VPB is sandwiched between two consecutively conducted sinus beats and is called an interpolated VPB. There is no compensatory pause after this VPB.

**VPB 3:** The impulse from this VPB is blocked on its way to the AV junction, as happened with VPB 2. This retrograde conduction into the AV junction makes the AV junctional tissue partially refractory. When the next sinus impulse conducts to the ventricle, it takes longer to pass through the AV junction, resulting in a prolonged PR interval. This VPB is also an interpolated VPB.

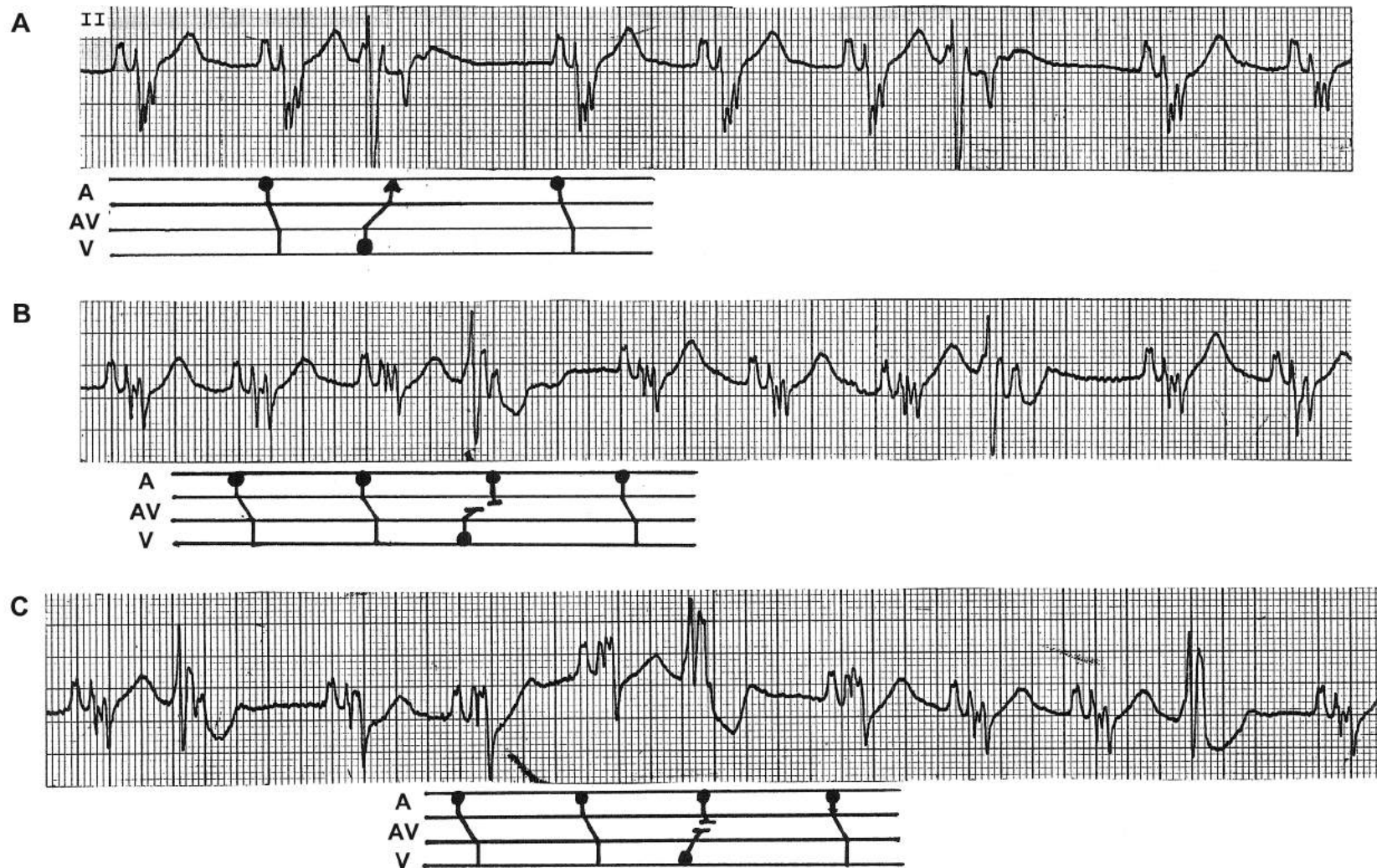**VPB 4:** This is the most common manifestation of a VPB. The retrograde conduction from this VPB is colliding with the anterograde conduction of the normal sinus impulse within the AV junction. There is momentary AV dissociation for this beat. The sinus node is not reset, and the next sinus impulse occurs at the scheduled time, and conducts to the ventricle normally. This VPB is followed by a full compensatory pause, i.e., the pause compensates for the VPB's prematurity so that the interval from the preceding sinus beat to the succeeding sinus beat is equal to two sinus cycles.

**VPB 5:** A VPB can occur very late, even after the atria have already been activated by the sinus impulse. Therefore, it is preceded by a sinus P wave, as in this case. This "end-diastolic" VPB also has a full compensatory pause.

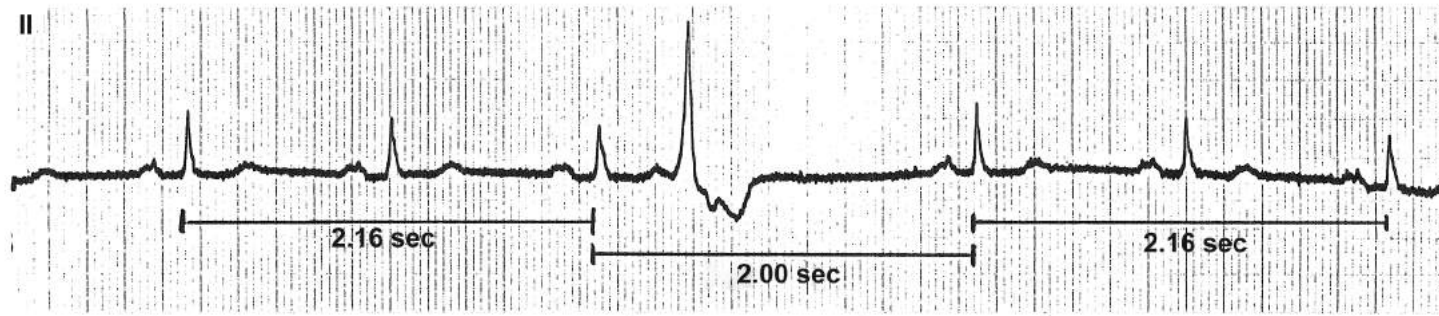




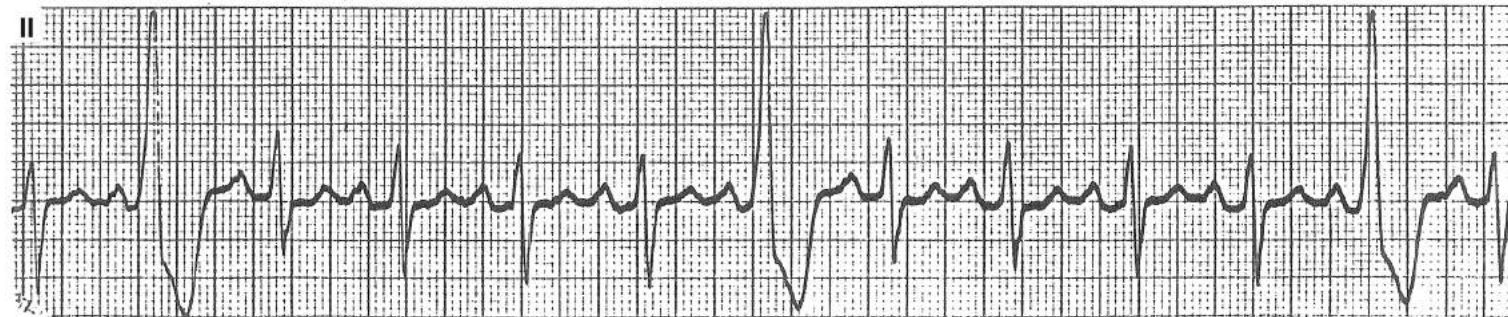
These rhythm strips reveal various manifestations of VPBs. Some occur early enough to depolarize the atria retrogradely (A). If they occur a little later, they would fail to do so, and the atria are depolarized by the normal sinus impulse, resulting in a positive P wave (B). At times, these P waves are visible, while at other times they are buried within the VPB (C).



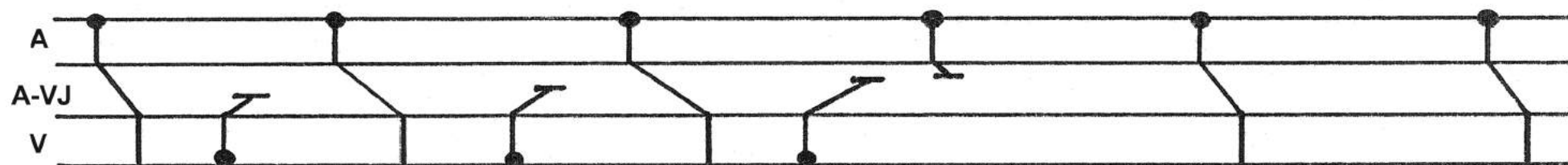
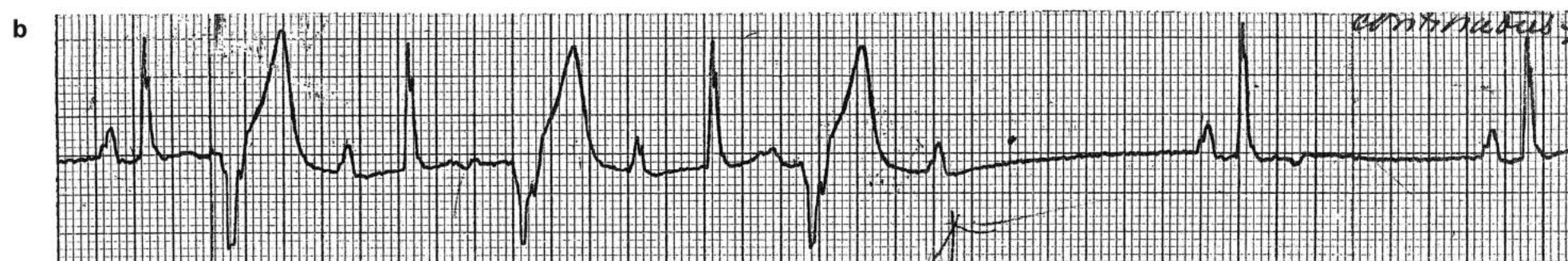
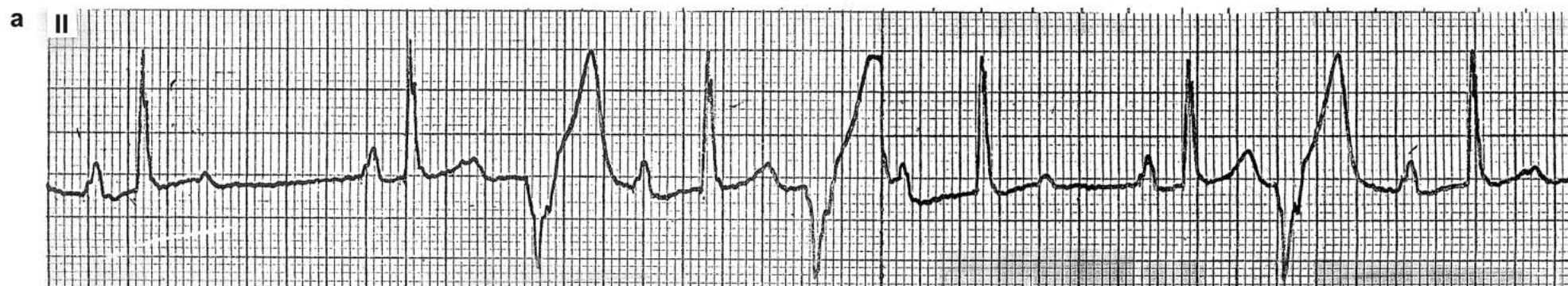




In this tracing, a VPB occurs very early. It is able to depolarize the atria retrogradely, resulting in an inverted P wave. The sinus node is also depolarized from this retrograde impulse and is reset. Because the sinus mechanism is reset, the interval from the preceding sinus beat to the next sinus beat is less than twice the basic cycle length (2 seconds instead of 2.16 seconds).



In this tracing, the VPBs occur late enough to be preceded by a sinus P wave. Note that the P waves march out, indicating that these are not APBs with aberrant conduction. Moreover, the P wave to the wide complex interval is shorter than the PR interval of sinus beats.



In the upper tracing, there are many interpolated PVCs. The impulse from each of these PVCs penetrate AV junction retrograde while failing to conduct all the way to the atrium (concealed conduction). This concealed conduction “disturbs” the AV junction so that the subsequent sinus impulse is conducted to the ventricle with a longer PR interval. An interesting phenomenon happens in the lower tracing as diagrammed. These concealed retrograde conduction disturb the AV junction progressively more and more, causing the P waves to conduct to the ventricle with progressively longer PR intervals until finally a P wave is completely blocked: a pseudo AV Wenckebach phenomenon.



## Usefulness of Ventricular Premature Beats

This patient with alcoholic cardiomyopathy was admitted in frank congestive heart failure. The rhythm strip initially revealed a wide complex tachycardia at a rate of approximately 120/min (strip a). The patient had a bundle branch block and the QRS morphologies were identical when compared to the tracing taken previously when she was in normal sinus rhythm. However, no P waves were identified, raising the possibility of many ECG diagnoses.

Strip b revealed a premature beat which had a flat ST segment and a blip suggestive of atrial activity. In strip c, this premature beat occurred again, revealing a blip suggestive of a P wave. The interval from the blip to the QRS was identical to that of the distorted downslope of the T wave to the next QRS. This strongly suggested sinus tachycardia with a slightly prolonged PR interval. The patient was treated with diuretics and digitalization. Within 2 days, her clinical condition improved remarkably. The rhythm strip taken at that time (strip d) revealed that the ventricular rate had slowed from 120 to 85. There appeared to be one P wave for each QRS with a prolonged PR interval.

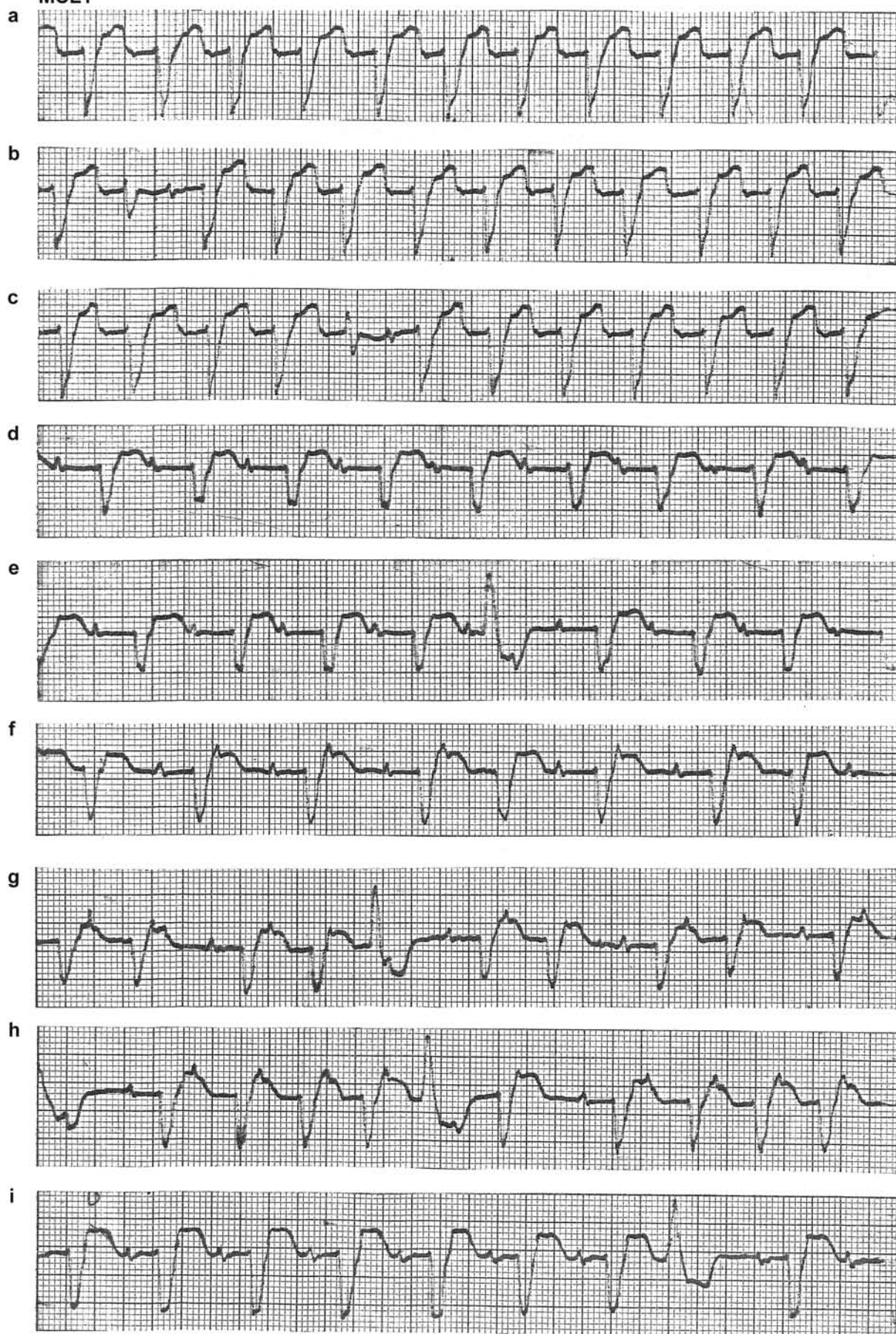
It was assumed that the sinus rate had slowed with the improvement of the cardiac condition and the prolonged PR interval was secondary to the digitalis effect. The patient, however, had occasional VPBs and in the ST segment of the VPB, there was a blip, suggestive of an extra P wave. The blip occurred half way between the P-waves before and after the VPB. What actually happened was that the patient developed PAT with 2:1 AV block. This is highly suggestive of digitalis intoxication. The reason why the extra P wave was not seen was because it occurred within the QRS. It was revealed by the ventricular premature beat.

Strip f revealed this extra P wave more clearly. Strips g and h revealed AV Wenckebach periodicity. The diagnosis of digitalis intoxication was made and digitalis was withheld.

Two days later, Fig. i was obtained. At a quick glance, it appeared to indicate a normal sinus rhythm. But again, one could not rule out the possibility of an extra P wave hidden within the QRS. In this situation, one would look for a VPB and indeed she had one. The ST-segment of this VPB was smooth without any extra blip. At last, one could be convinced that the patient had converted from PAT to normal sinus rhythm and was out of digitalis toxicity.



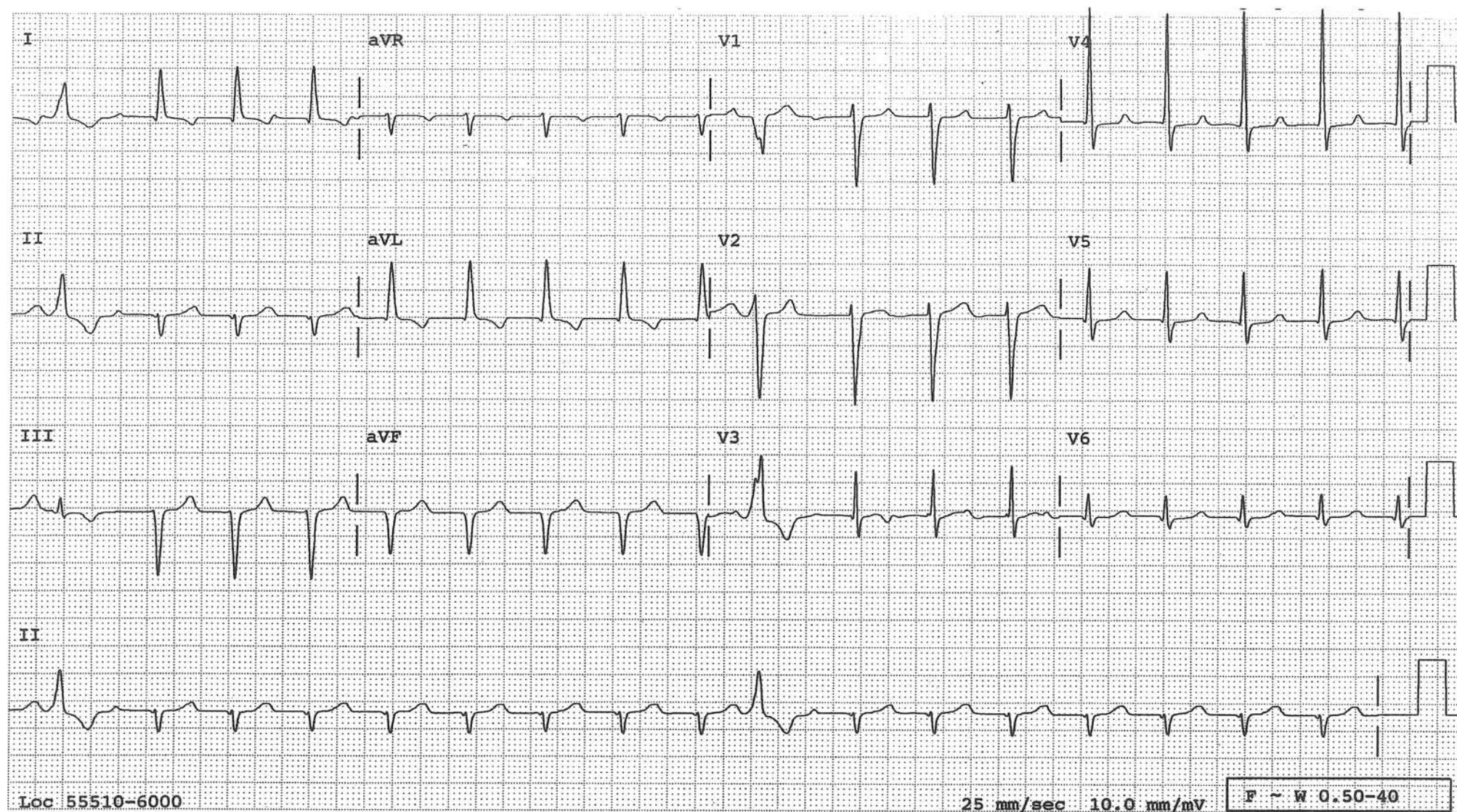
MCL1





## Usefulness of PVCs

Narrow QRS tachycardia at a rate of 105/min is present. P waves are not readily recognizable, and it is difficult to tell what the rhythm is. In the rhythm strip of lead II at the bottom, the compensatory pause after a VPB reveals the P wave convincingly, proving that the rhythm was sinus tachycardia with 1° AV block with the P waves hidden in the T waves.



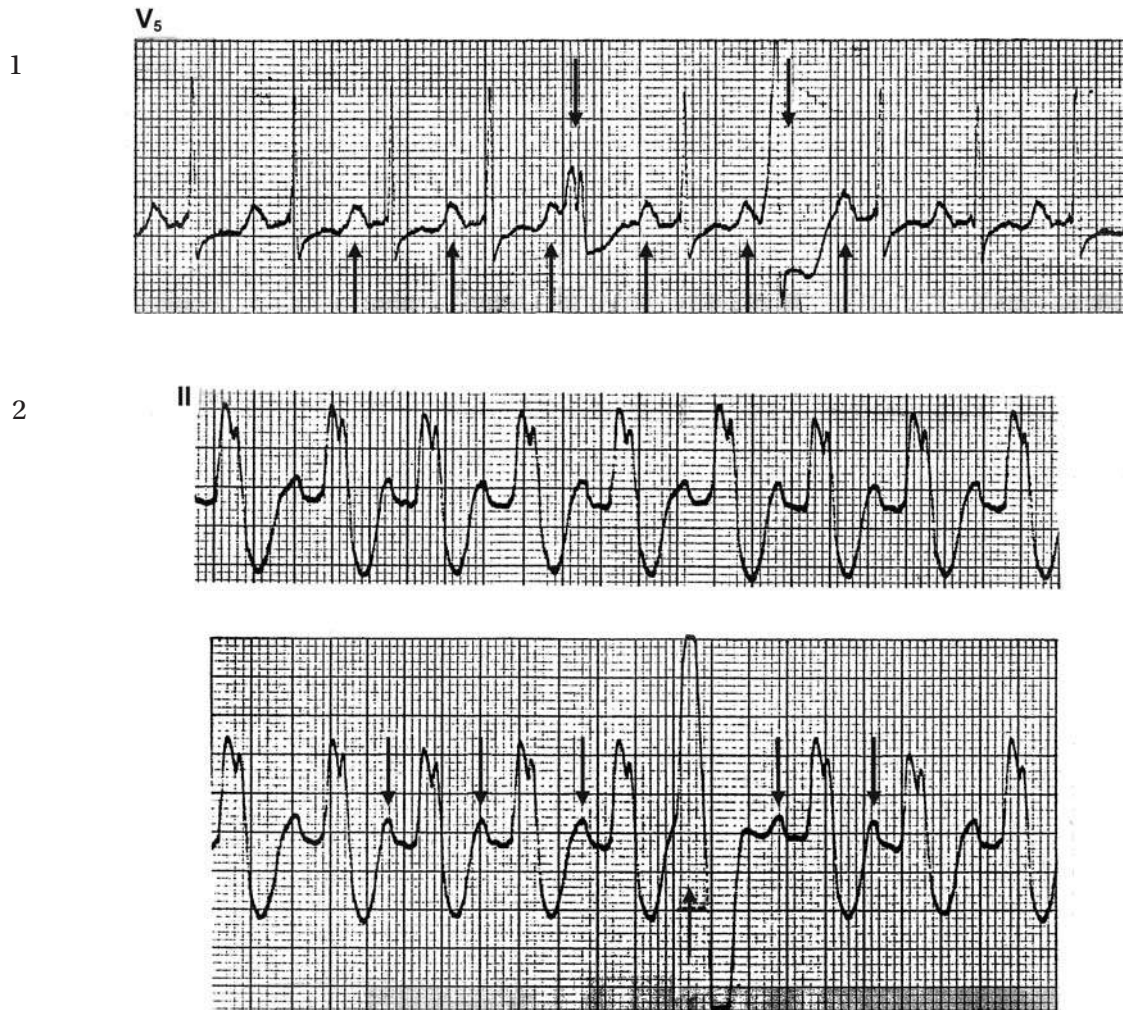


## Revelation of P Waves that are Otherwise Obscured

When a patient has a regular rhythm and only one deflection exists between QRSs, it is sometimes difficult to tell whether the deflection is a P wave, a T wave, or both. In this situation, the compensatory pause after a ventricular premature beat (VPB) may tell us which one it is.

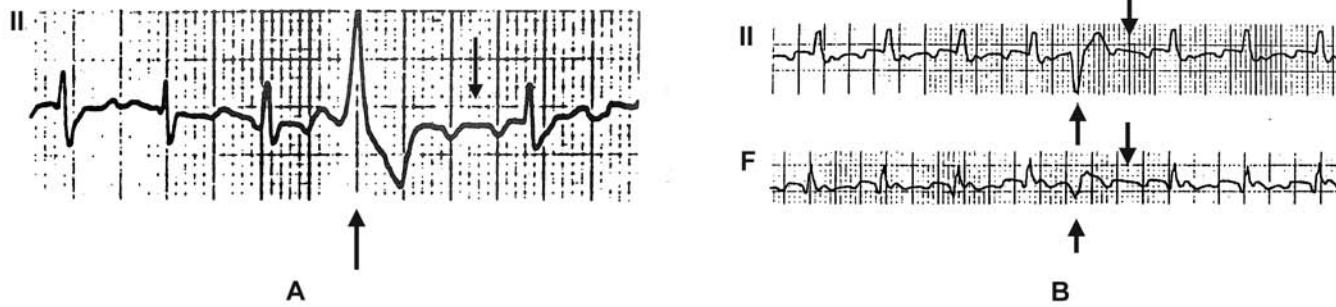
The patient in Figure 1 has a narrow QRS tachycardia at a rate of 120/min. The deflections between the QRSs ( $\uparrow$ ) could be T waves, P waves, or both. The compensatory pauses after the VPBs ( $\downarrow$ ) tell us that they are P waves.

A similar situation is shown in Figure 2. This patient has a wide QRS tachycardia at a rate of 125/min. P waves are not clearly identified, raising the possibility of ventricular tachycardia. In the lower tracing, however, a VPB ( $\uparrow$ ) unmasks the sinus P wave ( $\downarrow$ ), confirming the rhythm to be sinus tachycardia with underlying bundle branch block.

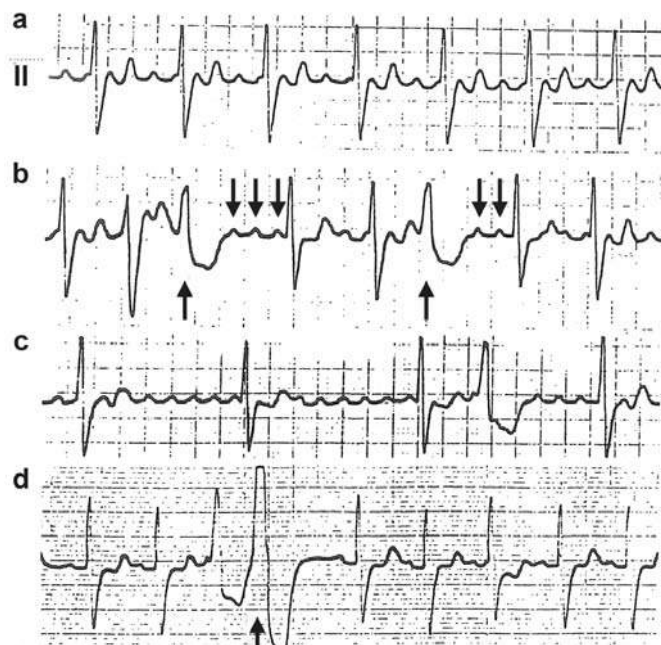




## Revelation of Atrial Flutter Waves by the Compensatory Pause



In the patients A and B, the compensatory pause after a VPB (↑) shows intact atrial flutter waves (↓).



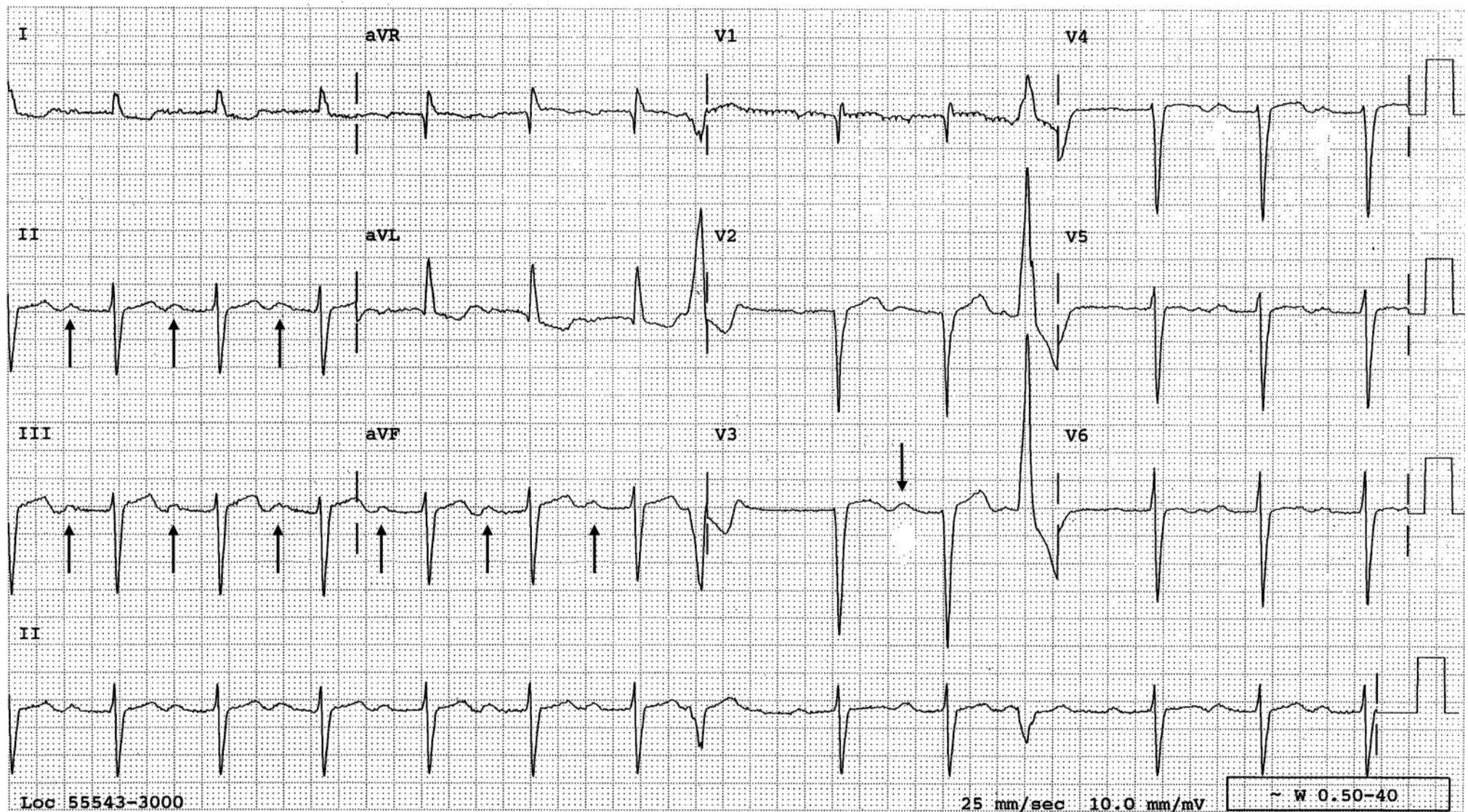
The compensatory pauses after VPBs (↑) showing atrial flutter waves (↓).

- A regular rhythm at a rate of 68 beats per minute. On first glance, the rhythm appears to be sinus with a prolonged PR interval.
- The compensatory pauses that follow the VPBs show a regular atrial mechanism at a rate of 300 beats per minute, indicating that the patient is in atrial flutter.
- The atrioventricular block increases, and the atrial flutter waves become easily recognizable, even without the help of VPBs.
- The compensatory pause after a VPB proves that the flutter waves are gone, allowing one to declare that the atrial flutter has converted to sinus rhythm.



## P Waves or U Waves or Summation of Both?

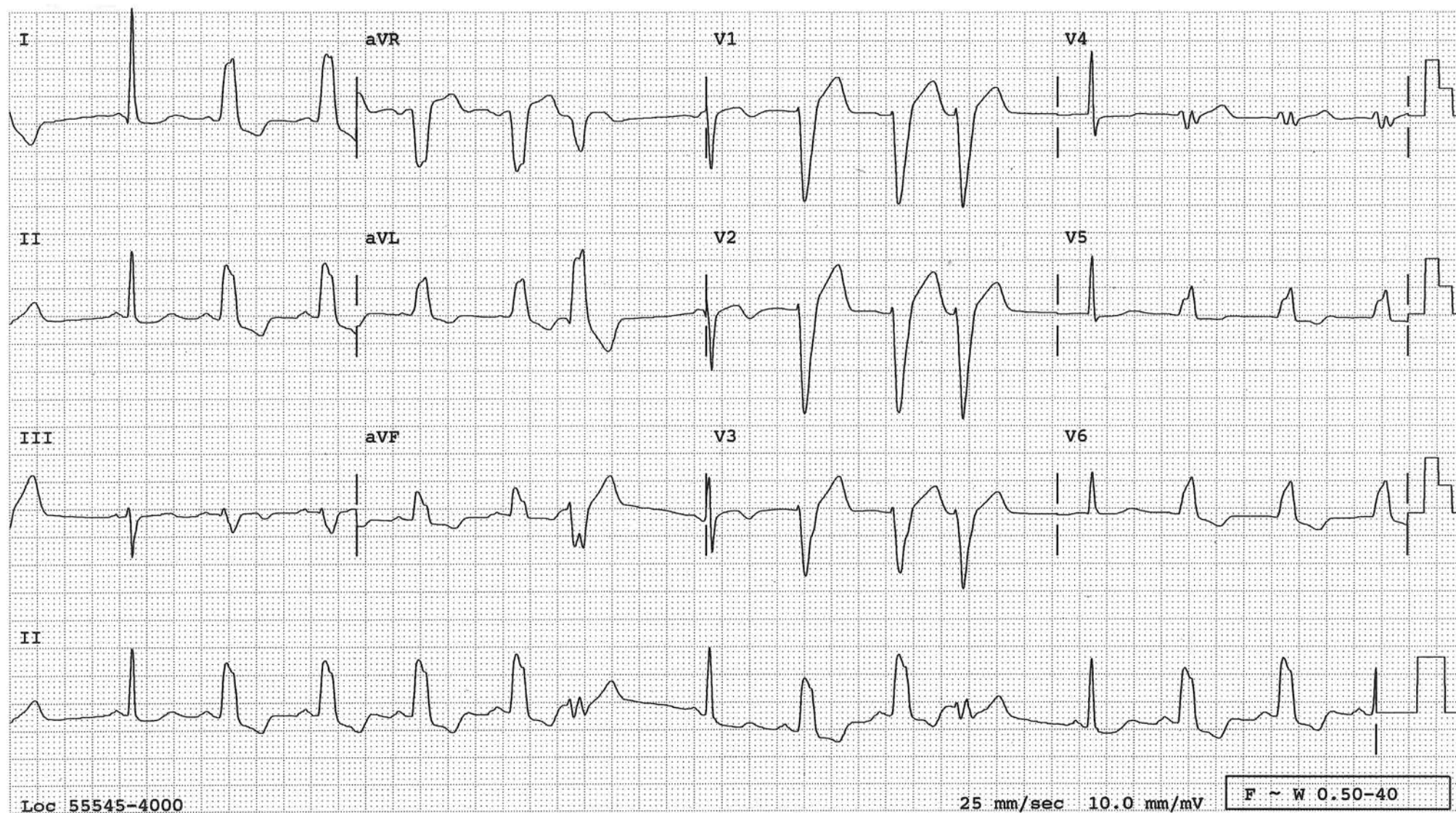
The tracing below nicely illustrates the usefulness of VPBs in ECG interpretation. As far as the timing is concerned, the waves indicated by  $\uparrow$  could pass as U waves. They could also be the P waves with 1° AV block, or they could be both together. The issue could not be settled if it weren't for the VPBs. In the rhythm strip of lead II, the wave during the compensatory pause following each VPB is too far out from the VPC to be a U wave. Therefore, it is a P wave with a prolonged PR interval. As luck would have it, the P wave is isoelectric in V3. Therefore, the wave ( $\downarrow$ ) in front of the second QRS in V3 is not a P wave and is a U wave. Now, one can conclude that the patient is in normal sinus rhythm with 1° AV block and there are prominent U waves. Without the VPBs, one could not have reached this conclusion. What is the importance of sorting these out? Prominent U waves may be due to severe hypokalemia, which could precipitate life-threatening arrhythmias during the induction of anesthesia. 1° AV block may be the first sign of paravalvular abscess if this is a patient with an aortic valve endocarditis. If the waves are only U waves, then the rhythm is accelerated junctional rhythm, in which case one has to look for digitalis intoxication, myocardial ischemia or infarction, or excess amount of catecholamines circulating which means any stressful condition.





### Rate-Dependent LBBB

LBBB is evident. The pause from a VPB is long enough for the left bundle branch to recover from the refractory period and the impulse is conducted normally. This proves that the LBBB in this patient is not permanent but rate dependent. At times, this normalized QRS may reveal very important information which otherwise is masked by the LBBB.



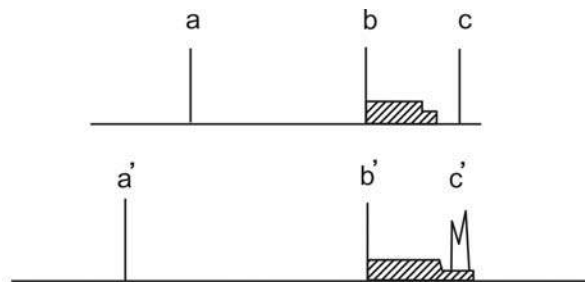


## Aberrant Conduction

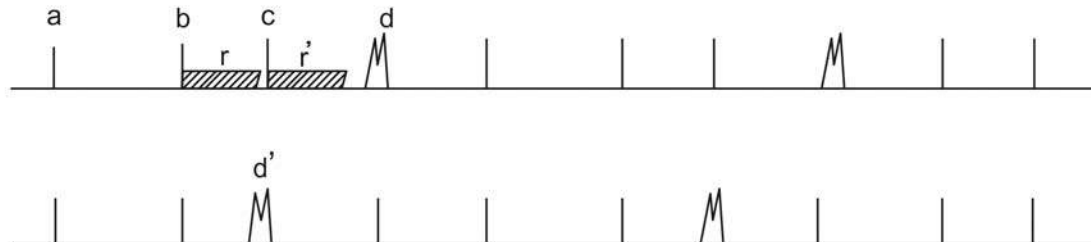
Aberrant conduction results simply because the right and left bundle branches (BB) have different length of refractory period (see page 112). If a supraventricular impulse reaches the ventricles when one bundle branch is still refractory while the other bundle branch has recovered from the refractory period, it will result in a different looking QRS (aberrant conduction). Usually it is the right BB which has the longer refractory period, which is the reason why an aberrantly conducted QRS will more often result in a right BB block pattern. But in other patients or in the same patient at other times, it may be the left BB that has the longer refractory period, and an aberrant conduction manifests in a left BB block pattern.

The length of the refractory period is proportionally related to the preceding R-R cycle length. Therefore, the beat which follows a longer R-R cycle is more likely to be aberrantly conducted because it has the increased chance of landing on the refractory period which now has lengthened (Ashman's Phenomenon). In diagram A, the hatched areas represent the refractory period following the QRSs (b) and (b') respectively. The QRS (c) occurs outside of the refractory period and is normally conducted. The QRS (c') is aberrantly conducted because it lands on the tail end of the refractory period which is lengthened due to the longer preceding R-R cycle (a'-b'). In diagram B, the complex (c) is conducted normally, indicating that the refractory period from the complex (b) (r) had ended when complex (c) occurred. The length of the refractory period from the complex (c) (r') should be shorter than that of r since a-b is longer than b-c. Since one does not know how short it should be, make r' equally as long as r and say that it cannot be longer than that. The complex (d) falls clearly outside of r', i.e., the complex (d) is occurring at a time when all the conduction system has recovered. Therefore, it has no reason to be aberrantly conducted and it is a VPB. Thus, a wide complex terminating a normally conducted short-long cycle is diagnostic of a ventricular premature beat. A wide complex terminating a long-short cycle length (d') is not helpful in this regard.

A

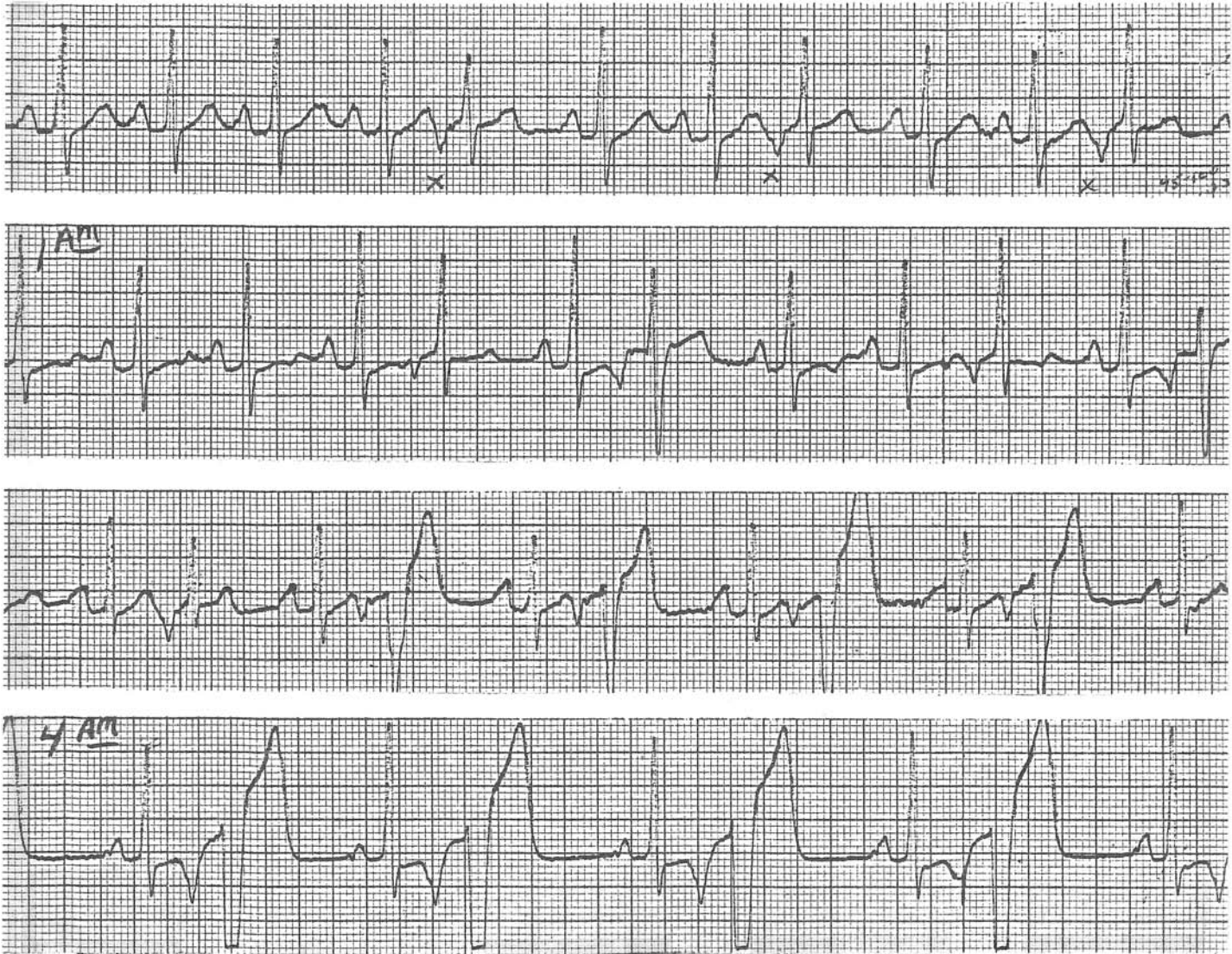

B



## Varying Degrees of Aberrancy

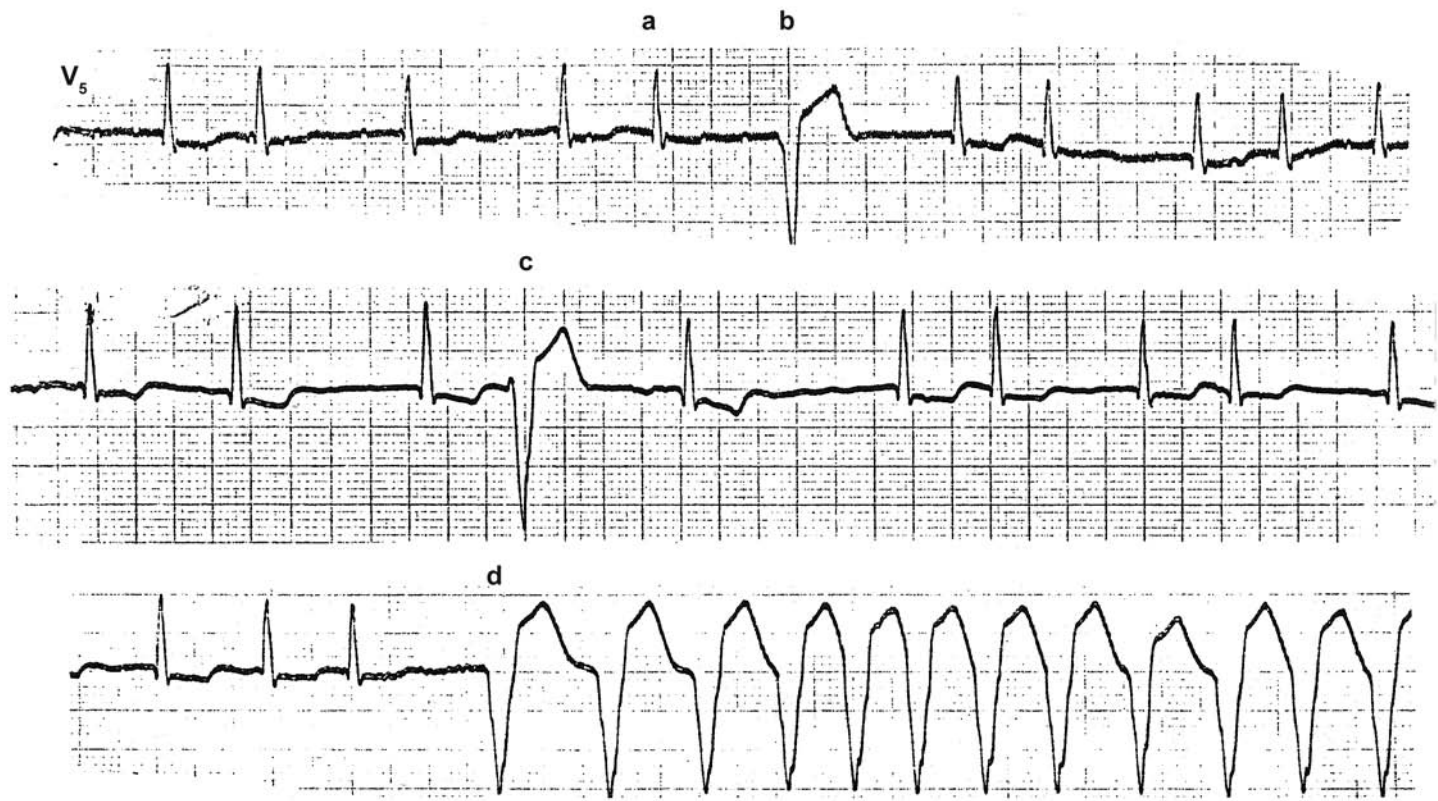
II



The patient is in normal sinus rhythm with frequent APBs (x). In the top strip, these APBs are nearly normally conducted. In the second tracing, the APBs following a longer R-R cycle are aberrantly conducted. In the third strip, the degree of aberrancy is more marked. The last strip reveals atrial bigeminy with an even more marked degree of aberrancy, simulating ventricular bigeminy. These tracings illustrate that a patient can have varying degrees of aberrancy.



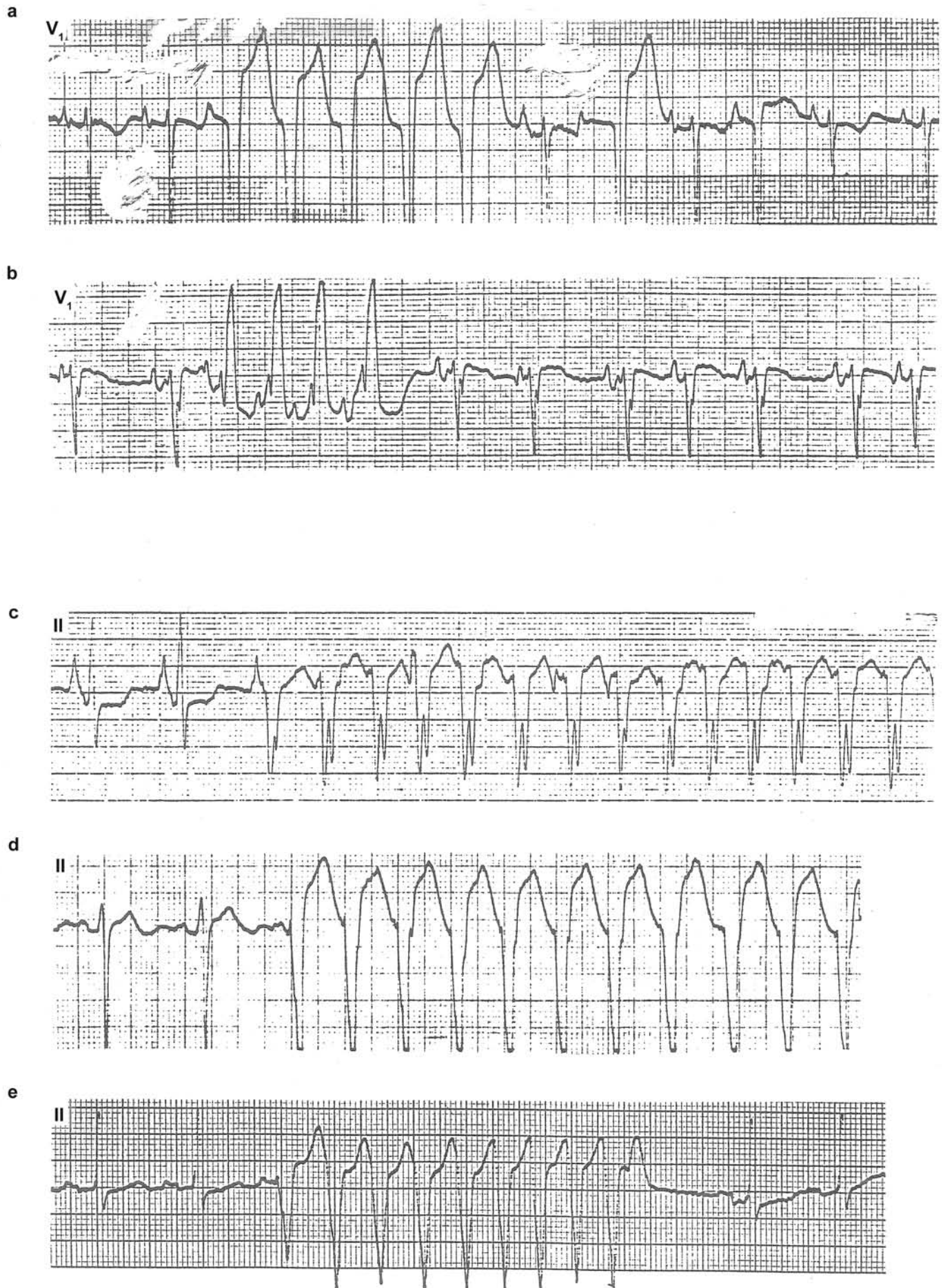
## Aberrancy or VT?



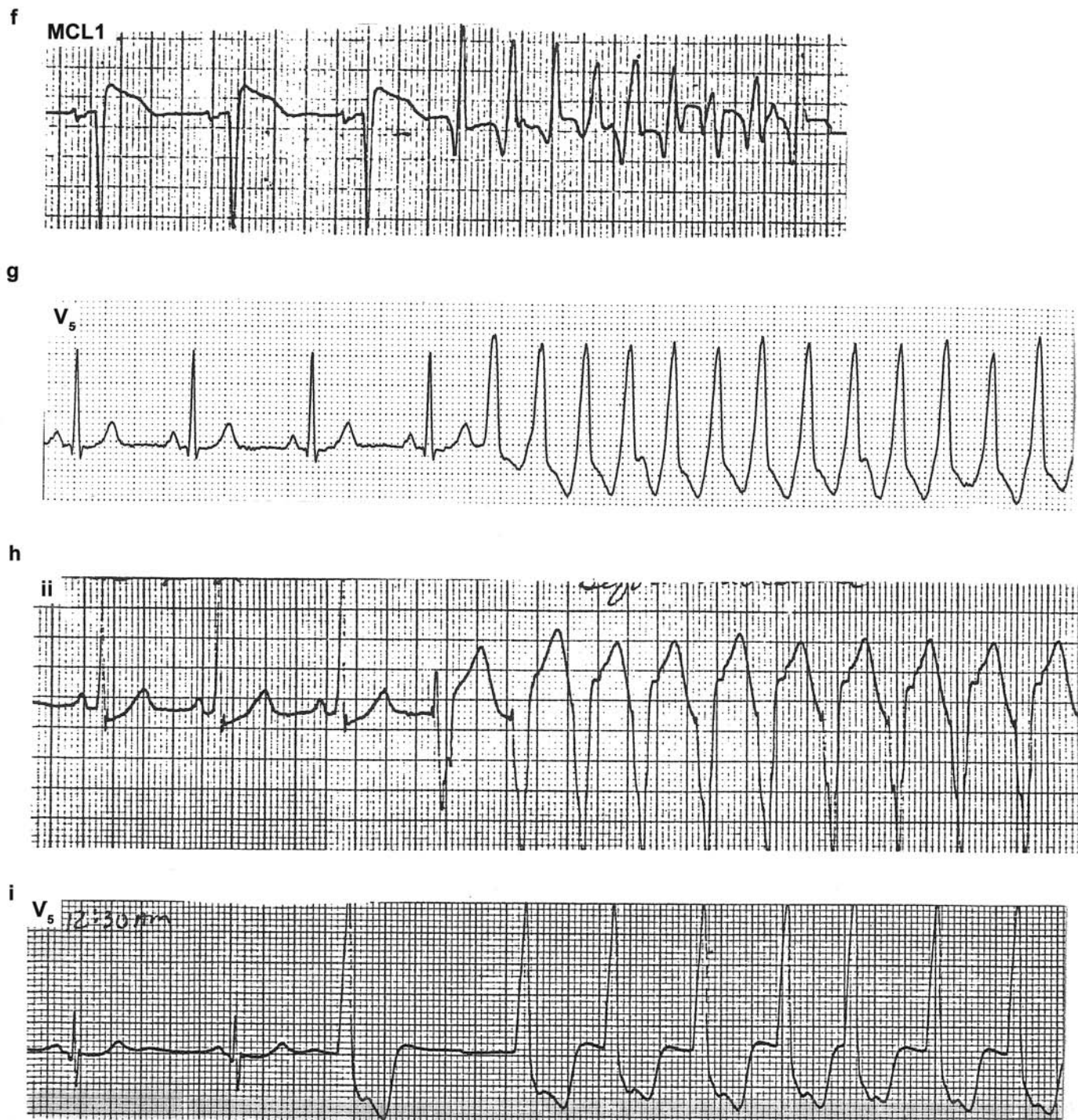
The patient is in atrial fibrillation. The complex (a) is conducted normally, indicating that the refractory period ended before the complex. Since the complex (b) occurs beyond the refractory period and has no reason to be aberrantly conducted, it is a VPB. The same reasoning cannot be applied in analyzing complex (c) in the second strip. In the third strip, the first wide complex (d) is a ventricular complex, by the same reasoning as with the complex (b), and the tracing reveals a run of ventricular tachycardia. Note that the rhythm is not exactly regular. It is not unusual for ventricular tachycardia to be this much irregular.



**Aberrancy or VT?**  
(See the legend on the next page)



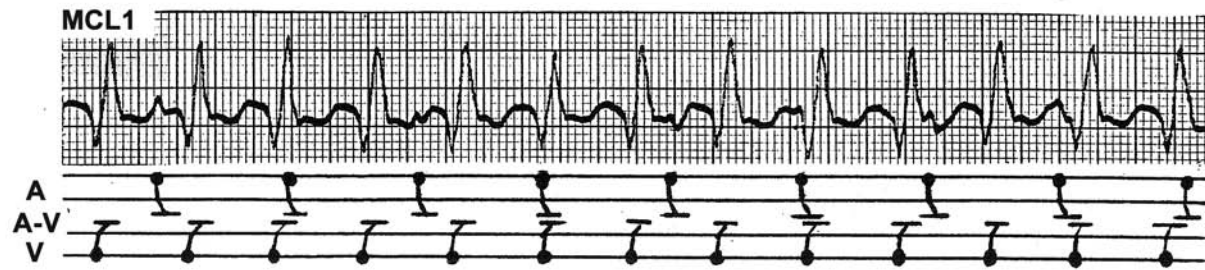




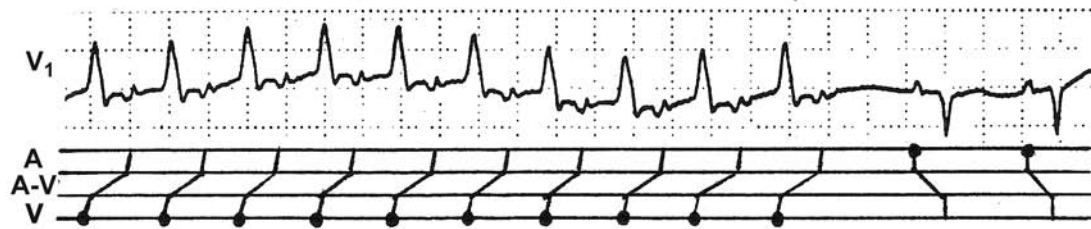
A wide complex tachycardia is either supraventricular tachycardia with aberrant conduction or ventricular tachycardia. Often, it is not easy to distinguish one from the other. However, if the patient is in sinus rhythm and one catches the beginning of the tachycardia, there is little difficulty in distinguishing which one it is. When the run of wide complex tachycardia is preceded by a premature P wave (often the P wave has a different morphology), then it is SVT with aberrant conduction (a and b). If the wide complex tachycardia is preceded by a regularly (not prematurely) occurring sinus P wave (the PR interval is shorter than that of normally conducted sinus beats), it is ventricular tachycardia (c, d, and e). If the wide complex tachycardia is not preceded by a P wave, it is ventricular tachycardia (f, g, h, and i).

## Ventricular Tachycardias with:

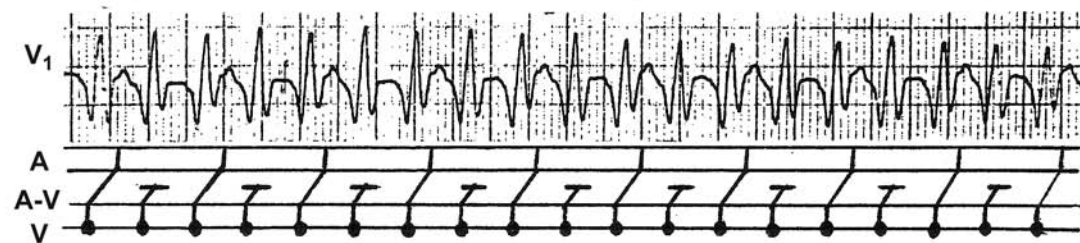
### Complete AV dissociation



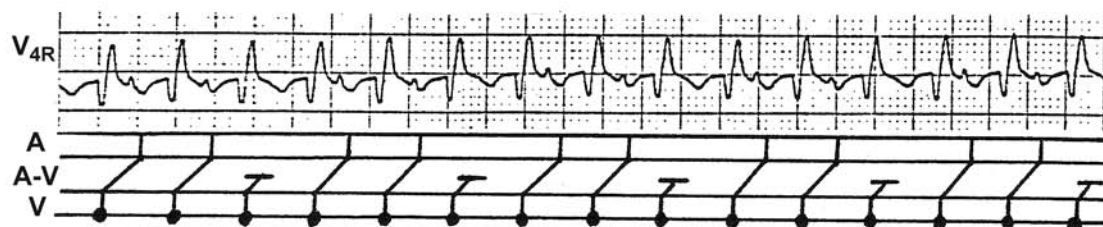
### 1:1 Retrograde VA conduction



### 2:1 Retrograde VA conduction

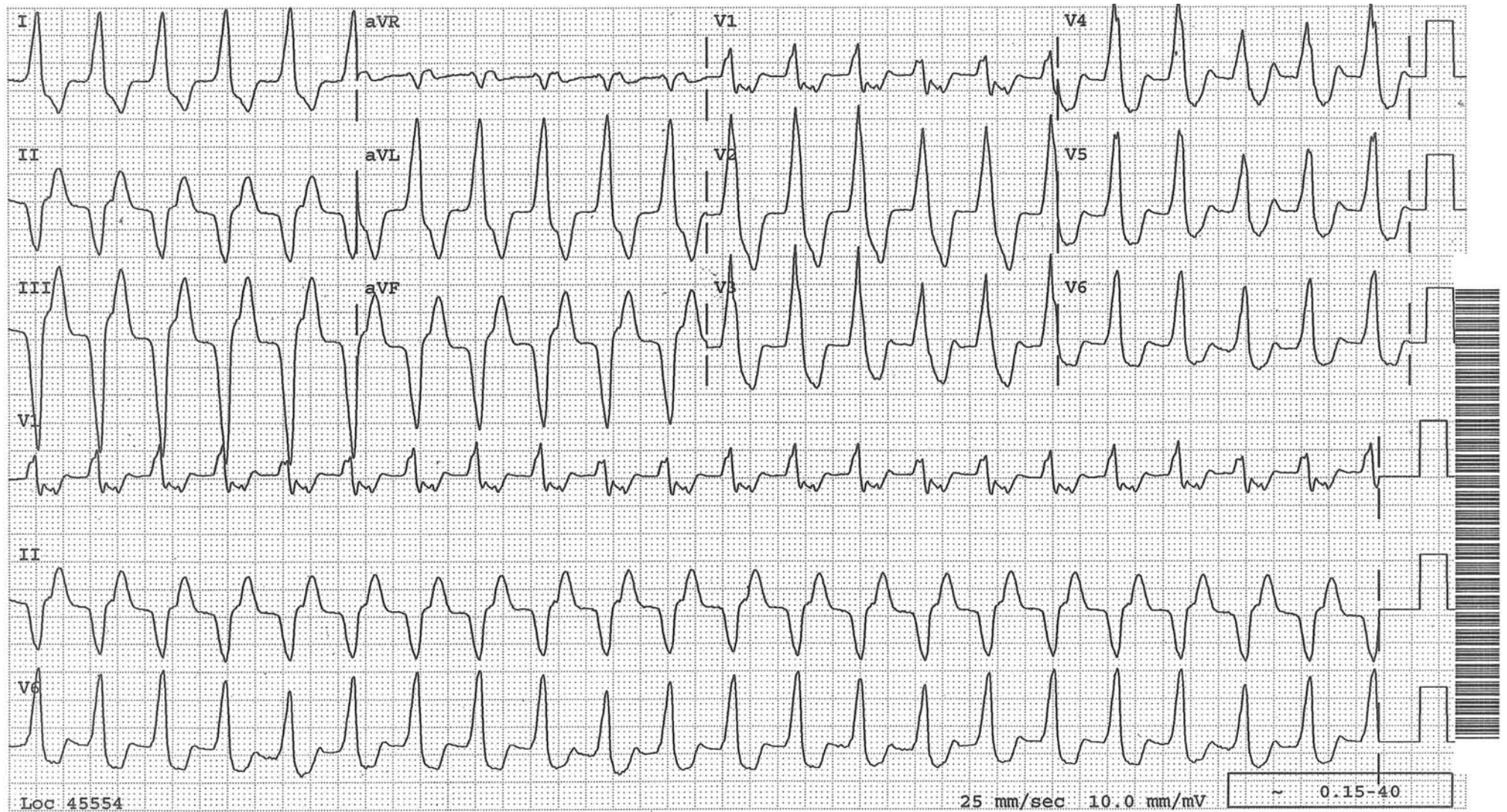


### 3:2 Retrograde VA Wenckebach phenomenon



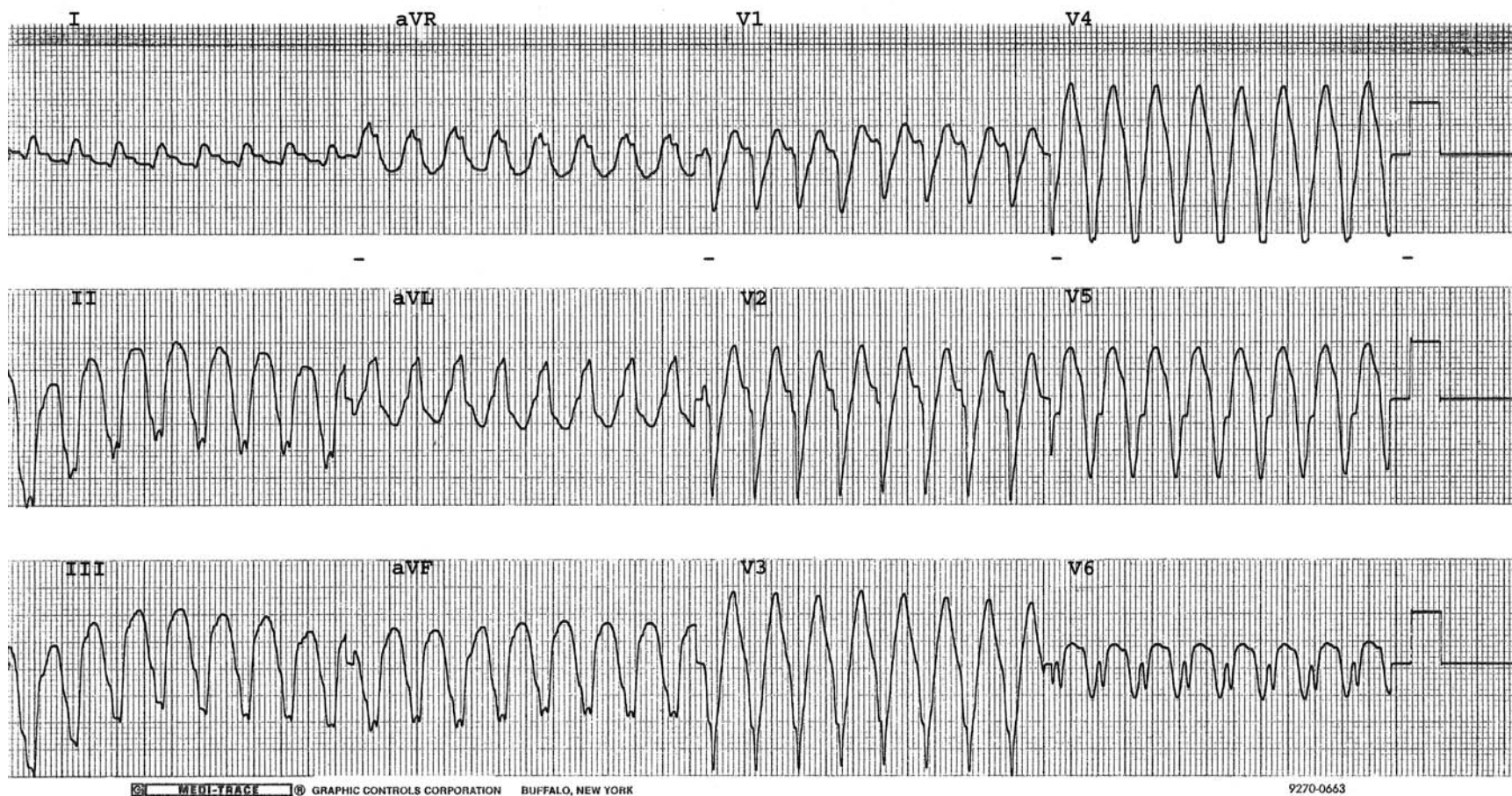


Wide QRS tachycardia at 130/min. There is a positive concordance of the QRSs in the precordial leads (all QRSs in the precordial leads are predominantly positive), which is highly diagnostic of ventricular tachycardia.



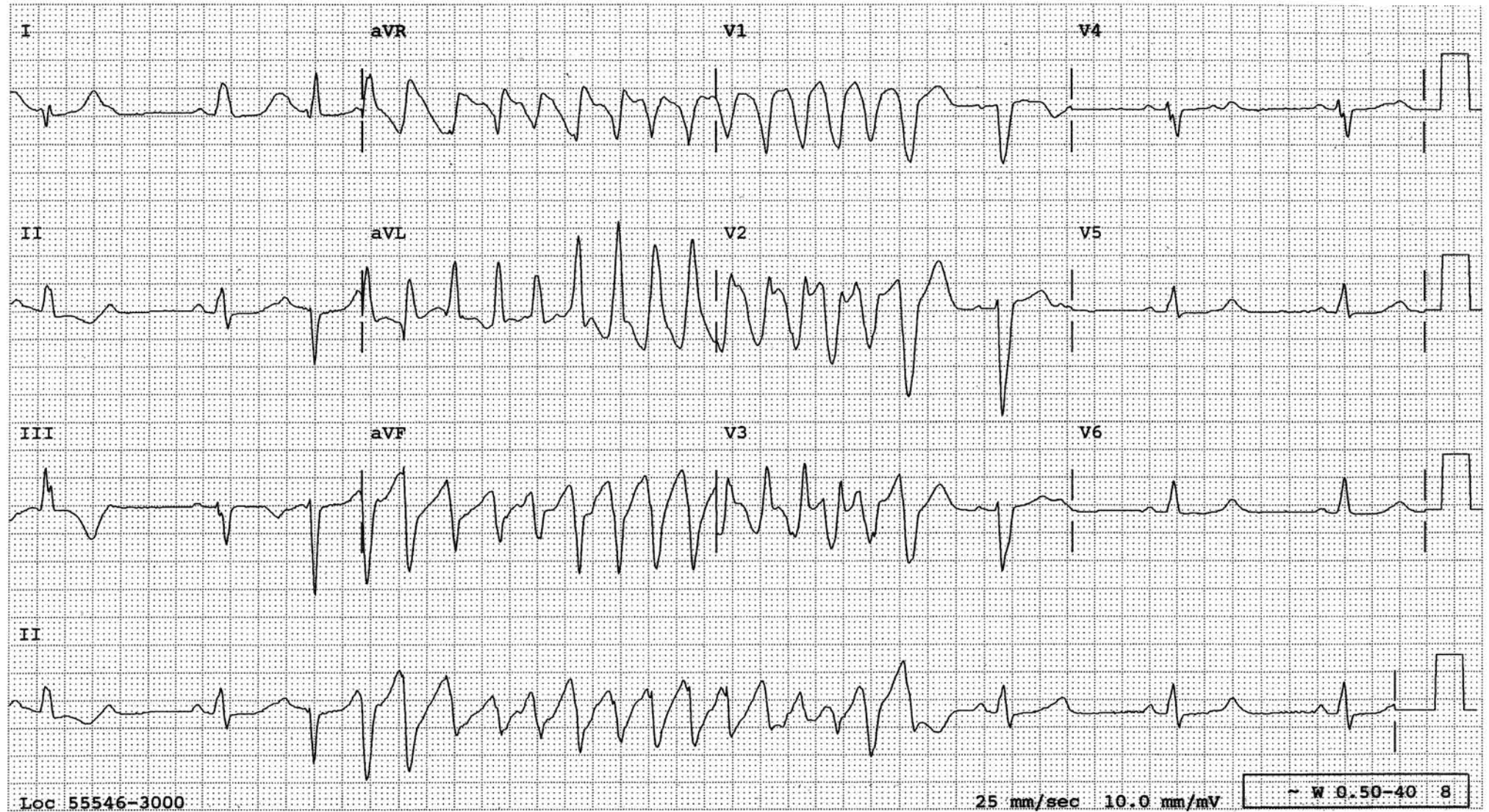


A wide complex tachycardia is present. There is a concordance of the QRS in the precordial leads (all the QRSs in the precordial leads are basically QS pattern throughout). This is highly diagnostic of ventricular tachycardia.



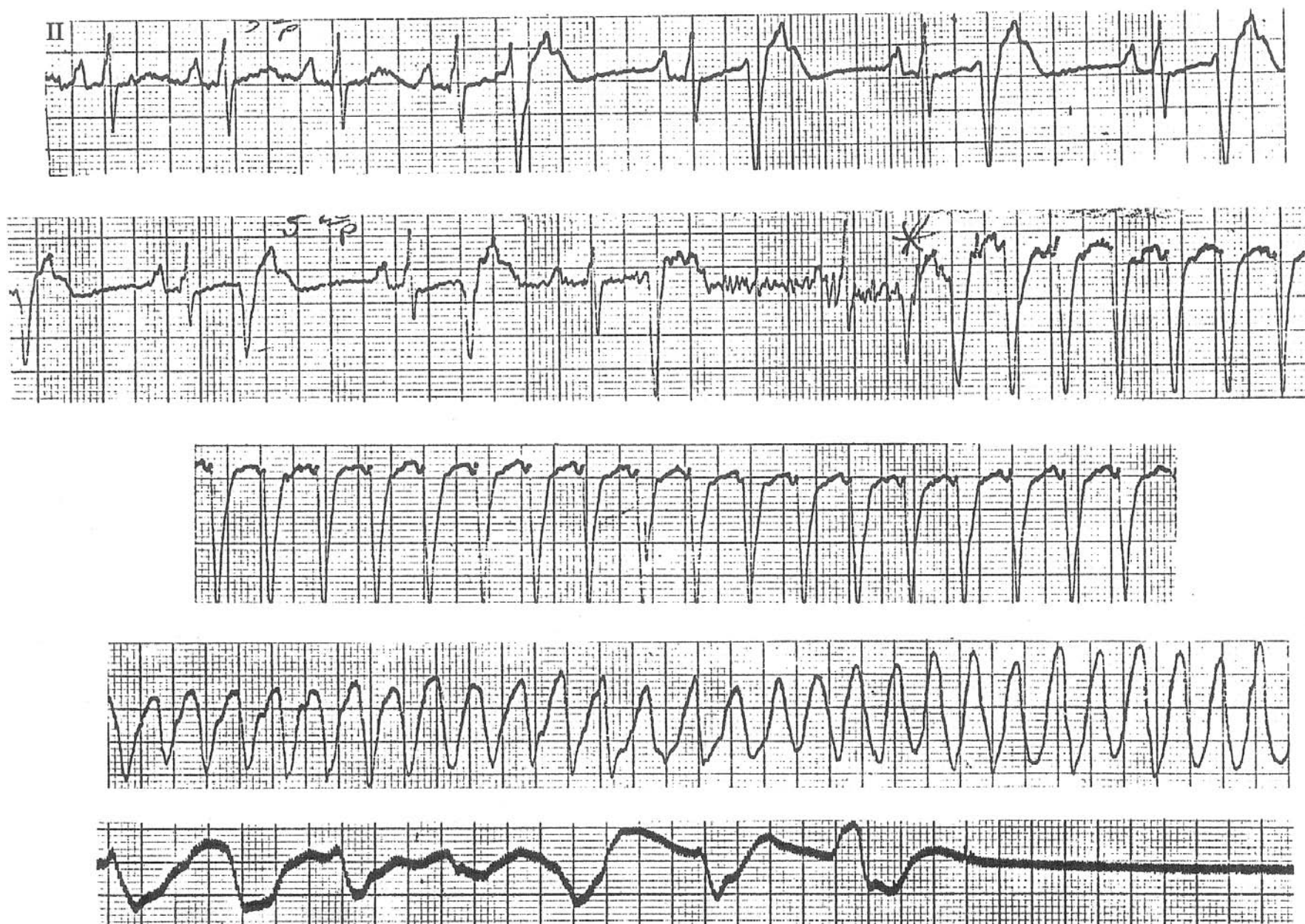


# Torsade de pointes with long QT interval as a proarrhythmic effect from Sotalol





## PVCs Progressing to a Cardiac Arrest



Multiple VPBs are present in the upper tracing. In the second strip, one of these VPBs initiates ventricular tachycardia which degenerates into ventricular flutter, ventricular fibrillation, and asystole.

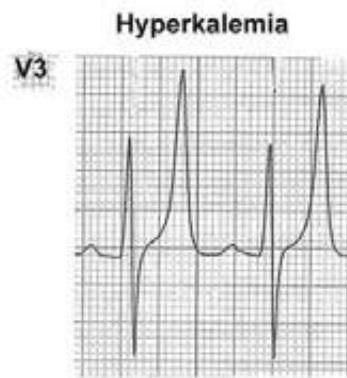
# Electrolyte Problems

## Hyperkalemia

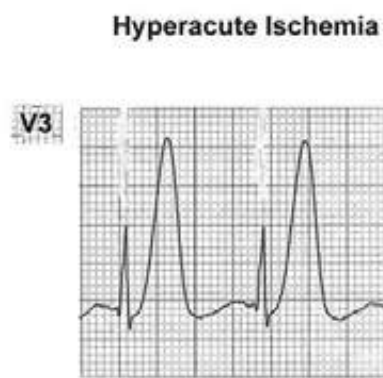
### ECG Features:

- Tall, peaked, narrow, tented T waves as if pinched from above
- Widened QRS
- Intra-atrial block
- Prolonged PR interval
- Low or absent P waves

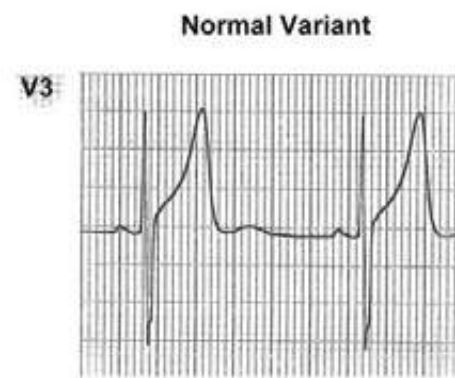
## Different Causes of Tall T Waves



Symmetric, narrow, pointed, tented,  
“pinched from above”



Symmetric, broad-based, not tented,  
not pointed. QT interval tends to be  
long (not in this example)

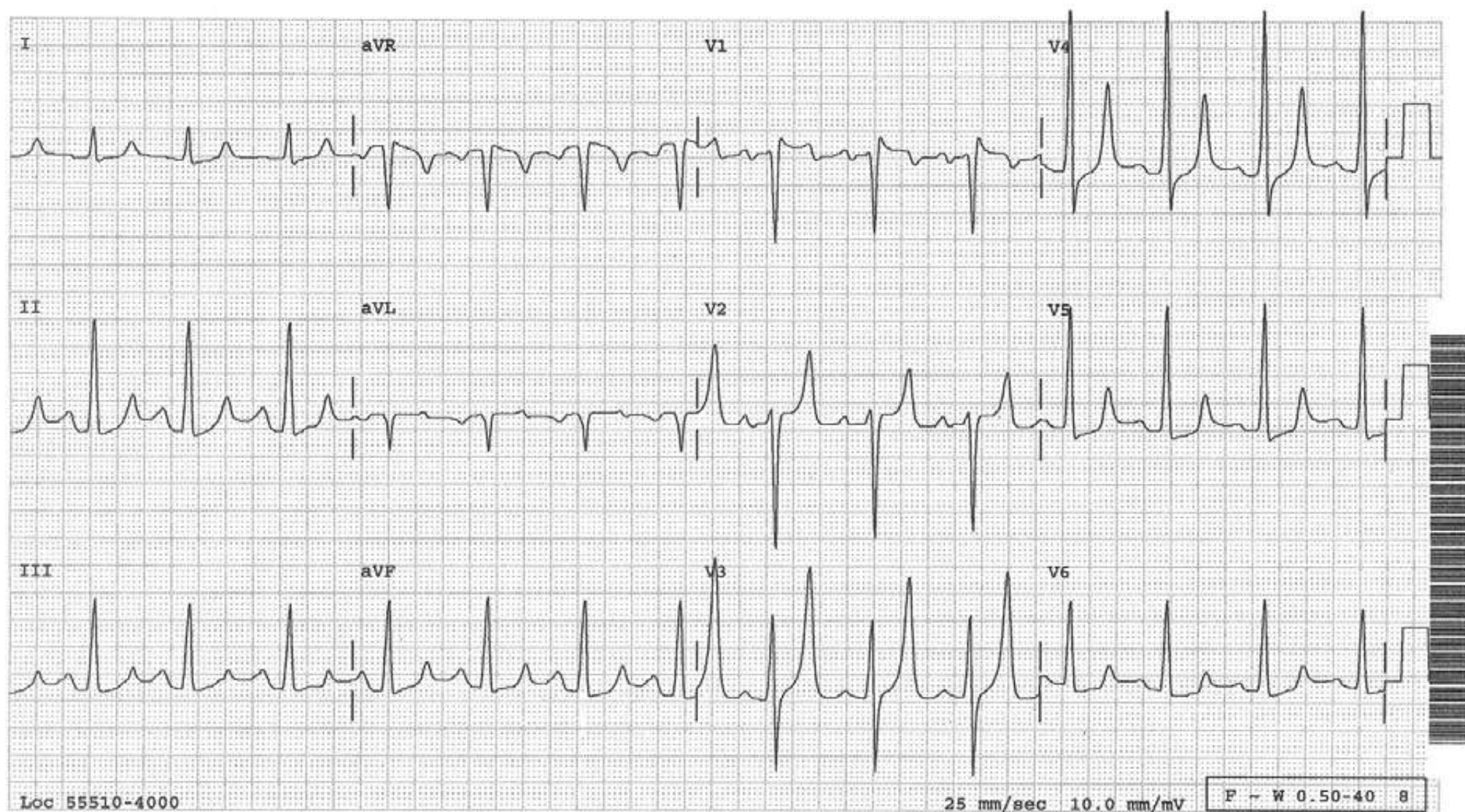


Asymmetric and not narrow



## Hyperkalemia

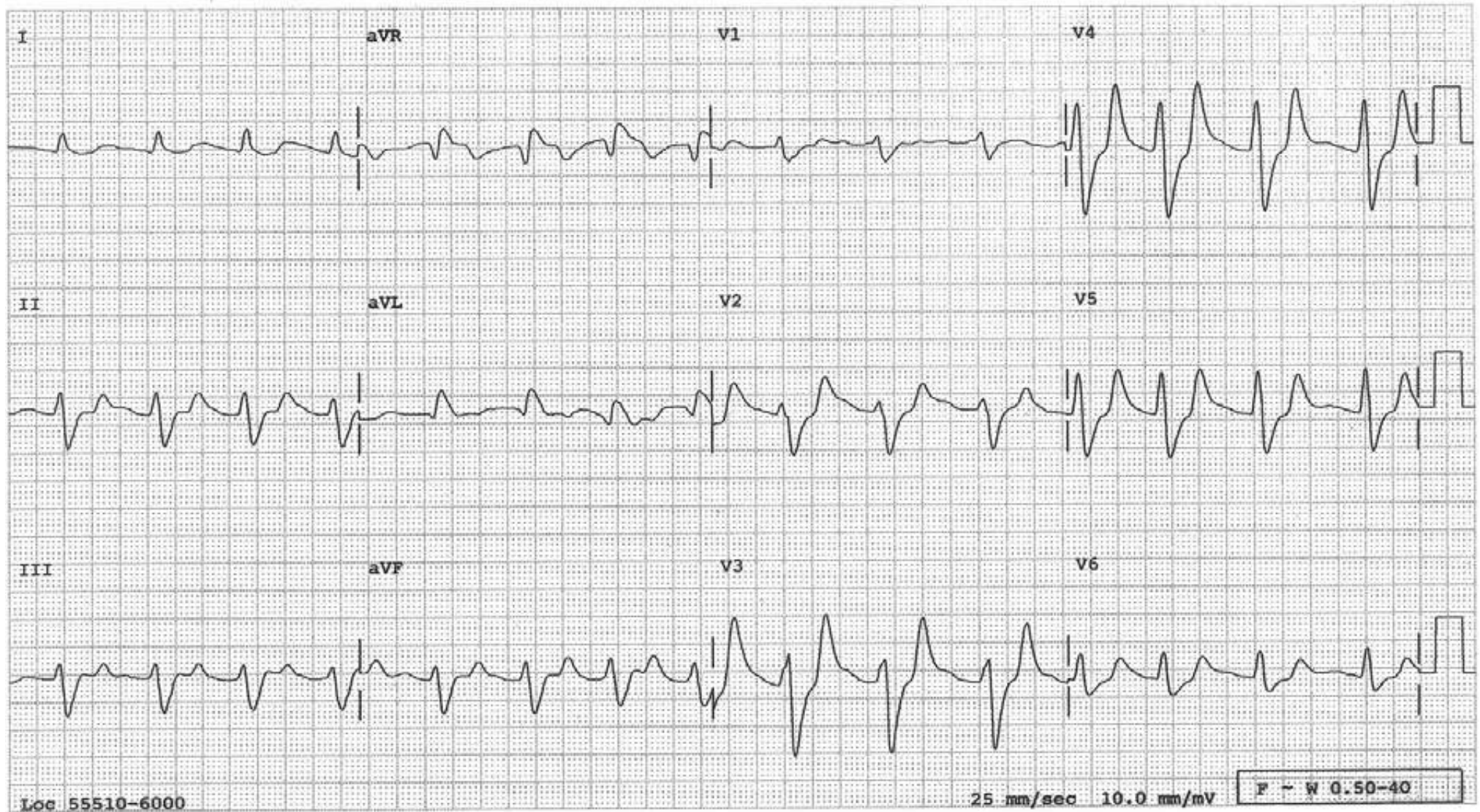
A typical example of hyperkalemia manifested by tall, narrow, pointed and “tenting” T waves which are symmetric.





## Hyperkalemia

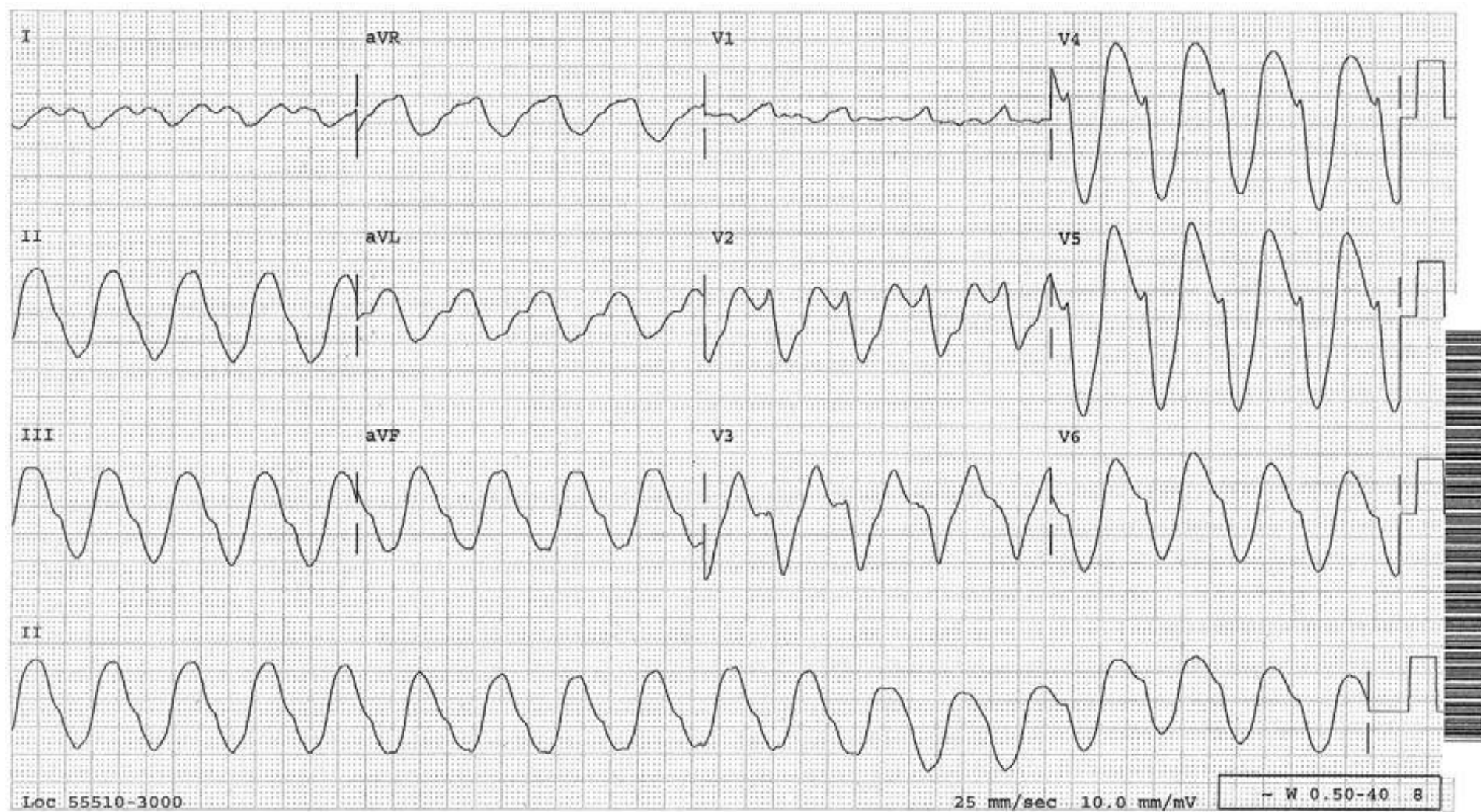
Wide QRSs, low amplitude P waves and tall, pointed T waves (see V3 and V4 especially) are all characteristic of hyperkalemia.





## Hyperkalemia

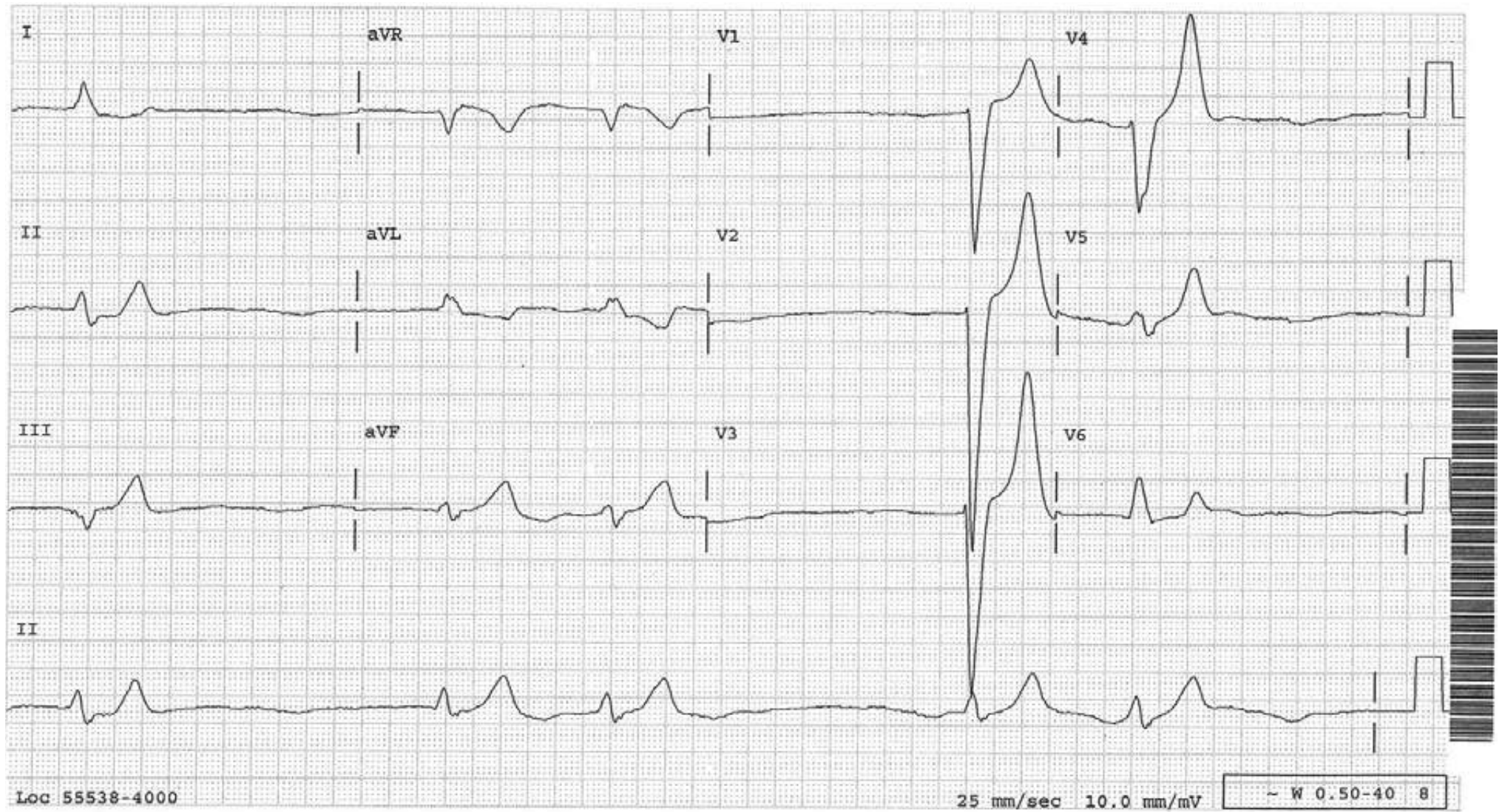
Widened QRSs merging into ST segments are on the verge of becoming sine waves.





## Hyperkalemia

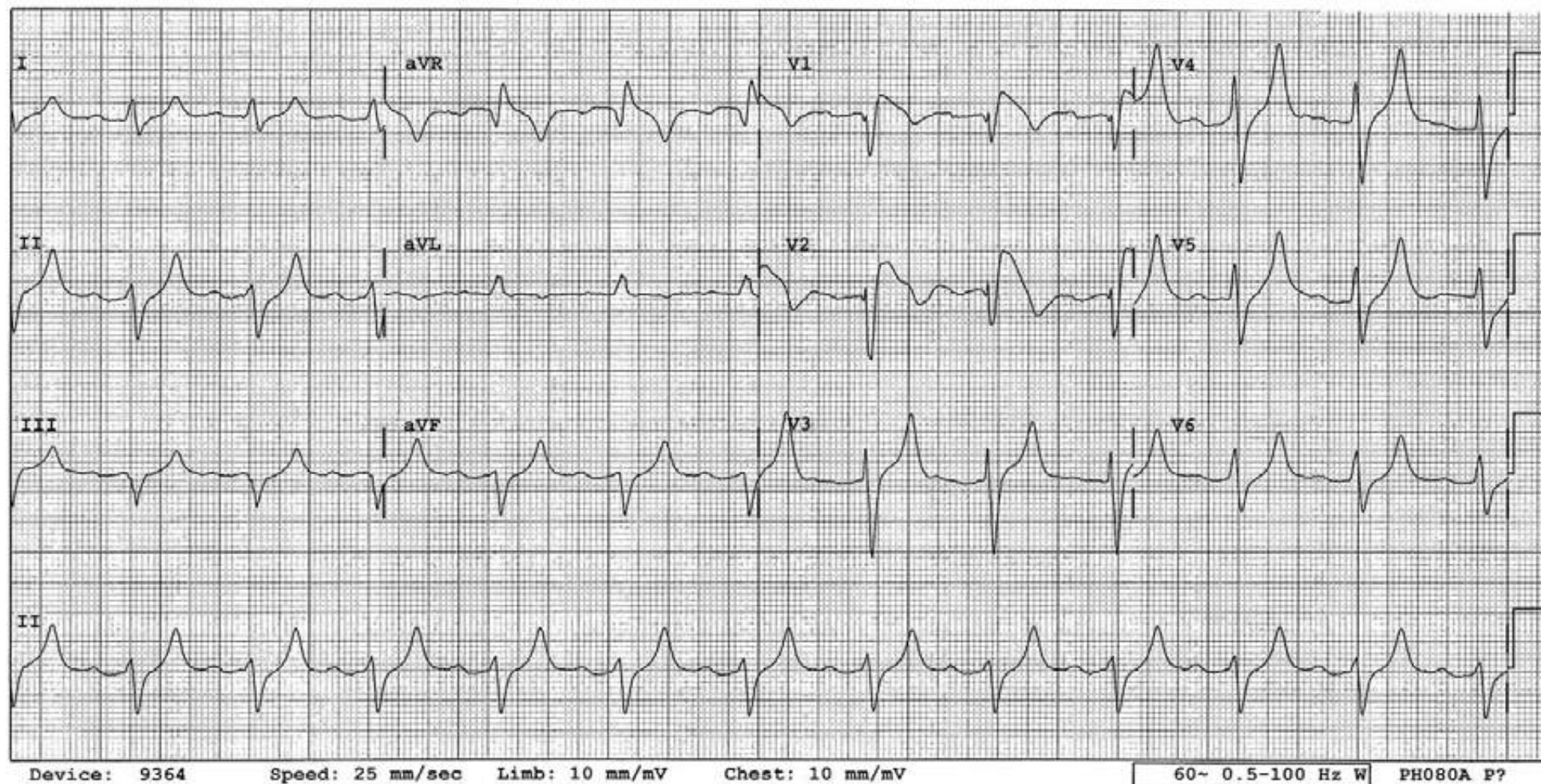
Slow and irregular rhythm, wide QRS complexes, tall and pointed T waves and absence of P waves are all strongly suggestive of hyperkalemia. This patient has chronic renal failure, is taking Lisinopril and the serum potassium is 7.9.





## Acquired Brugada ECG Pattern from Hyperkalemia

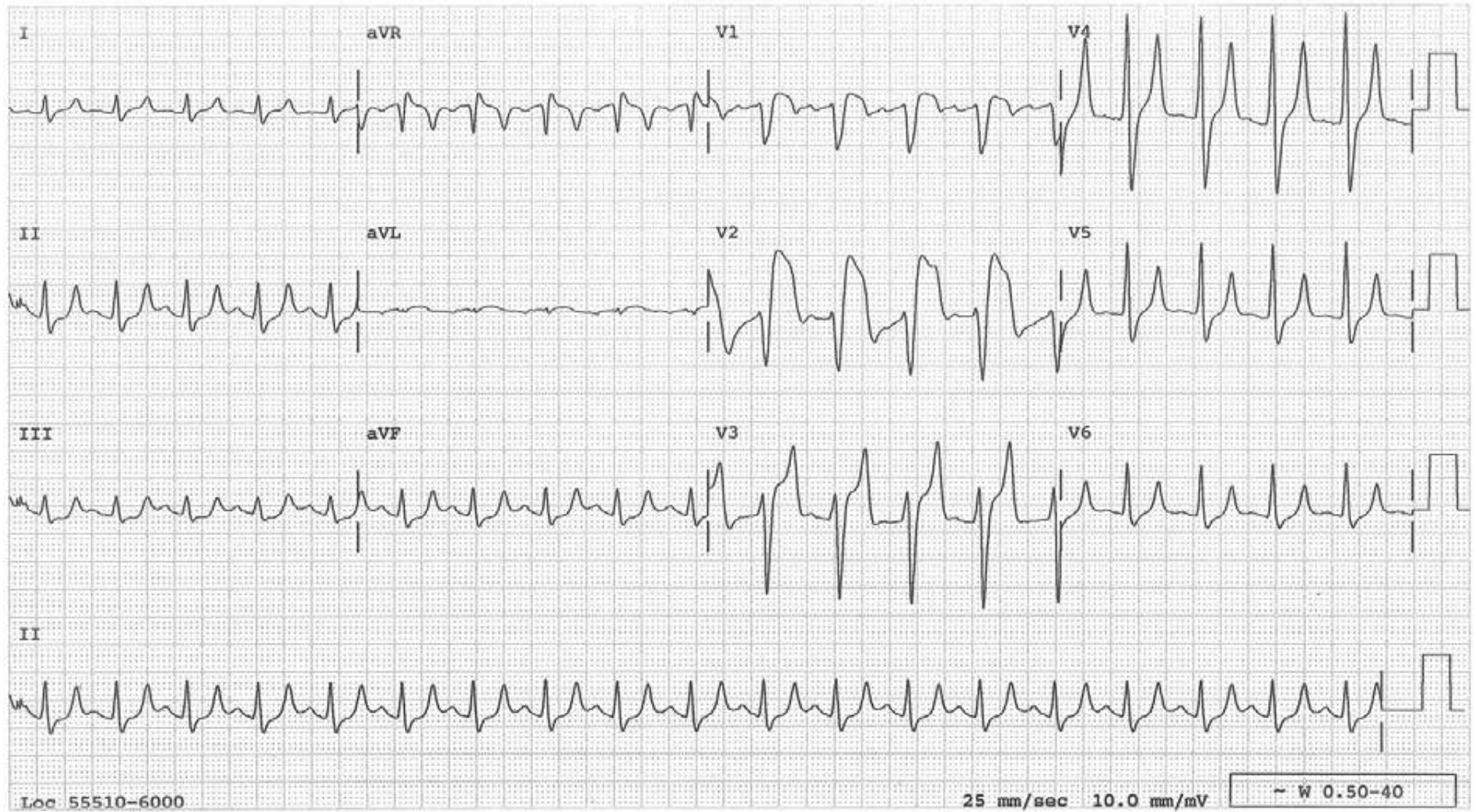
A typical Brugada ECG pattern in  $V_{1-2}$  is present (ST segment begins from the top of the R' and is down sloping, ending in the inverted T wave). QRSs are wide and T waves are tall, symmetric and tented in other leads, especially in  $V_4$ . These are all features of hyperkalemia, which is what this patient has. Anything that disables sodium channel, such as hyperkalemia, fever or cocaine, can cause acquired Brugada ECG pattern at times as in this case.





### “Pseudoinfarction” Pattern from Hyperkalemia

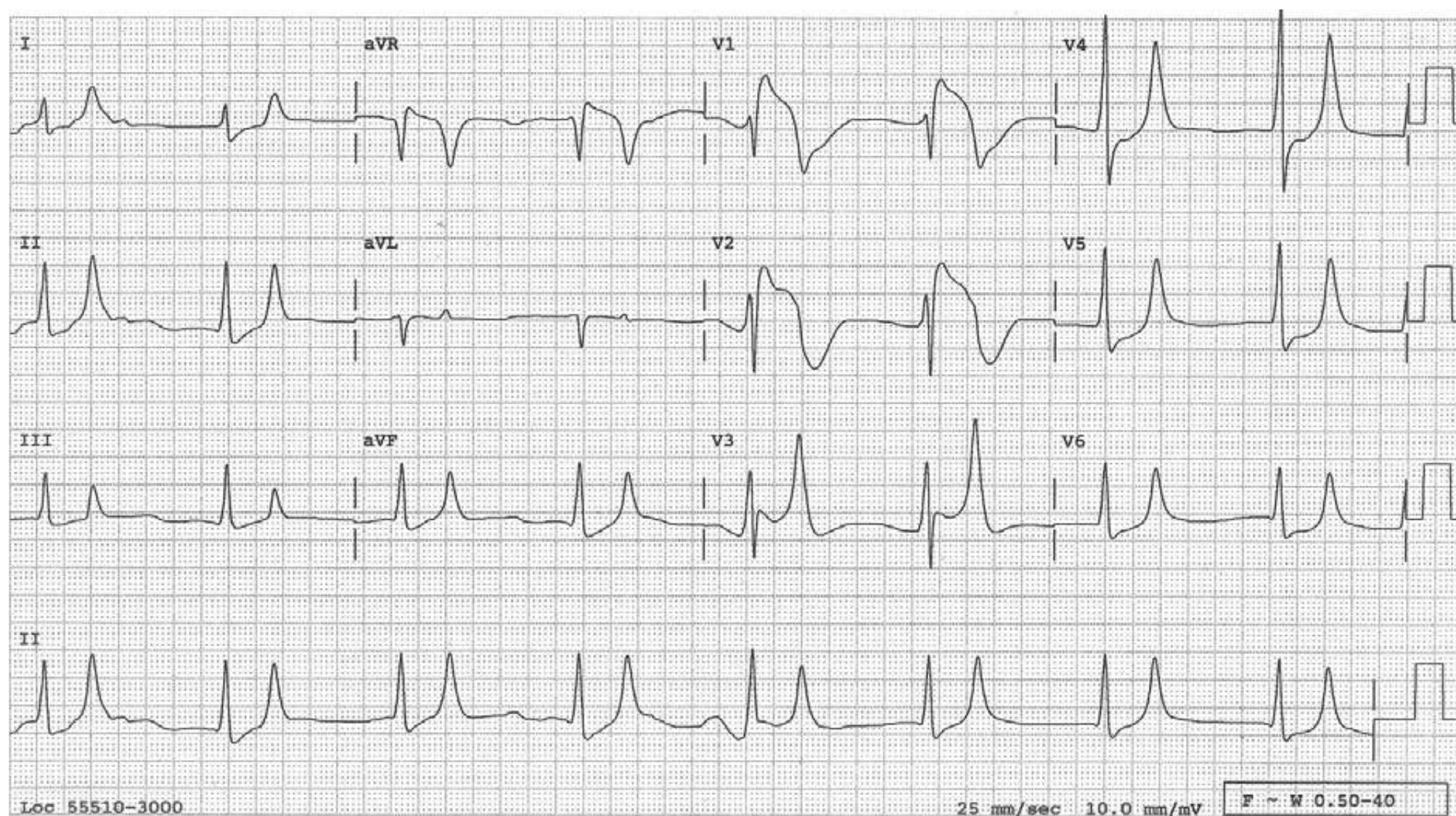
There is a 10 mm injury-pattern ST elevation in lead V2, highly suggestive of acute anteroseptal infarct. This tracing is from a patient during hyperkalemia (serum K: 7.9 mEq/L). A clue to the correct diagnosis is the T wave in lead V4 which is tall, narrow, and tented and is associated with a short QT interval. The tall T waves of hyperacute ischemic changes are not narrow and tented and are associated with a long QT interval (The findings in V<sub>1-2</sub> can be considered as an acquired Brugada ECG pattern).





## Hyperkalemia Causing Pseudoinfarction Pattern in Leads V<sub>1-2</sub>

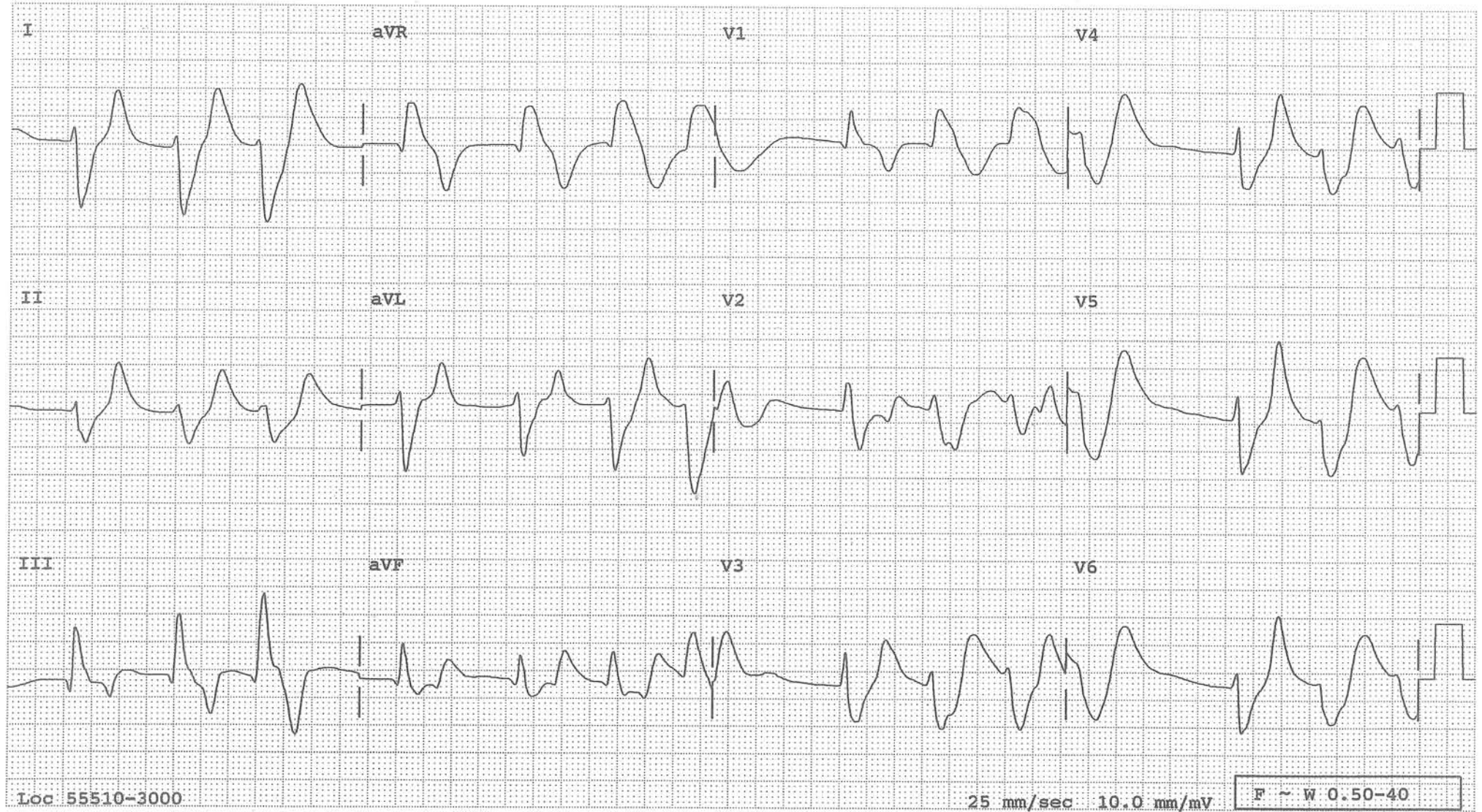
Note other features of hyperkalemia, including disappearance of P waves, widened QRSs and T waves that are tall, pointed, and narrow (see lead V<sub>3</sub> and V<sub>4</sub> especially). What is the rhythm? A regular wide QRS rhythm at 47/m with no P waves suggests ventricular rhythm, but it is not. With progressive hyperkalemia, the P waves become flatter and flatter and eventually disappear when the atrial myocardium is rendered inexcitable by the hyperkalemia. Yet, the impulse from the sinus node is conducted to the AV node through the specialized internodal tract(s), then to the ventricles. This rhythm is called sino-ventricular rhythm. This situation provides physiological evidence for the presence of the specialized internodal tract(s) even though it has not been identified histologically (The findings in V<sub>1</sub> and V<sub>2</sub> can be considered as an acquired Brugada ECG pattern).





## Hyperkalemia Causing “Pseudoinfarction” Pattern in Lead III

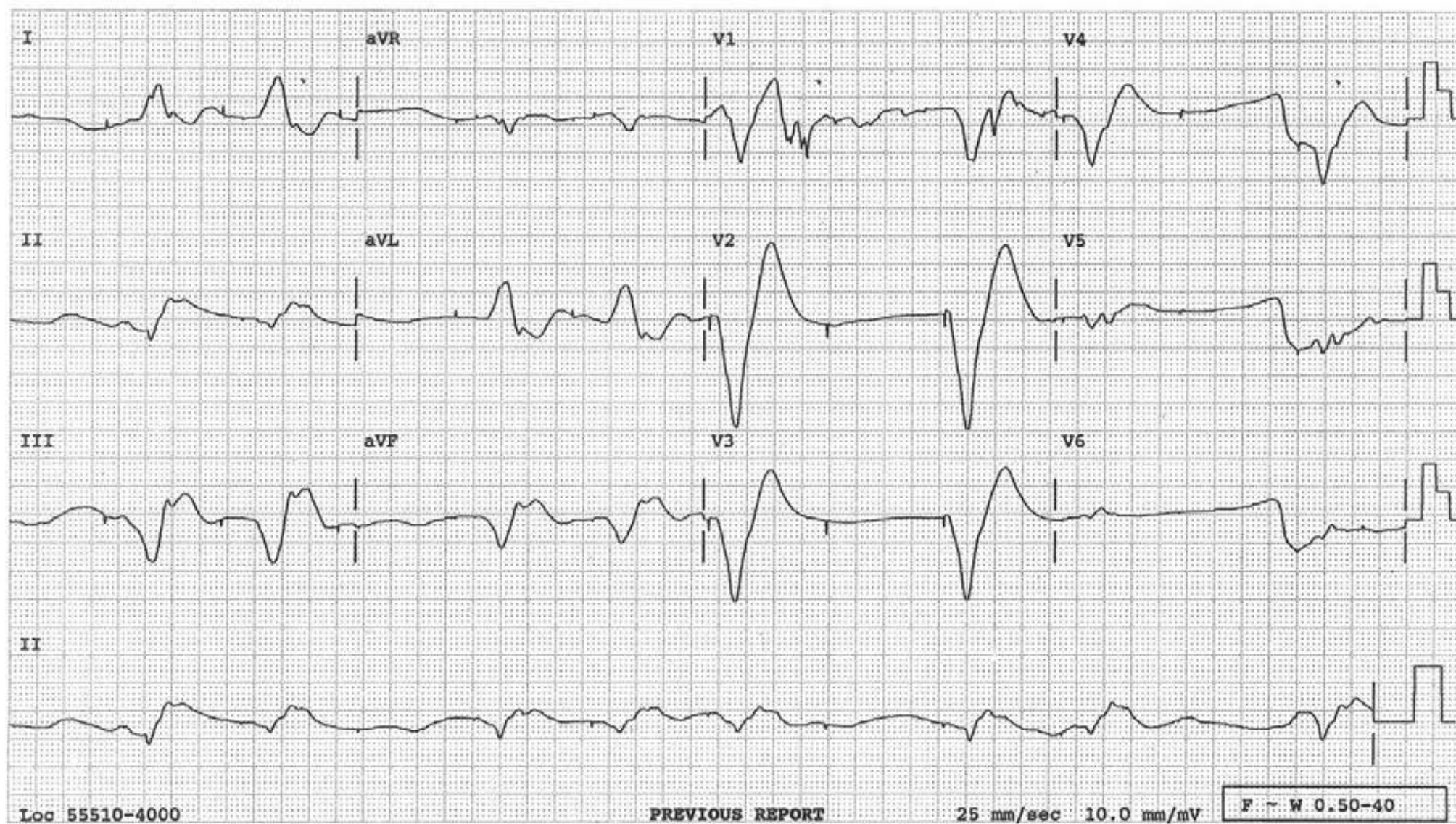
Other features of hyperkalemia include widened QRSs and T waves that are tall, narrow, and pointed (see second complex in lead V<sub>5</sub>).





## Hyperkalemia Causing Pacemaker Failure

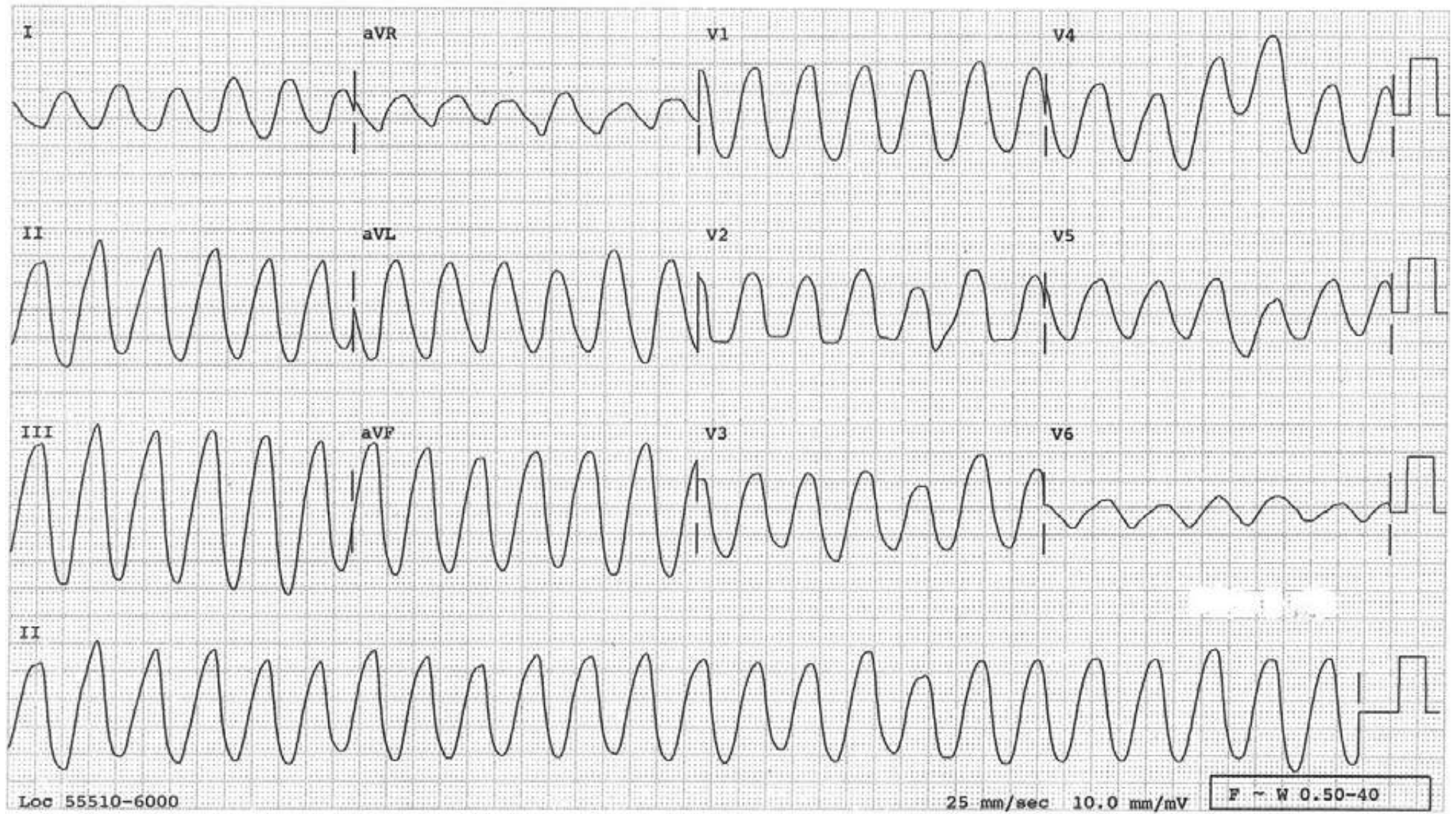
Many pacemaker spikes fail to capture the ventricle because the pacing threshold is increased by hyperkalemia. Other features of hyperkalemia are present, including wide—even for paced—QRSs and tall T waves.





## Hyperkalemia and Acidosis

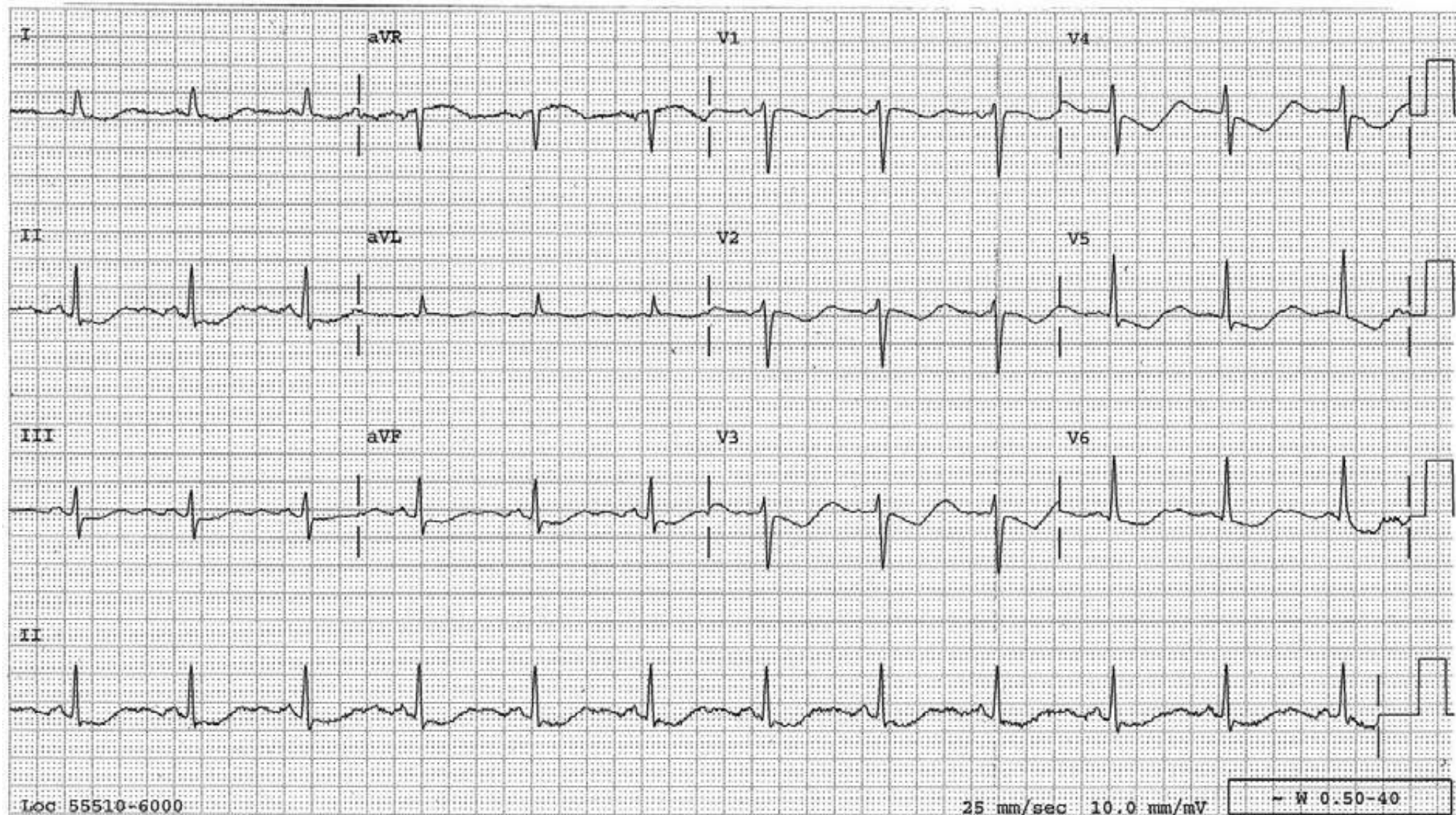
Severe hyperkalemia resulting in sine waves





## Hypokalemia

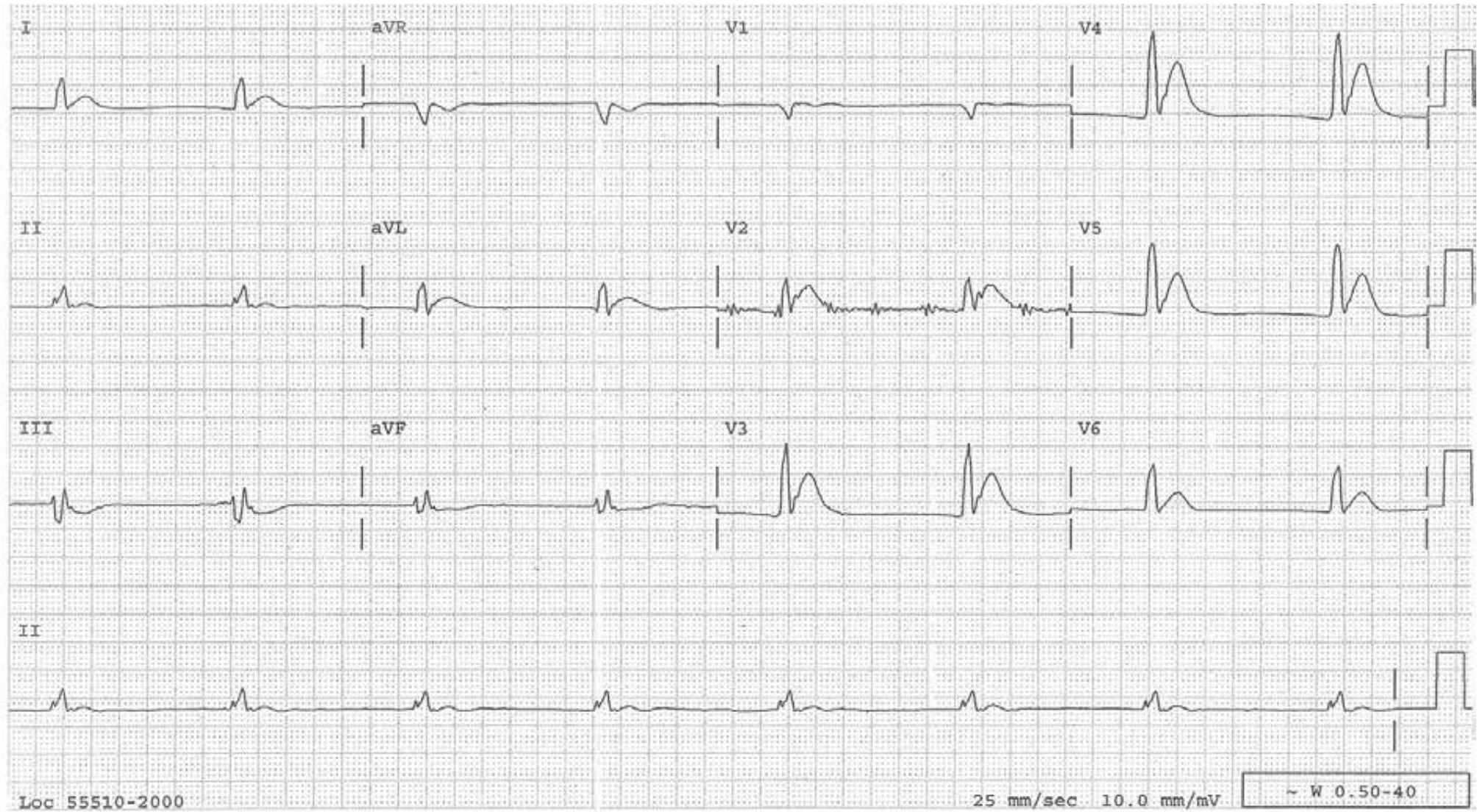
Shallowly inverted T waves and prominent U waves merging into each other to form “lazy” waves with a long QTU interval. The U waves are better recognizable in the inferior leads. The serum K<sup>+</sup> was 1.7 mEq/L at this time.





## Hypercalcemia

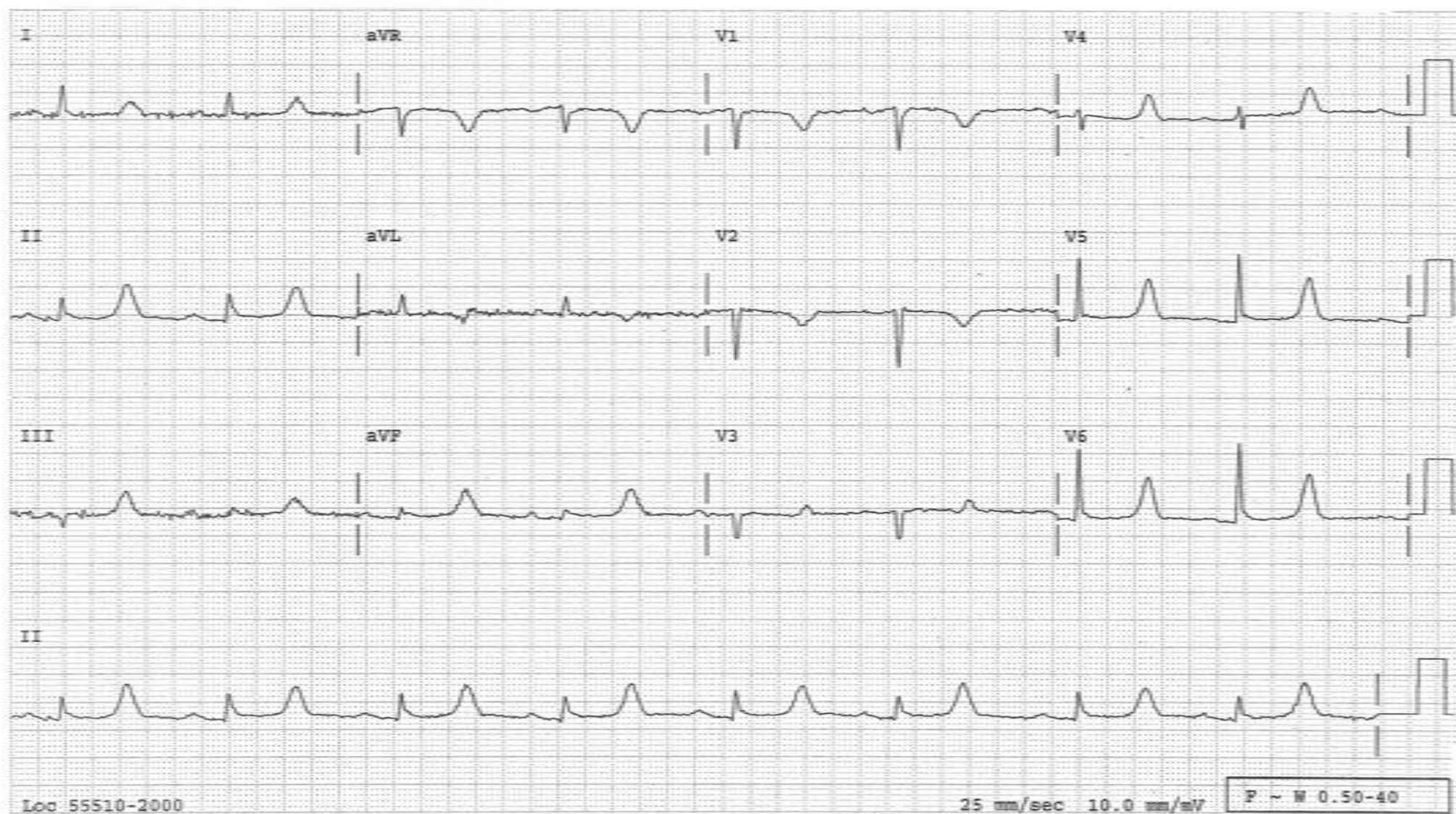
A short QT interval without hardly any ST segment is the ECG feature of hypercalcemia. This tracing also shows intraventricular conduction defect and junctional escape rhythm, which are not part of hypercalcemia.





## Hypocalcemia

A long QT interval made of a long ST-segment with a delayed onset of the T wave. The long QT interval due to hypocalcemia does not predispose to Torsade de points while all other long QT intervals do, supposedly because the QT interval is homogeneously prolonged in hypocalcemia, while it is inhomogeneously prolonged in all other conditions resulting in potential gradient between one area to another of the ventricular myocardium setting up electrical current.

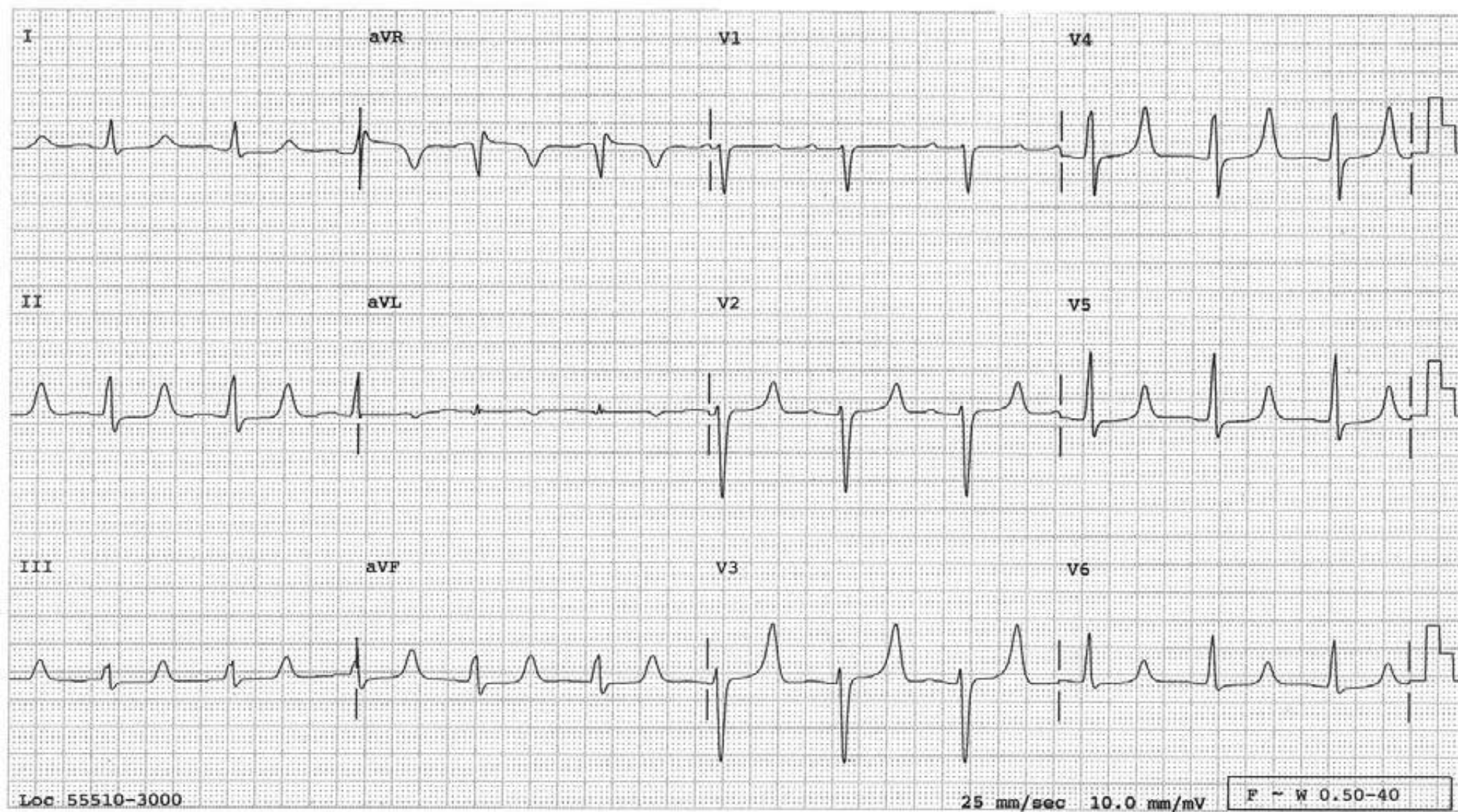




## Hyperkalemia and Hypocalcemia

(This combination is often seen in patients with chronic renal failure.)

The QT interval is obviously prolonged which, in this case, is due to a prolonged ST segment with delayed onset of T waves (leads II, III, aVF, V<sub>4-6</sub>). This is a typical feature of hypocalcemia. The T waves are tall, narrow and pointed, indicating hyperkalemia as well (V<sub>3-4</sub>). (Note: precordial leads are half-standard).

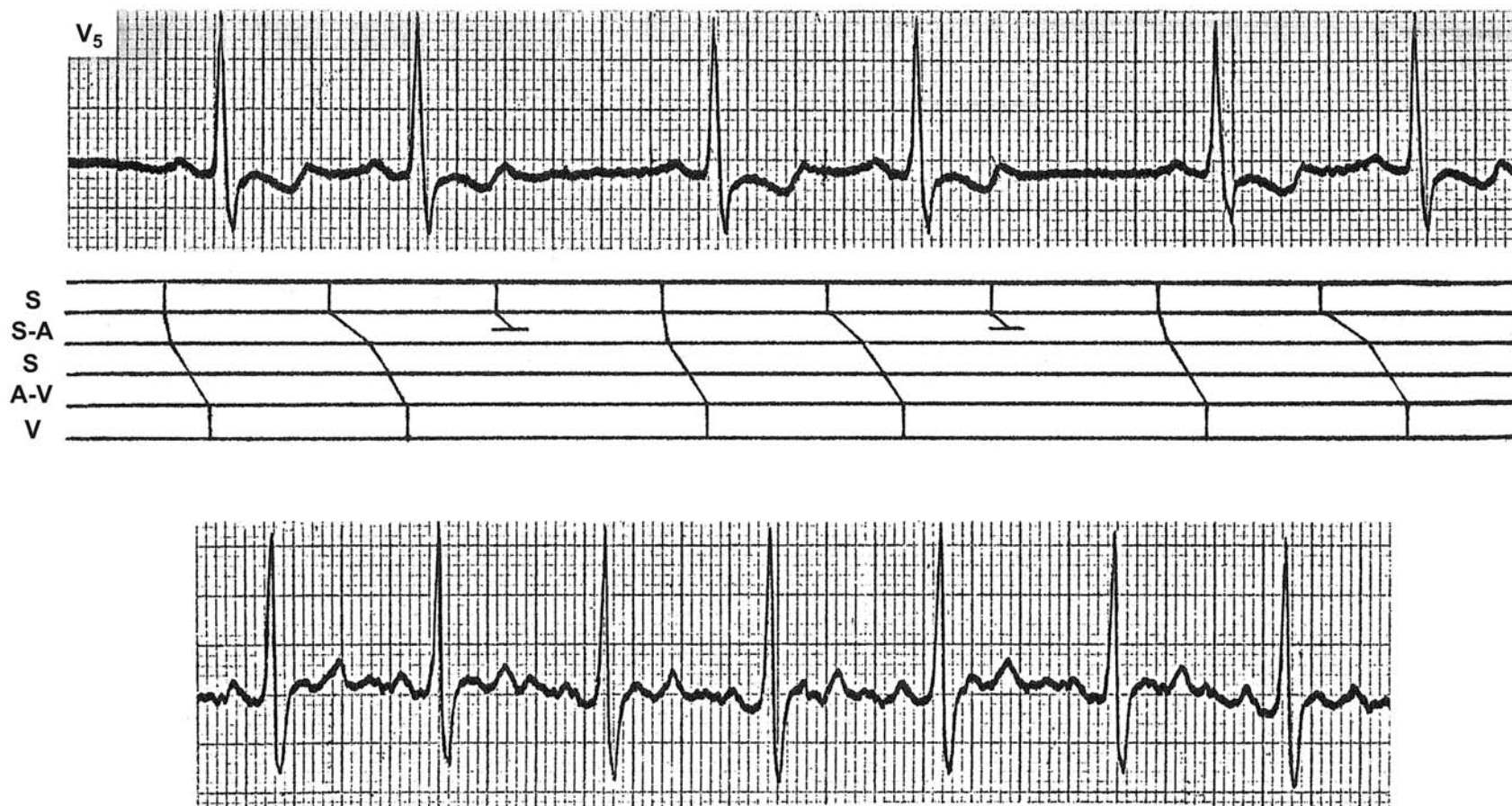




## Sinus Node Dysfunction

SA node dysfunction can be primary or secondary to drugs (e.g. digitalis or type IA antiarrhythmic agents), ischemia, or infarction of the sinus node. When it is primary, it is called sick sinus syndrome.

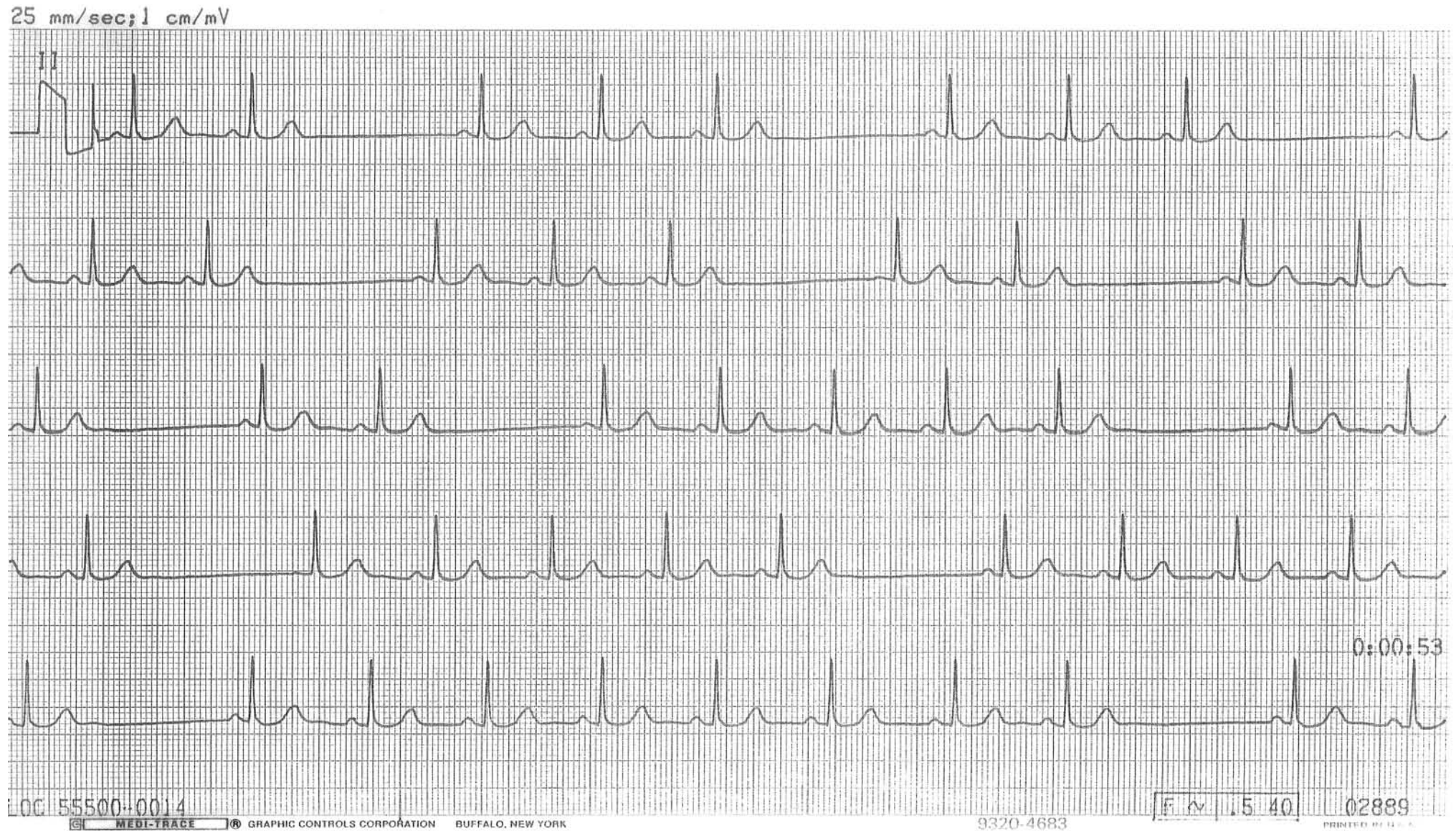
This patient has bigeminal rhythm. The differential diagnosis includes 3:2 SA block or atrial bigeminy. The P waves are identical favoring the former. If it is atrial bigeminy, the P wave morphology with the shorter R-R interval would be different from that of longer R-R intervals. In the tracing taken from the same patient a moment later, the rhythm becomes regular and the combination of short and long cycle lengths is equal to three basic cycle lengths. This strongly supports the diagnosis of 3:2 SA block, as diagrammed below. Note that the SA conduction lengthens before the impulse is blocked, hence Type I SA block.





## Type II SA Block

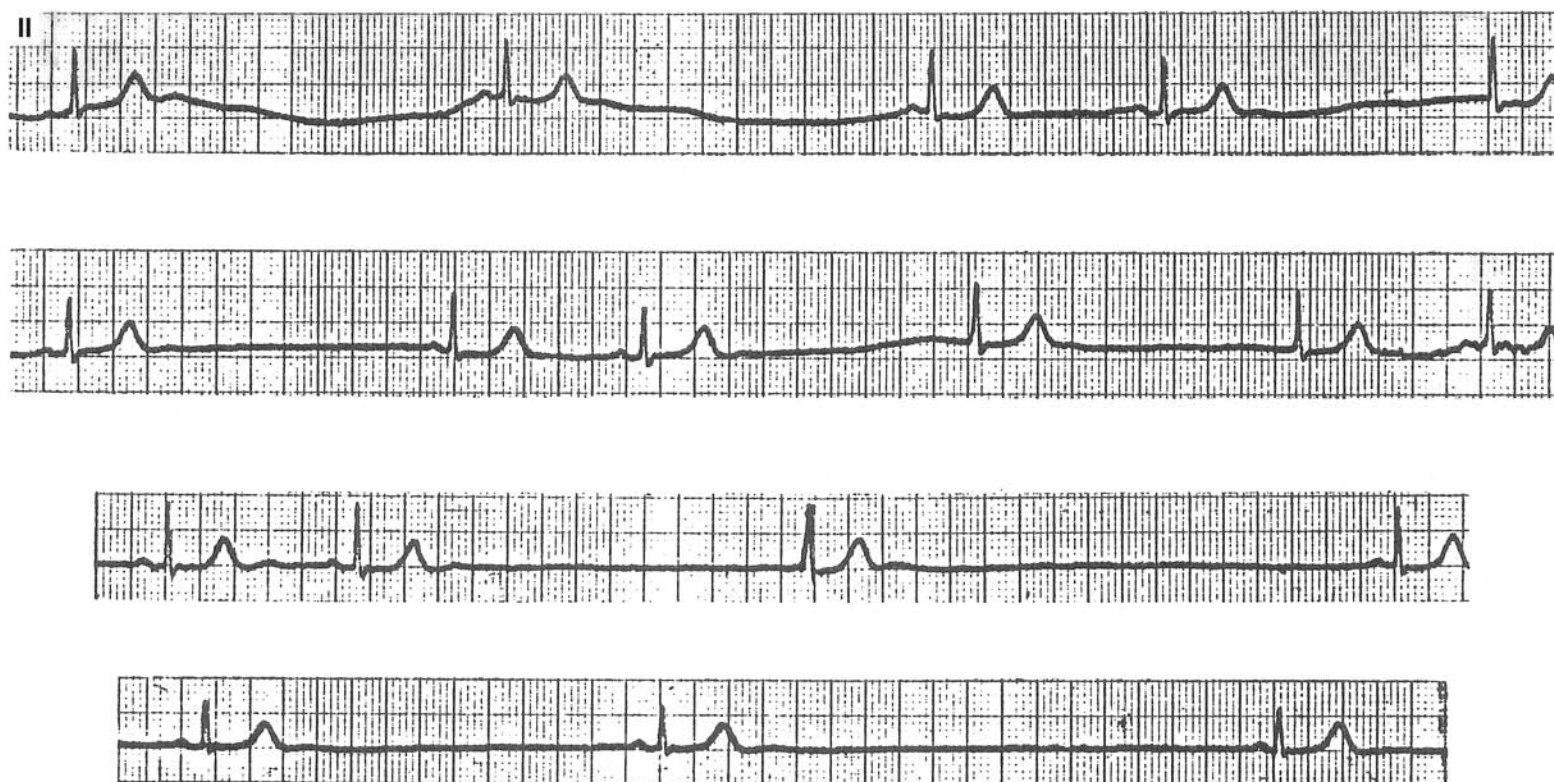
These rhythm strips reveal many pauses. These pauses are twice the basic cycle length and are diagnostic of type II SA block. In the case of sinus arrest, the pauses are not simple multiples of the basic cycle length.



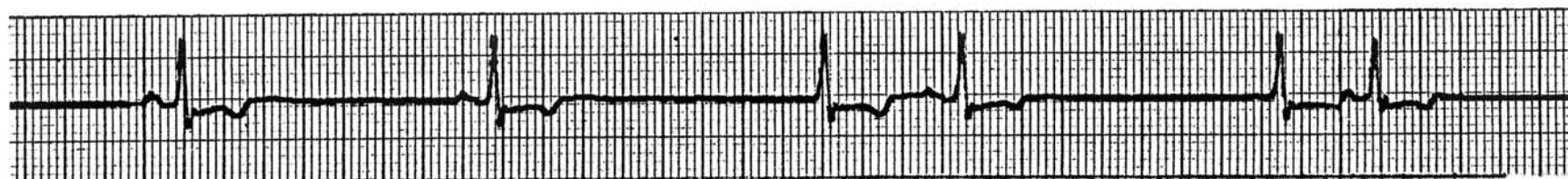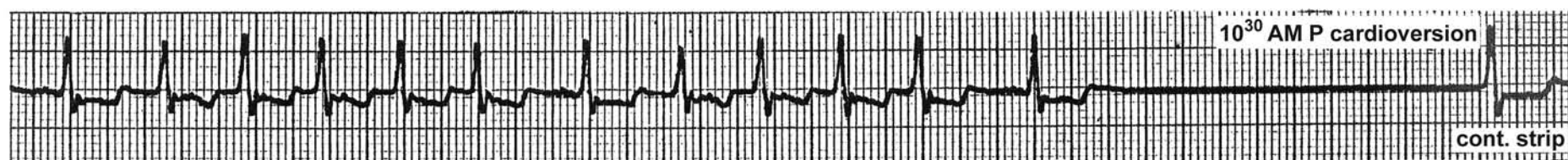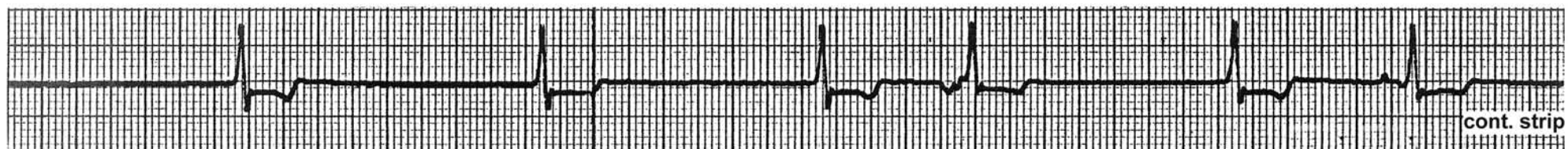
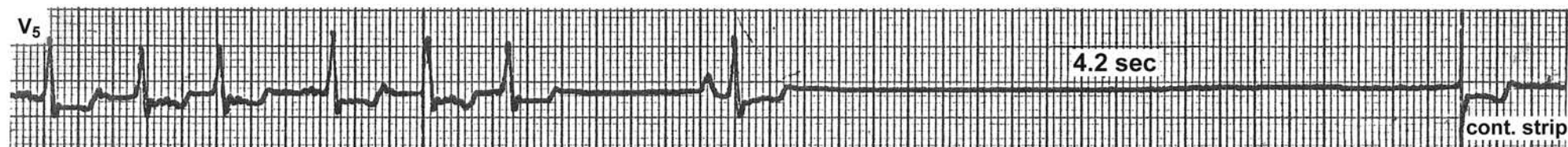


## Sick Sinus Syndrome

An example of sick sinus syndrome with a marked degree of sinus bradycardia. The occasional AV junctional escape beats also show marked slowing.



An example of sick sinus syndrome with alternating tachycardia and bradycardia





## Electronic Pacemaker

The atrium, the ventricle, or both can be paced and/or sensed electronically. Three or four position letter codes are used to describe the functions of pacemakers (e.g., DDDR, VVI, DVI, V00, AA1, etc.).

### Where:

*1<sup>st</sup> position letter:* The chamber paced (note that the primary function of the pacemaker is to pace, not to sense; hence, 1<sup>st</sup> position)

*2<sup>nd</sup> position letter:* The chamber sensed

*3<sup>rd</sup> position letter:* The response to sensed signal (either inhibited or triggered)

*4<sup>th</sup> position letter:* Rate adaptiveness

A: Atrium

V: Ventricle

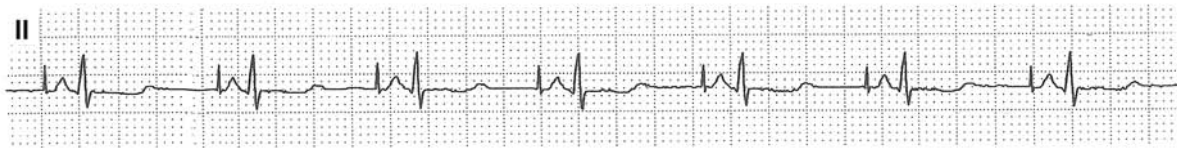D: Dual or both (both A and V or both I and T)

I: Inhibited response to sensed signal (pacemaker discharge is suppressed by a sensed signal)

T: Triggered response to sensed signal (pacemaker discharge is triggered by a sensed signal)

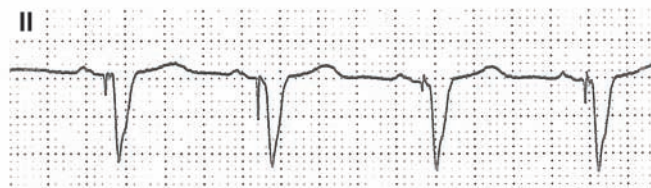### Atrial Pacing (AAI or DDD)

This type of pacemaker serves the purpose when the sinus rate is not fast enough (chronotropic incompetence) while AV conduction is intact.



### P Triggered Ventricular Pacing (VAT)

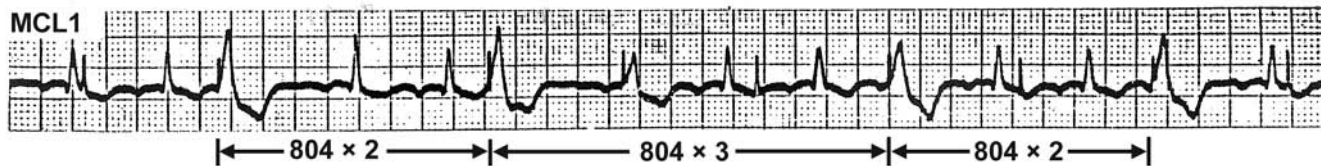
The electrode in the atrium senses the patient's P wave and commands the ventricular electrode to pace after a programmed "PR" interval. This kind of pacemaker serves the purpose when the problem is AV block while the sinus node function is intact. In this way, the physiologic sequence of atrial and ventricular contractions is maintained. In addition, the pacing rate follows the sinus rate which is more physiologic. An upper rate limit prevents the pacemaker from following the P wave above the programmed rate.



## Ventricular Pacing, Fixed Mode (V00)

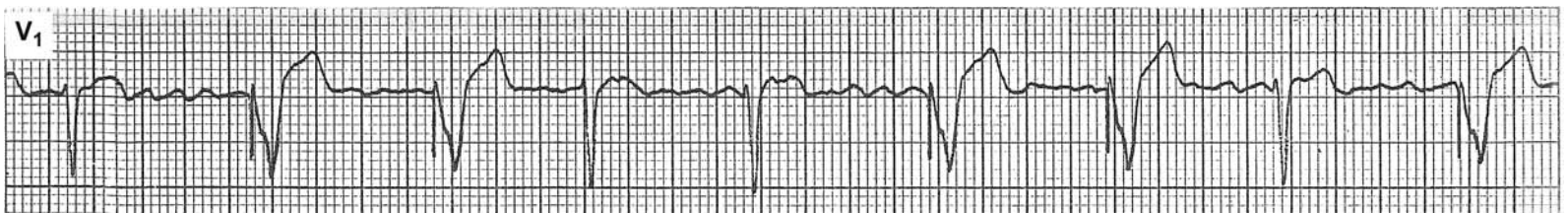The pacemaker stimulates the ventricle at a fixed rate, regardless of the presence or absence of the patient's own QRS. A paced QRS results only when the pacing spike occurs outside the ventricular refractory period. This situation can be considered as an artificially-induced ventricular parasystolic rhythm, i.e., there is a focus in the ventricle which discharges impulses regularly without being affected or reset by the patient's own rhythm (entrance block). These manifest as "VPBs" whenever the impulse occurs outside the ventricular refractory period, but are "silent" whenever the impulse occurs during the ventricular refractory period. These VPBs occur with varying coupling intervals and the VPB to VPB intervals are simple multiples of the basic cycle length.

There is a small risk that this kind of pacemaker may initiate ventricular tachycardia or ventricular fibrillation by stimulating the ventricle during the ventricular vulnerable period (near the peak of the T wave), especially if the ventricle is ischemic or seriously diseased.



## Ventricular Pacing, Demand Mode by Inhibited Response (VVI)

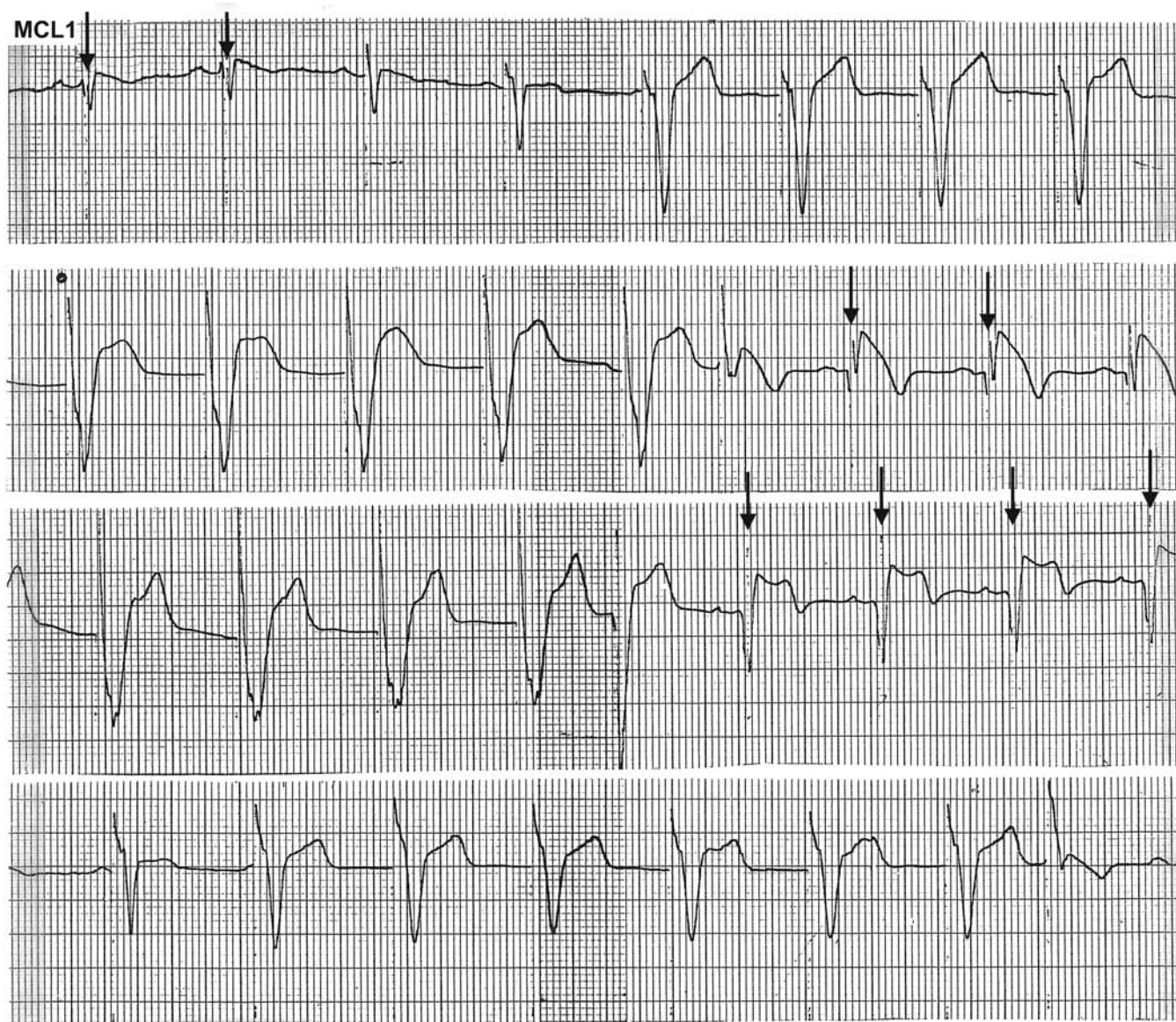
The patient is in atrial fibrillation and has a VVI mode pacemaker. The ventricle is paced whenever the patient's own QRS does not occur within the programmed interval. However, if the patient's own QRS occurs during this period, the pacemaker senses the QRS and is inhibited from discharging. This resets the pacing timing cycle. In this way, the pacemaker discharges only when there is a need; hence, a "demand" mode. Discharge on demand saves the battery's energy. Moreover, since the pacemaker is prevented from firing during the ventricular vulnerable period, the risk of the pacemaker initiating ventricular tachycardia or ventricular fibrillation is obviated.





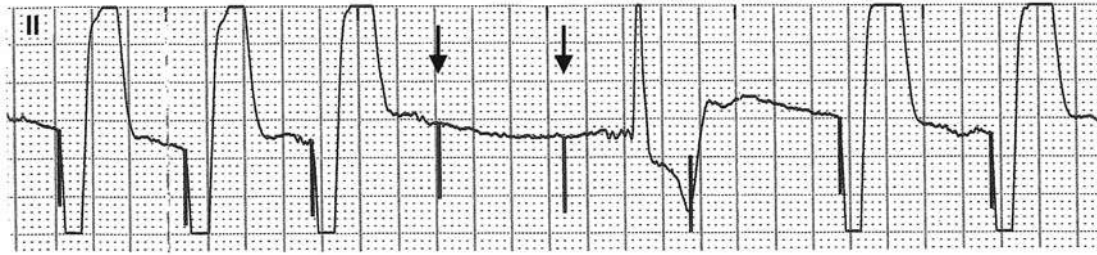
## Ventricular Pacing, Demand Mode by Triggered Response (VVT)

This patient has a VVT mode pacemaker. The ventricle is paced about half the time; during the other half, the patient's own rhythm prevails. Upon sensing the patient's own QRS, the pacemaker is programmed to discharge (↓) within the sensed QRS (the ventricular myocardium is absolutely refractory at this time) and the pacing cycle is reset. This prevents the pacemaker from firing during the ventricular vulnerable period, obviating the risk of inducing ventricular tachycardia or fibrillation. These features allow the patient's own rhythm to prevail, while the ventricle is paced as needed. A disadvantage of this mode is that the pacemaker continues to discharge when there is no need. This unnecessarily drains the battery. Moreover, the pacing spike distorts the patient's own QRS morphology. However, this mode is useful in a situation where noncardiac signals, such as myopotentials, are sensed. In that situation, a VVI mode pacemaker will be inhibited as long as these signals are sensed, which may result in a long period of asystole. In contrast, the VVT mode pacemaker will pace the ventricle up to the programmed upper rate limit. This mode is not in use now a days.



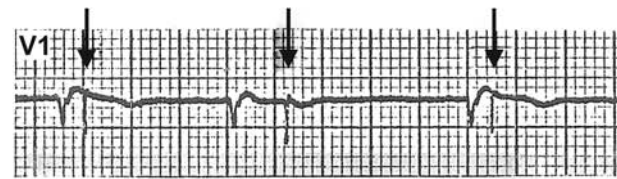
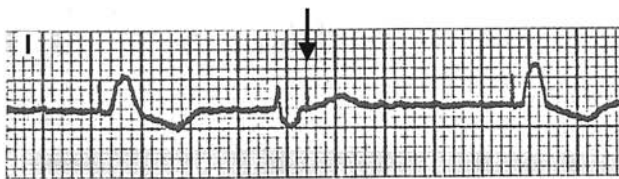
## Failure to Capture

The 4<sup>th</sup> and 5<sup>th</sup> pacing spikes (↓) fail to capture the ventricles even though they occur outside the ventricular refractory period. Causes for this include: an increase in pacing threshold due to ischemia, hyperkalemia, drug toxicity, poor electrode contact with the endocardium, fibrosis around the electrode tip, etc.



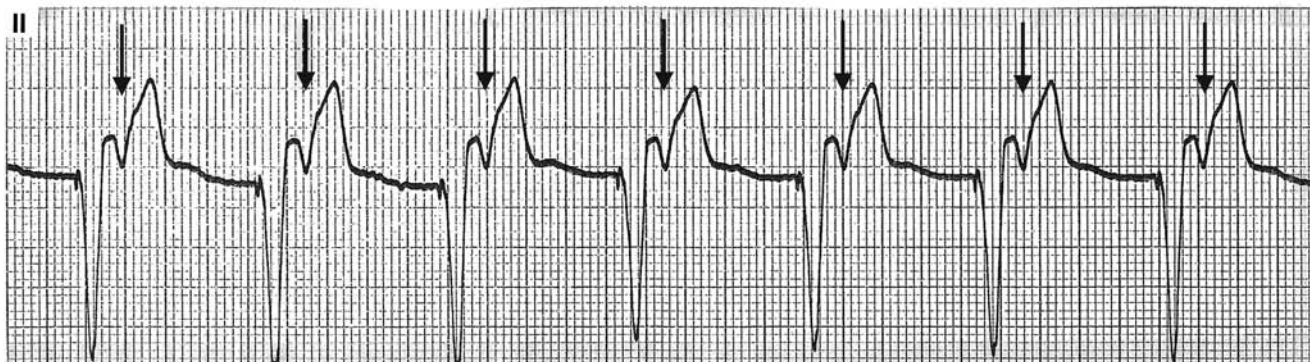
## Failure to Sense

This patient has a VVI (demand mode) pacemaker. However, the pacemaker fails to sense the patient's own QRS and the pacing spikes (↓) are seen following the QRS, which is inappropriate; however, there is no failure to capture, as long as the pacing spike occurs outside the ventricular refractory period. Causes for this include: an increase in sensing threshold, poor electrode contact with the endocardium, etc.



## Ventricular Pacing with 1:1 VA Conduction

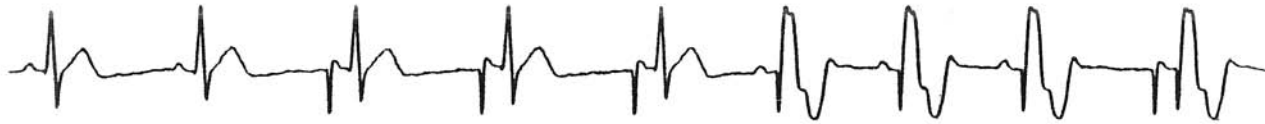Every pacer induced QRS is followed by a retrograde P wave (↓). Approximately 15–20% of patients with this situation develop pacemaker syndrome. (Pulsation in the neck from cannon “a” waves, hypotension causing dizziness or even syncope at times.)





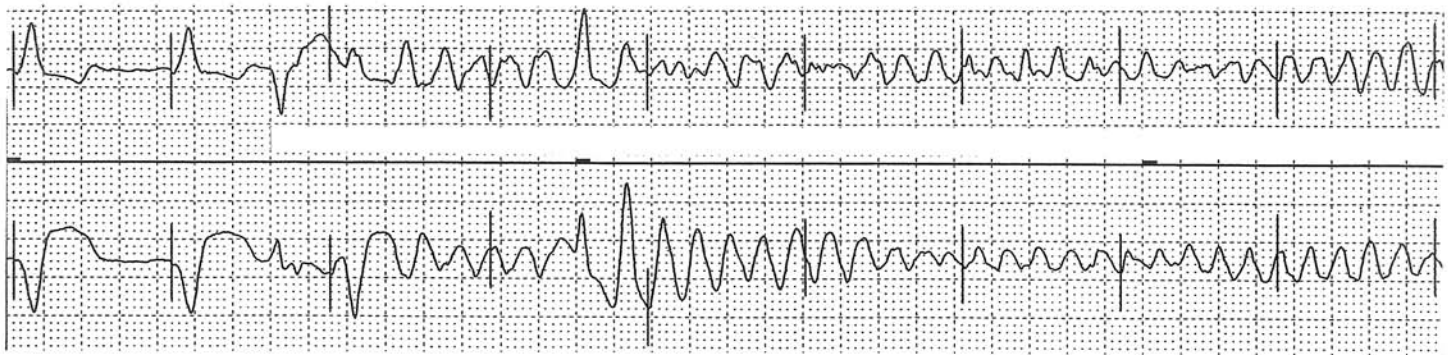
## AV Sequential Pacing (DDD, DVI)

The atrial electrode paces the atrium, and after a programmed delay, commands the ventricular electrode to pace the ventricle (AV sequential pacing, the last complex). If the patient's own sinus rate becomes faster than the programmed atrial pacing rate, the pacemaker is switched to a P triggered mode (6<sup>th</sup> through 8<sup>th</sup> complex). If the patient's AV conduction resumes and the sinus rate is fast enough, both atrial and ventricular pacing will be inhibited (first two complexes). If AV conduction becomes normal, but the sinus rate is not fast enough, the pacemaker is switched to an atrial pacing mode (3<sup>rd</sup> through 5<sup>th</sup> complexes). This is indeed a "can-do-all" pacemaker, also called a "universal" pacemaker.



## Pacemaker Induced Ventricular Arrhythmia

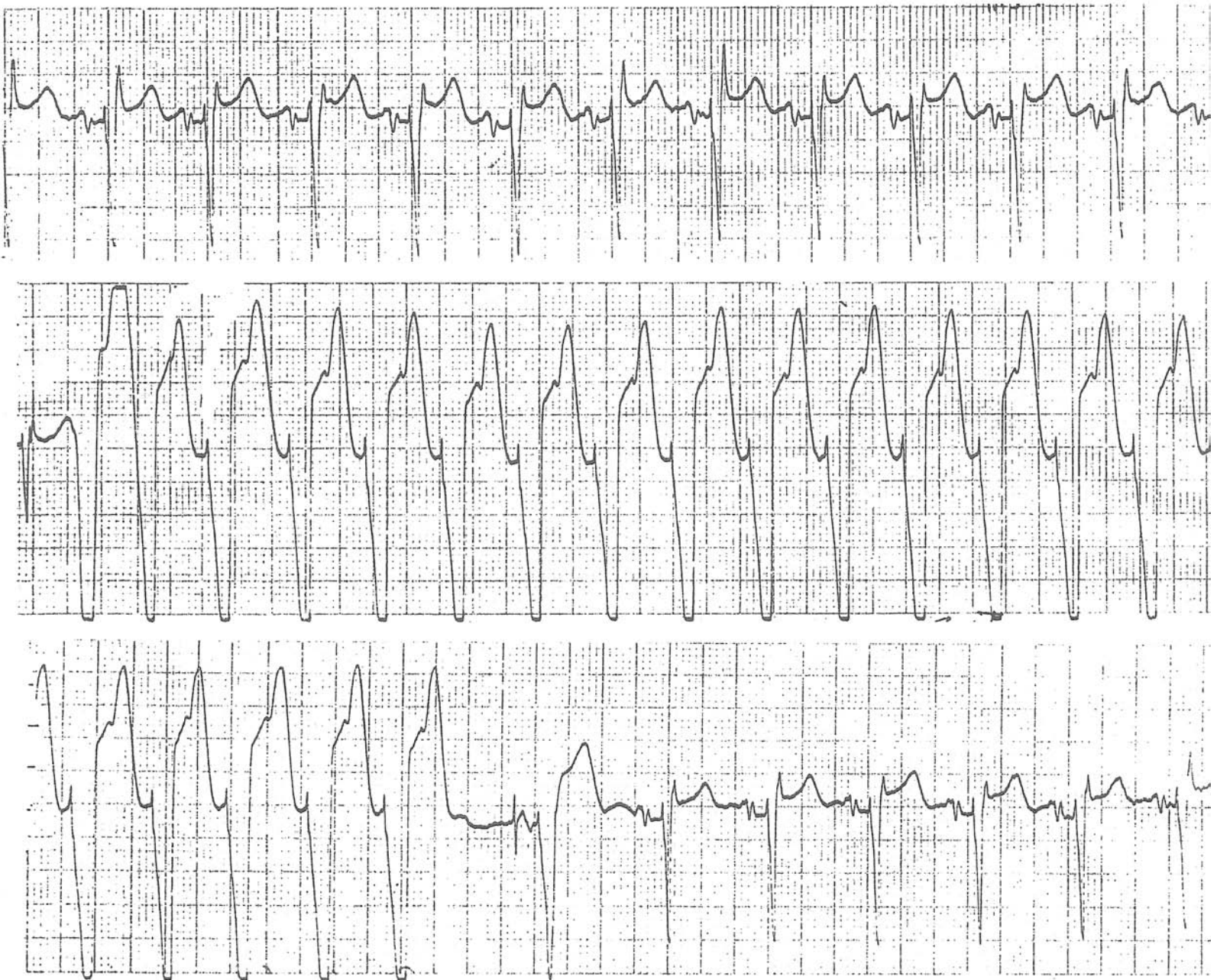Pacemaker spike occurs during the ventricular vulnerable period (near the peak of the T wave), initiating polymorphic ventricular tachycardia (or ventricular flutter). This disaster rarely occurs unless the myocardium is ischemic or severely diseased.



## Pacemaker Mediated (Endless Loop) Tachycardia

This patient has a dual chamber pacemaker. The first two wide complexes in the middle strip are VPBs. The second VPB produces a retrograde P wave which is sensed by the atrial electrode, commanding the ventricular electrode to pace the ventricle. This again causes a retrograde P wave and the cycle repeats again and again, hence the name “endless loop” tachycardia. The most effective way to terminate this tachycardia is to apply a magnet over the pulse generator which will convert the pacemaker mode to VOO from DDD, and prevent sensing of the retrograde P wave. Prevention of recurrences of this tachycardia is achieved by lengthening the atrial refractory period so that the retrograde P wave will not be sensed. Note the atrial pacemaker spike in the first beat after the conversion.

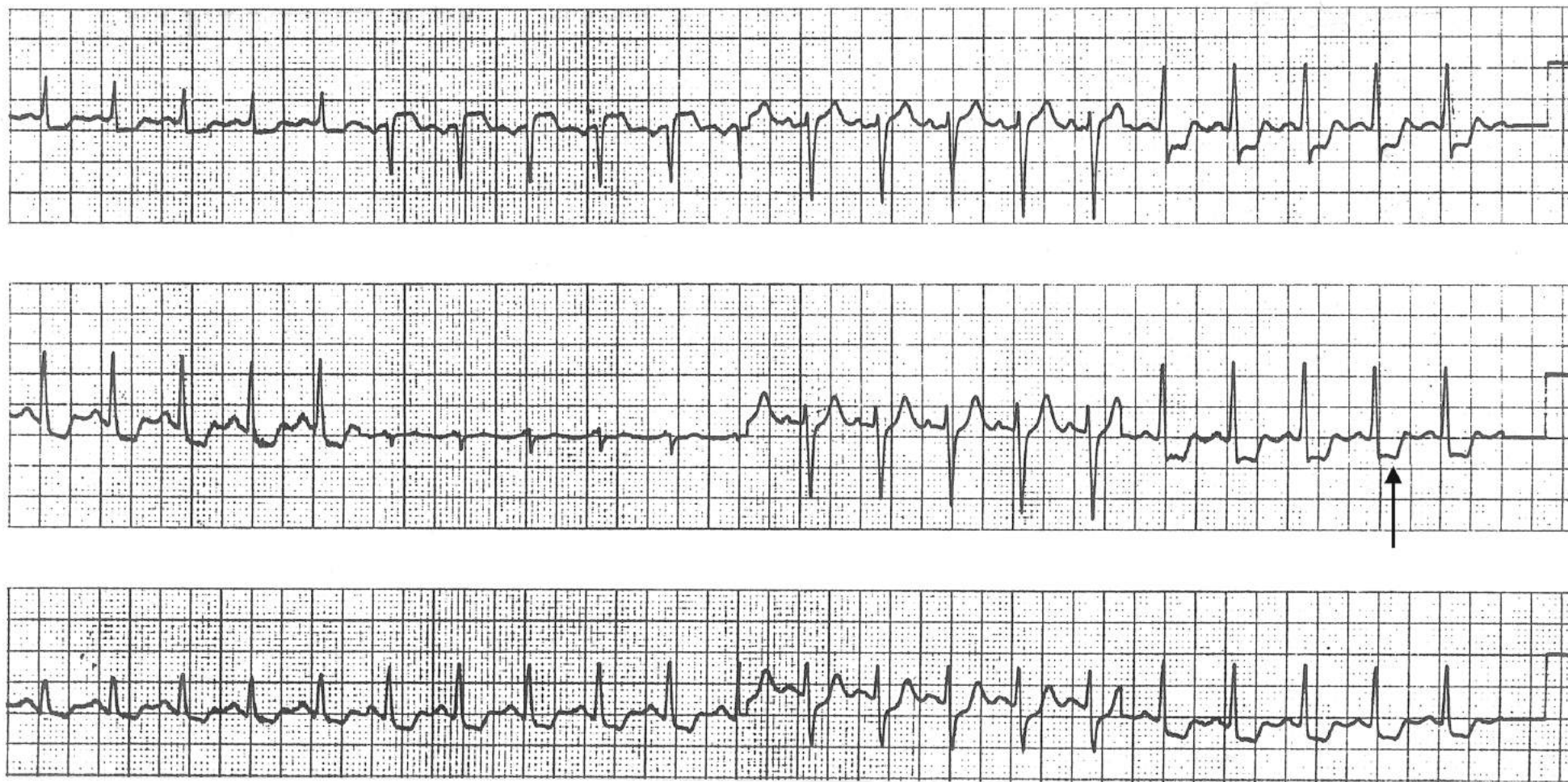
MCL1



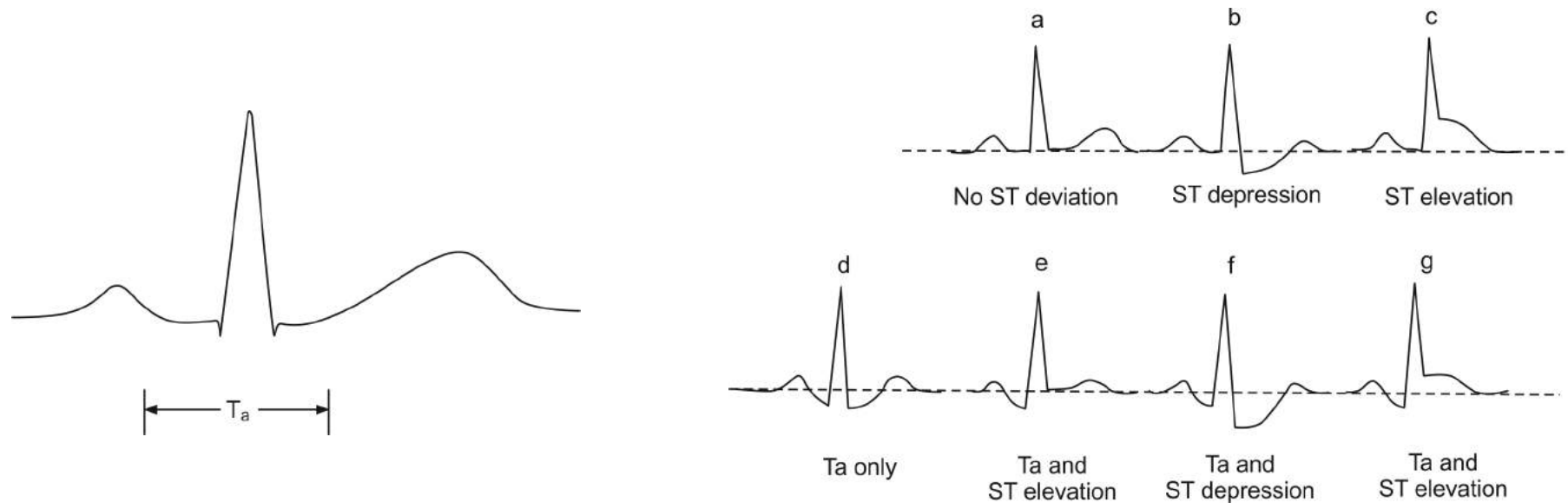


## Stress Electrocardiography

A typical example of a positive stress test revealing horizontal ST depression (↑) in the inferolateral leads.



## Atrial Repolarization (Ta) Wave

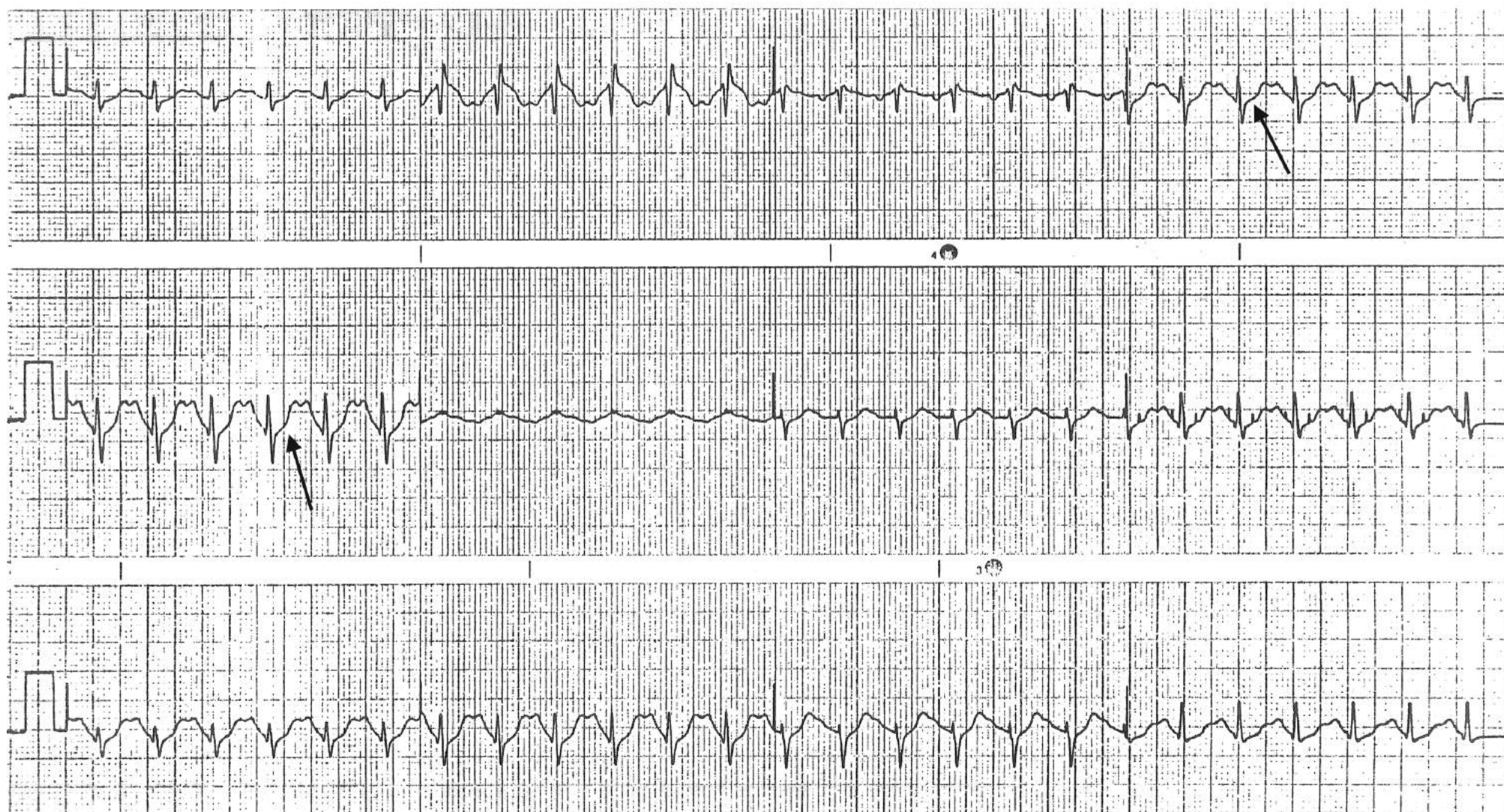


Just as the ventricular myocardium undergoes repolarization after depolarization, the atrial myocardium also undergoes repolarization. The atrial repolarization wave is called a “Ta” wave (atrial T-wave) and lasts about 60 msec beyond the QRS. Ordinarily, the Ta wave is not conspicuous. The sequence of atrial repolarization is in the same direction as that of depolarization (parallel to the atrial wall) and the Ta wave is directed opposite to the P vector. (Note that the sequence of ventricular repolarization is from epicardium to endocardium, which is opposite to that of ventricular depolarization (from endocardium to epicardium) and the T wave is directed to the same direction as the major QRS component). Therefore, the Ta wave is negative in leads where the P wave is positive. The atrial counterpart of ST elevation (as in pericarditis or atrial infarction) is PR-segment depression while that of ST depression is PR-segment elevation. During sinus tachycardia, the Ta wave becomes prominent at times, and manifests as a “scooped out” wave lasting beyond the QRS. This downsloping PR segment and upsloping ST segment will make a smooth curvature, i.e., a curvature with a single radius as in d. If a smooth curvature cannot be drawn because there is a “drop-off” at the beginning of the ST segment, as in f, it is a prominent Ta wave combined with ST depression. In e, even though the ST segment is at the same level as the TP segment, the prominent Ta wave manifested by a downsloping PR segment indicates that there is actually ST-segment elevation. The complex g reveals a combination of Ta wave (PR-segment depression) and ST elevation, which may occur in pericarditis. Therefore, it is important to use the end of the PR segment, not TP segments, as the reference point to measure the ST-segment deviation. In complexes a, b and c the Ta wave is not conspicuous and the PR segment is at the same level as TP segment (true baseline), and either can be used as the reference point for ST segment deviation. In interpreting a stress ECG, a prominent Ta wave is often mistakenly called “upsloping ST depression”.



## Prominent Ta Waves During an Exercise Test

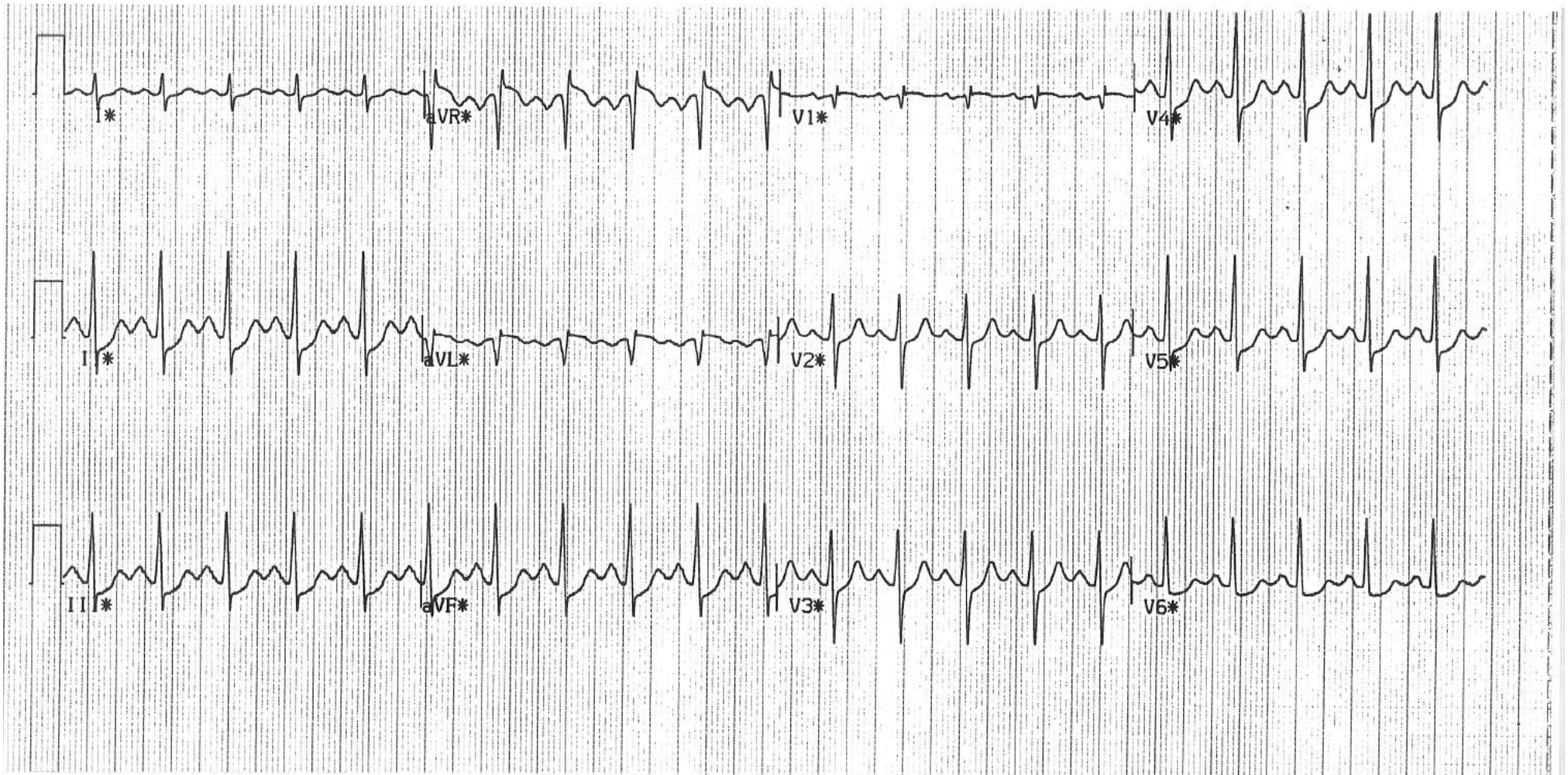
Note that the downsloping PR segment and the upsloping ST segment ( $\downarrow$ ) make a smooth curvature, i.e., the end of the PR segment and the beginning of the ST segment are at the same level (Ta wave). The ventricular myocardium (or the QRS) is not responsible for this upsloping ST segment, and this tracing should not be interpreted as showing “upsloping ST depression”.





## Prominent Ta Waves Combined with an Upsloping ST Depression

Note that the downsloping PR segment and the upsloping ST segment do not make a smooth curvature. Rather, the J point (the beginning of the ST segment) is depressed when compared to the end of the PR segment. Therefore, this tracing reveals upsloping ST depression in addition to a Ta wave.





## Preexcitation (WPW) Syndrome

Normally, impulses are transmitted from the atria to the ventricles (or from the ventricles to the atria) only through the specialized AV conduction system. In rare patients, an accessory pathway (bundle of Kent) is present which connects the atrium and the ventricle and transmits impulses. In this situation, the ventricular myocardium is activated by the atrial impulse through two different pathways: the normal AV conduction system and the accessory pathway. Unlike the AV node, the accessory pathway transmits the impulse with a shorter delay and activates a portion of the ventricular myocardium before the impulse traveling through the AV node activates the remaining part of the ventricular myocardium (preexcitation). It is this preexcitation that causes the slurred beginning (upstroke or downstroke) of the QRS, which is called a delta wave. Activation of the remaining ventricular myocardium through the AV conduction system results in the rest of the QRS. The PR interval is measured from the beginning of the P wave to the beginning of the delta wave and is shorter than normal. The diagnosis of preexcitation syndrome is made by the presence of short PR intervals and delta waves. The degree of the PR shortening and the size of the delta wave are determined by how much of and how quickly the ventricular myocardium is preexcited. If the delta wave is isoelectric in a given lead, the PR interval will not measure short in that lead. If the delta wave is negative in a given lead, it may be mistaken for an abnormal Q wave of myocardial infarction. Preexcitation can be present constantly or intermittently. When it is intermittent, it may involve alternate beats or several consecutive beats, or it may last for several hours or days at a time.

The presence of an accessory pathway can result in atrioventricular (A-V) re-entrant tachycardia which makes up about 30% of SVTs. In A-V re-entrant tachycardia, the re-entry circuit is made of anterograde conduction through the AV node and retrograde conduction through the accessory pathway (orthodromic reentry) in about 95% of the cases. In this situation, since no part of the ventricular myocardium is preexcited, there is no delta wave and the QRS is narrow during the tachycardia. In about 5% of the cases, the reentry circuit consists of the accessory pathway for anterograde conduction and the AV node for retrograde conduction (antidromic re-entry). In this situation, the ventricles are activated entirely through the accessory pathway and the QRS is abnormally wide.

Whether it is orthodromic or antidromic reentrant tachycardia, AV blocking maneuvers or medications including digitalis, verapamil and adenosine can terminate the rhythm since the AV node is an integral part of the reentry circuit. With reentrant tachycardia, the ventricular rate is about  $150 \pm 30$  beats/min which is reasonably well tolerated and is usually benign. Atrial fibrillation is not so benign. When a patient with preexcitation syndrome develops atrial fibrillation, the impulses from the atrium will conduct through the accessory pathway which has much shorter refractory period than the AV node and ventricular rate can be close to 300/min and life threatening. Digitalis, verapamil, or adenosine can facilitate the conduction through the accessory pathway further, increasing the ventricular rate or vasodilate causing further hypotension, and is contraindicated. Intravenous Procainamide or ibutilide can slow conduction through the accessory pathway and, thus, slow the ventricular rate, or better yet, convert the atrial fibrillation. When the patient is hemodynamically unstable, the treatment of choice is electrical cardioversion.

In some patients, an accessory pathway is present which does not conduct impulses anterogradely, but is used only for retrograde conduction. In that case, during normal sinus rhythm, no part of the ventricular myocardium is preexcited, there is no delta wave and the PR interval is not short. The evidence of the accessory pathway being present is completely hidden from the surface ECG ("concealed" accessory pathway), but it is available for retrograde conduction and therefore can accommodate orthodromic reentrant tachycardia.

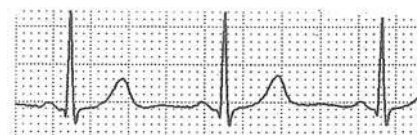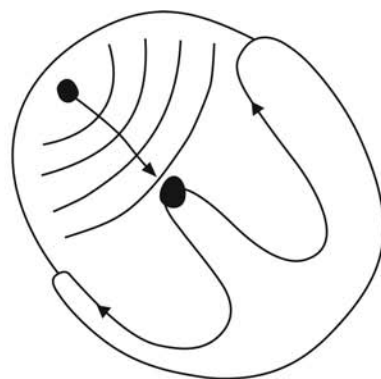
Asymptomatic preexcitation syndrome requires no further investigation or treatment. If the patient is symptomatic from these arrhythmias, the accessory pathway can be effectively ablated percutaneously. There may be more than one accessory pathway in a given patient. ECG findings of preexcitation syndrome can mimic many other conditions. Examples of these are shown in the following pages.



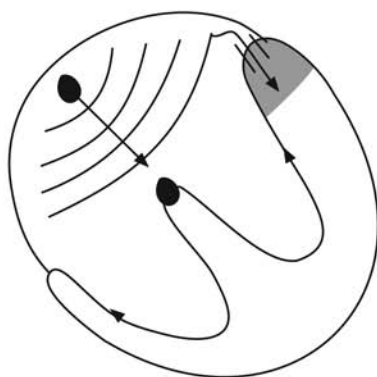
## Various Rhythms in WPW Syndrome

(see the preceding introductory pages for explanations)

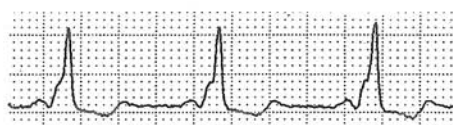
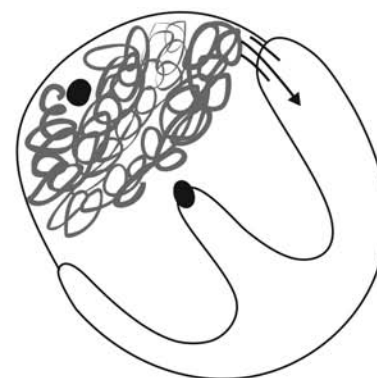
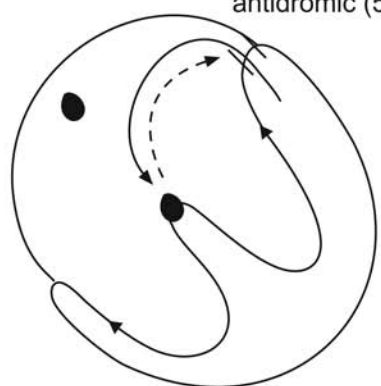
A) No WPW



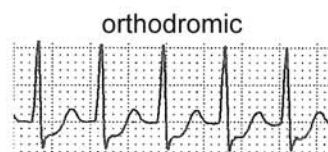
B) WPW



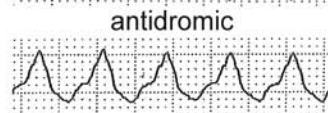
orthodromic (95%)  
antidromic (5%)



Sinus rhythm

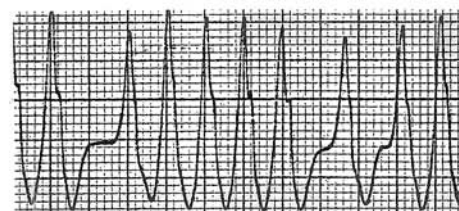


orthodromic



antidromic

A-V Re-entry

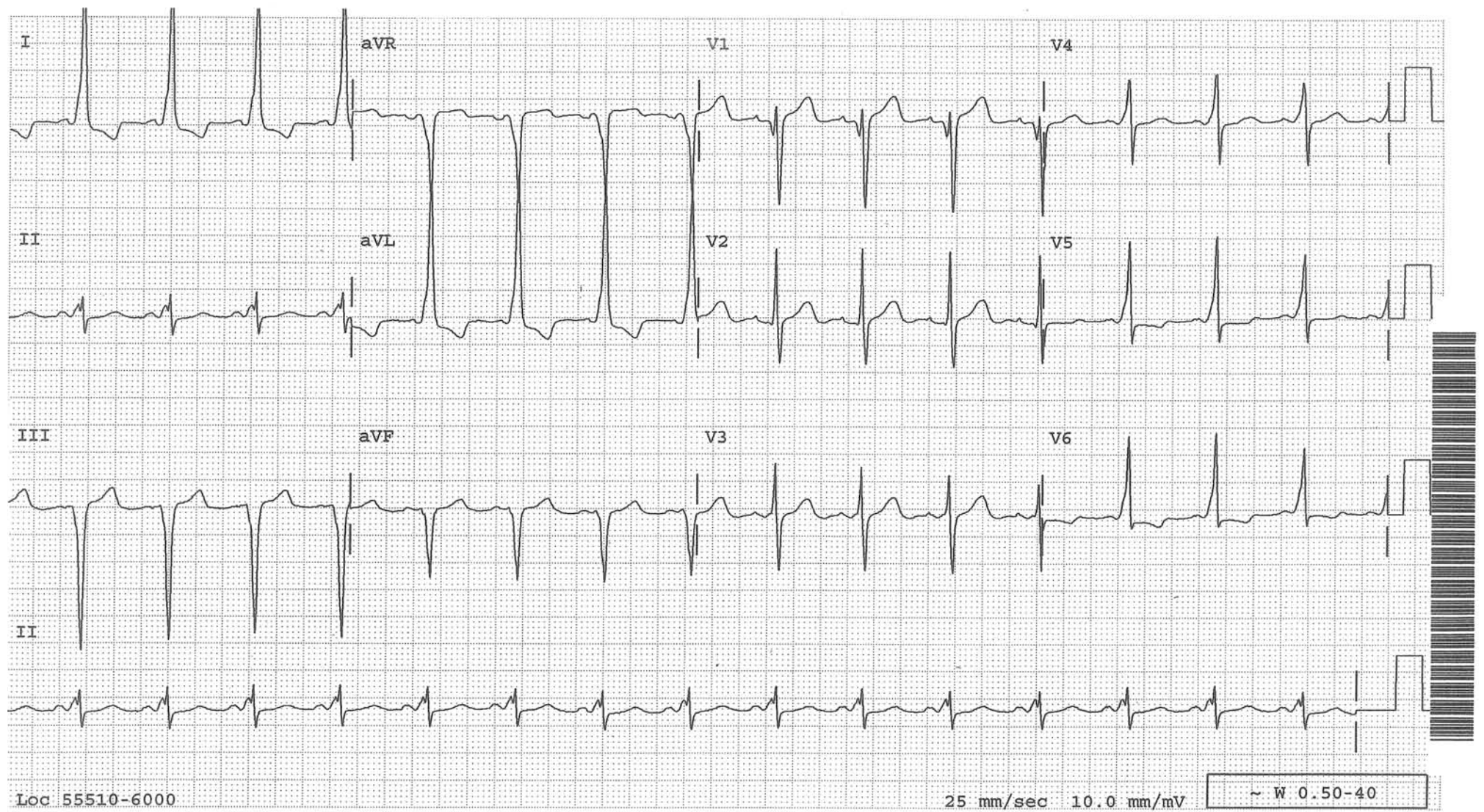


Atrial fibrillation



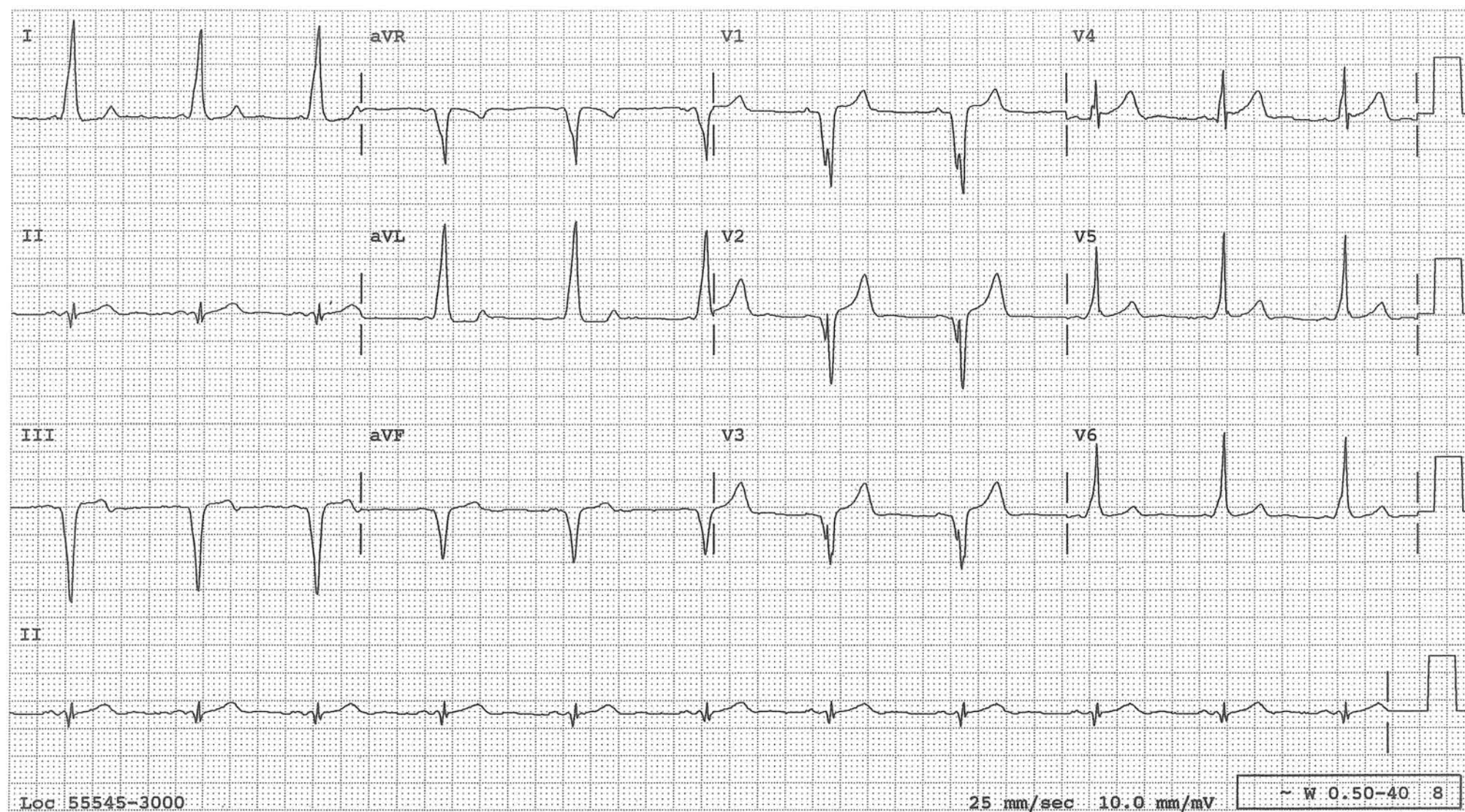
## A Typical Example of Preexcitation

Note the short PR intervals and delta waves





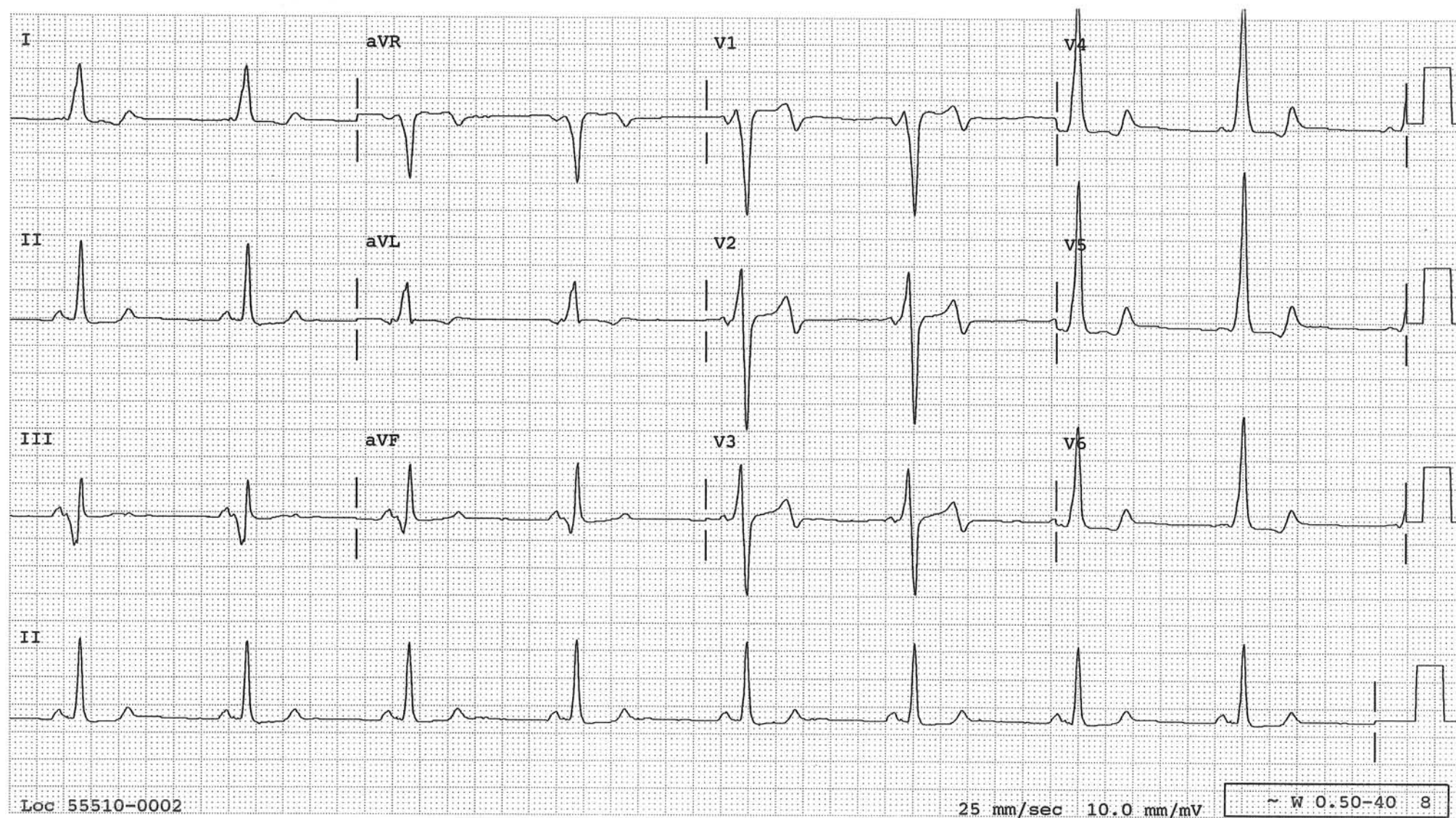
## An Example of Preexcitation Mimicking Anteroseptal and Inferior Myocardial Infarcts





## Preexcitation Simulating Inferior Infarct

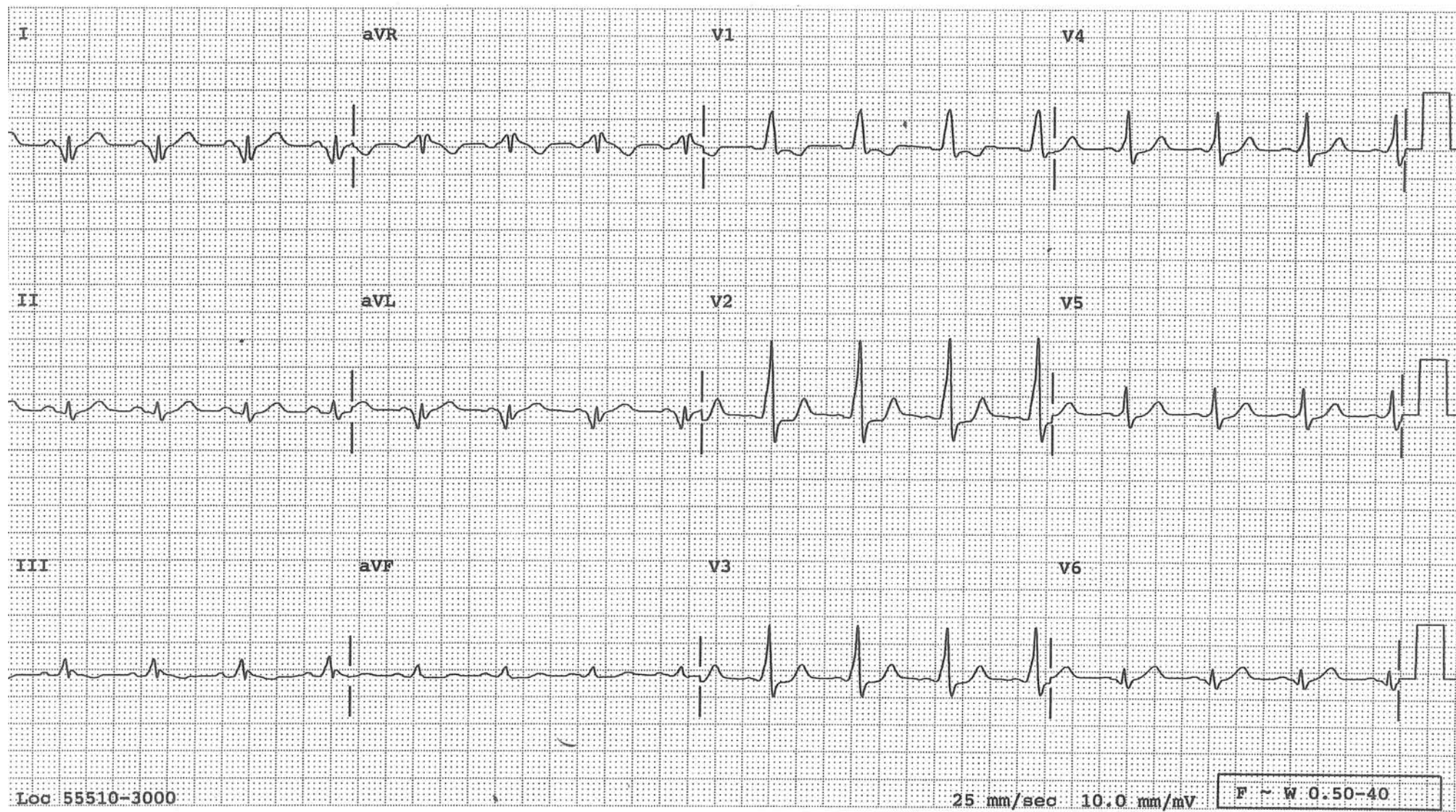
Wide "Q" waves in leads III and aVF, which are actually inverted delta waves





### Preexcitation Mimicking Posterolateral MI

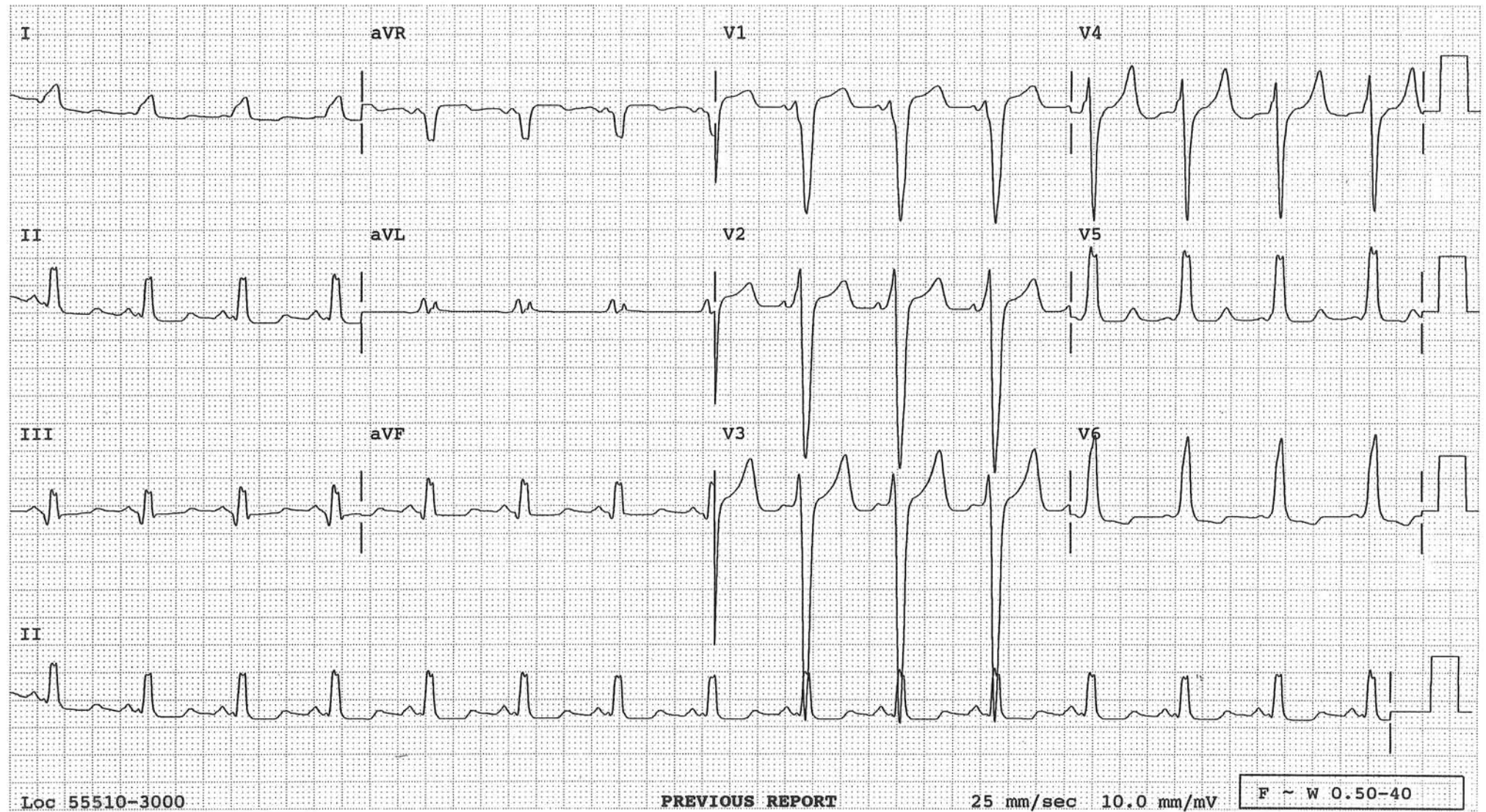
Wide “Q” waves in I and aVL are actually inverted delta waves and tall R waves in right chest leads are from the accessory pathway located in the posterior AV groove.





## Preexcitation Simulating Inferior MI and/or LBBB

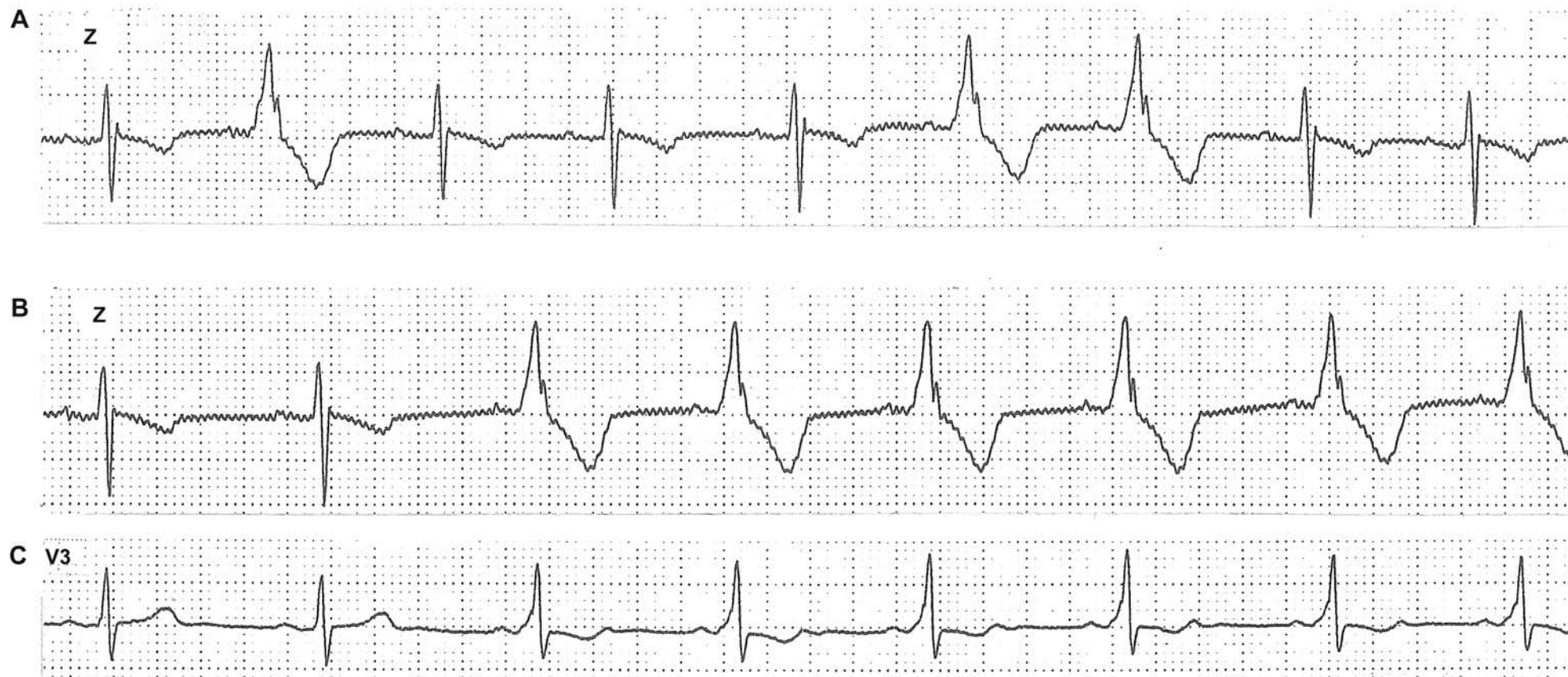The QRS in lead III suggests an inferior MI (wide “Q” wave). The QRS in lead I suggests LBBB (a monophasic R wave which is wide). This is an example of preexcitation simulating an inferior MI and/or LBBB. Short PR interval and more typical delta waves are evident in leads V1 through V5. When the delta wave is superiorly oriented, it will register as Q waves in inferior leads.



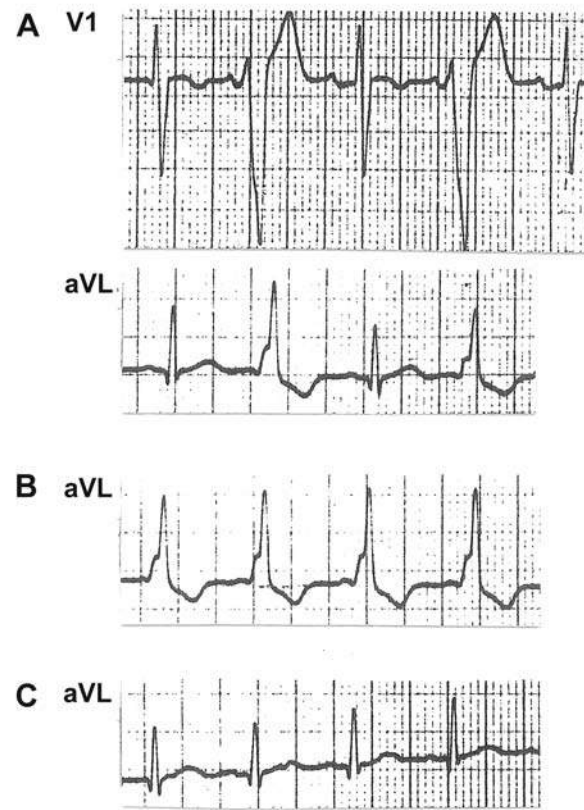


## Intermittent Preexcitation

Tracing A makes one think of frequent VPBs and tracing B makes one think of an accelerated idioventricular rhythm. Tracing C is taken simultaneously with tracing B, using a different lead. It readily reveals a short PR interval and a delta wave, confirming intermittent preexcitation.



## Intermittent Preexcitation



Selected strips from the same patient at different times.

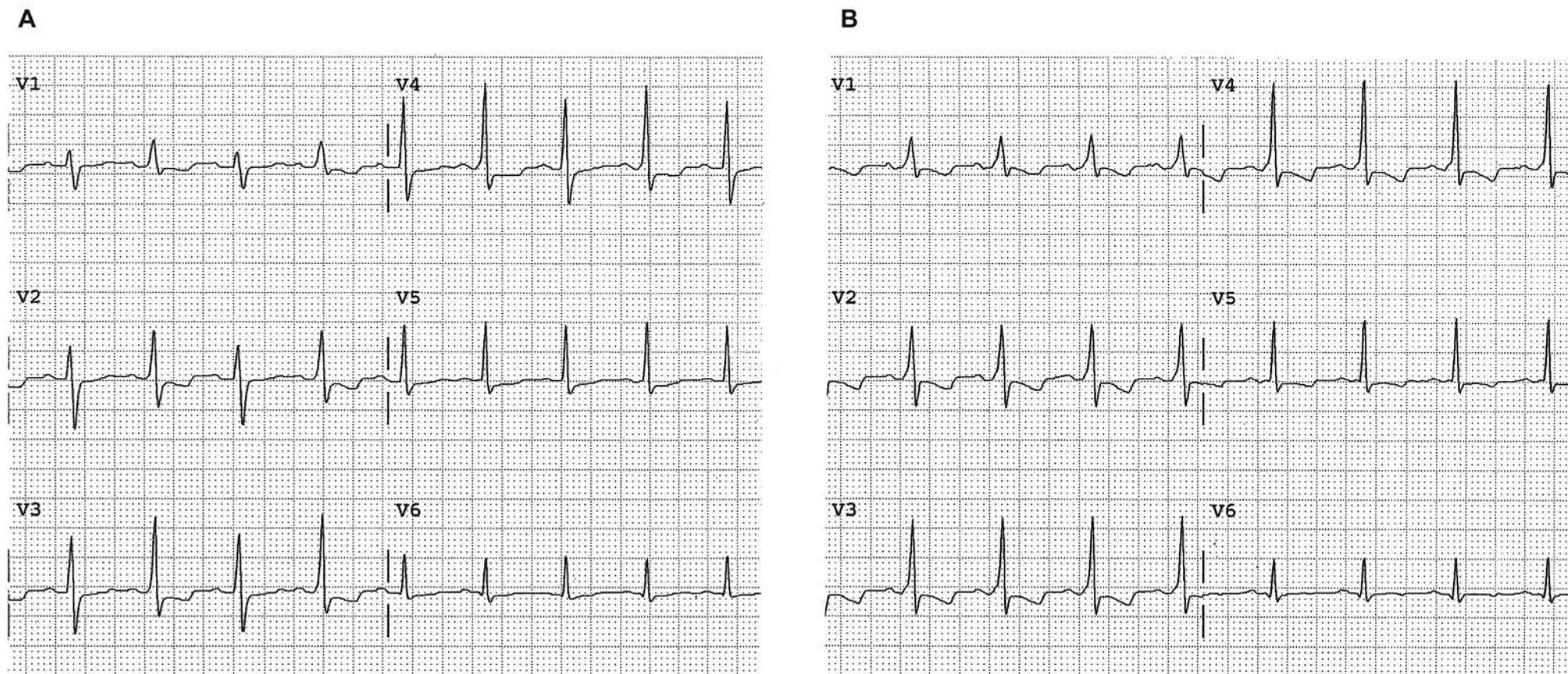
**A:** Preexcitation in the alternate beats simulating ventricular bigeminy.

**B:** Every QRS is preexcited.

**C:** No QRSs are preexcited, confirming the intermittency of preexcitation in this patient.



## Preexcitation of Every Other Beat Simulating Electrical Alternans

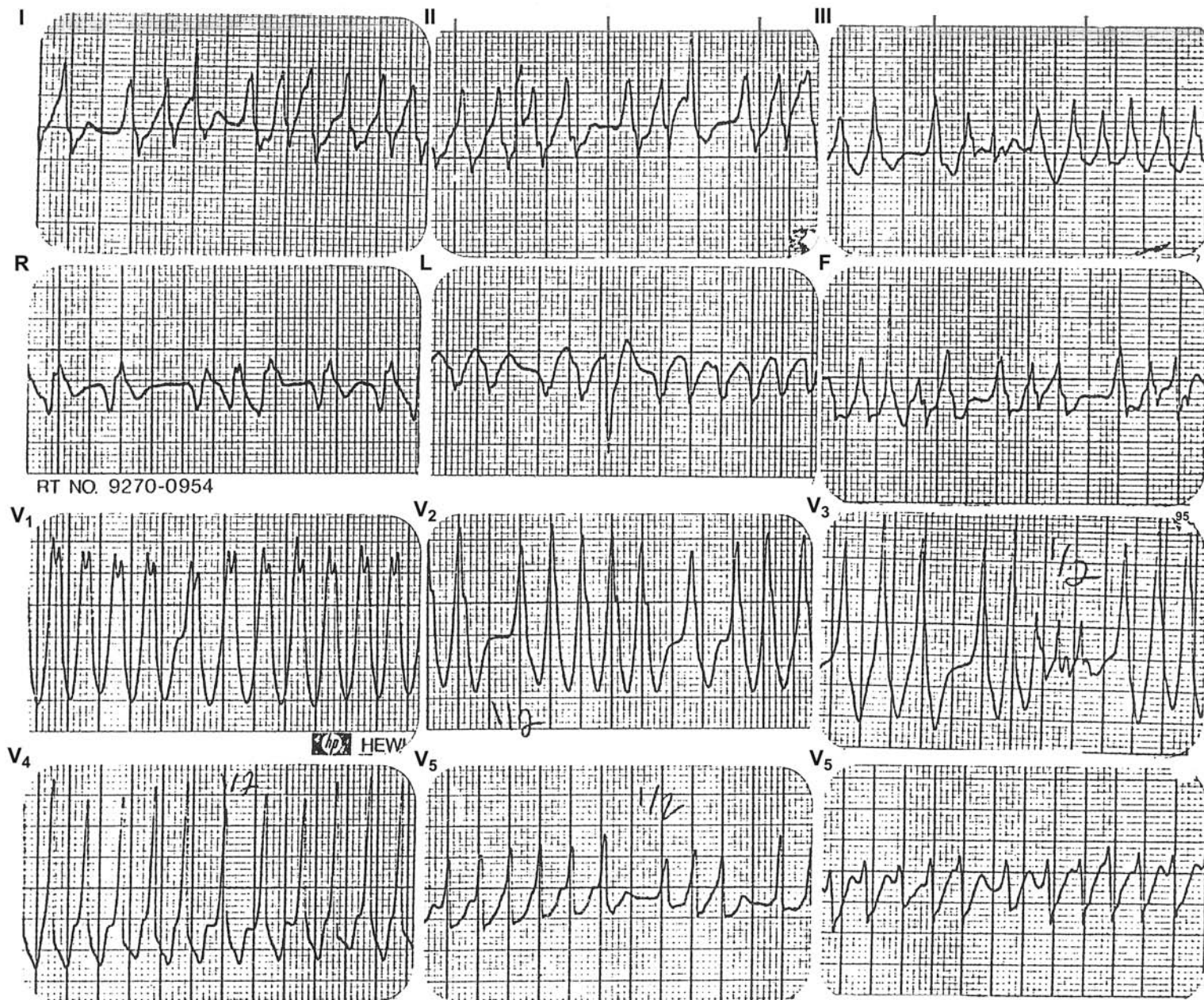


In tracing A, preexcitation in alternate beats simulates electrical alternans. The short PR interval and delta wave in the preexcited complexes are barely discernible in V4. Tracing B is taken from the same patient a moment later when every QRS is preexcited. In addition, more ventricular myocardium is preexcited and the short PR interval and delta waves are more readily recognizable.



## Atrial Fibrillation in WPW Syndrome

A patient with WPW syndrome during atrial fibrillation and almost 1:1 conduction to the ventricle through the bypass tract, resulting in what appears to be ventricular tachycardia or flutter. Marked irregularity in the R-R interval with pauses nearly as long as two R-R cycle lengths is the clue to the correct diagnosis. An electric shock to the precordium is the treatment of choice (one is converting atrial fibrillation to sinus rhythm). If patient is stable, chemical conversion with IV procainamide or ibutilide can be tried.

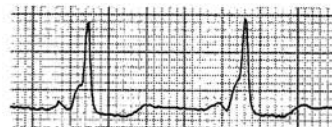




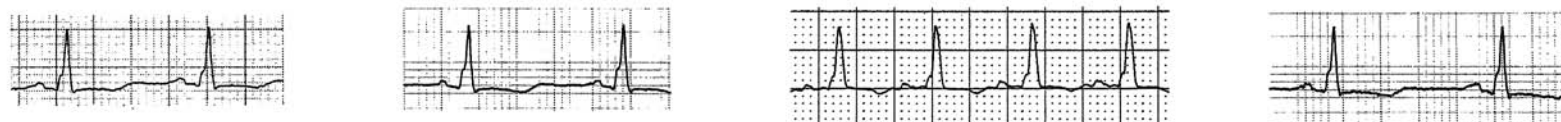
## True and Pseudo Delta Waves

(See discussion on the next page)

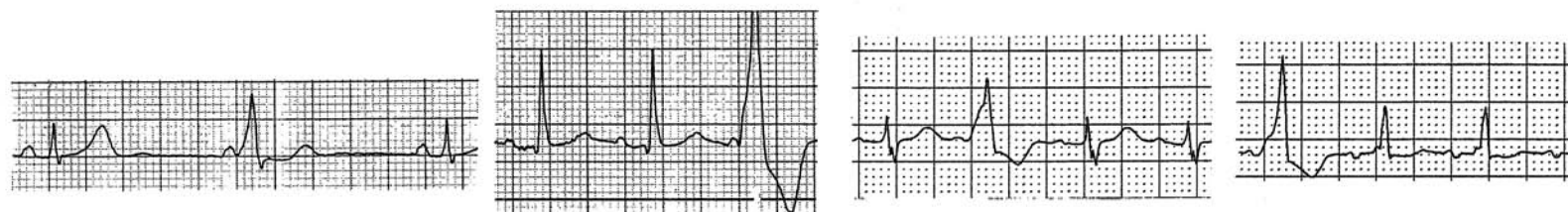
A



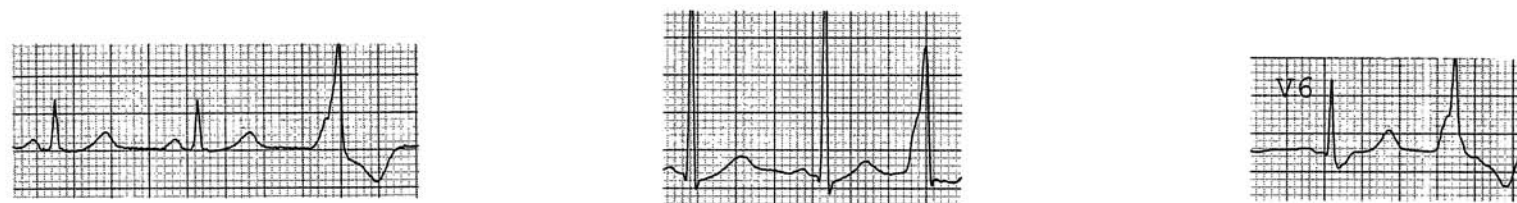
B



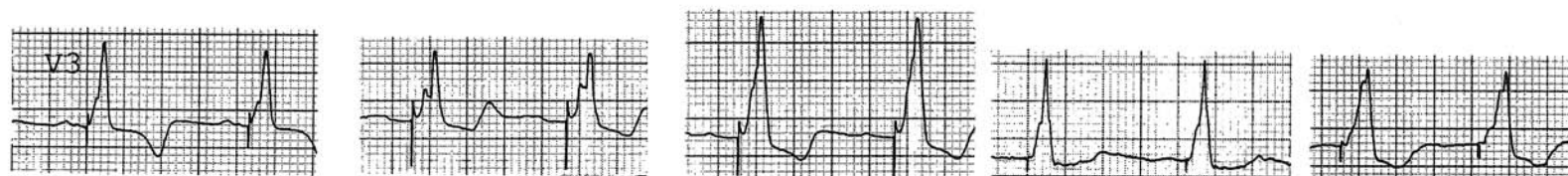
C



D



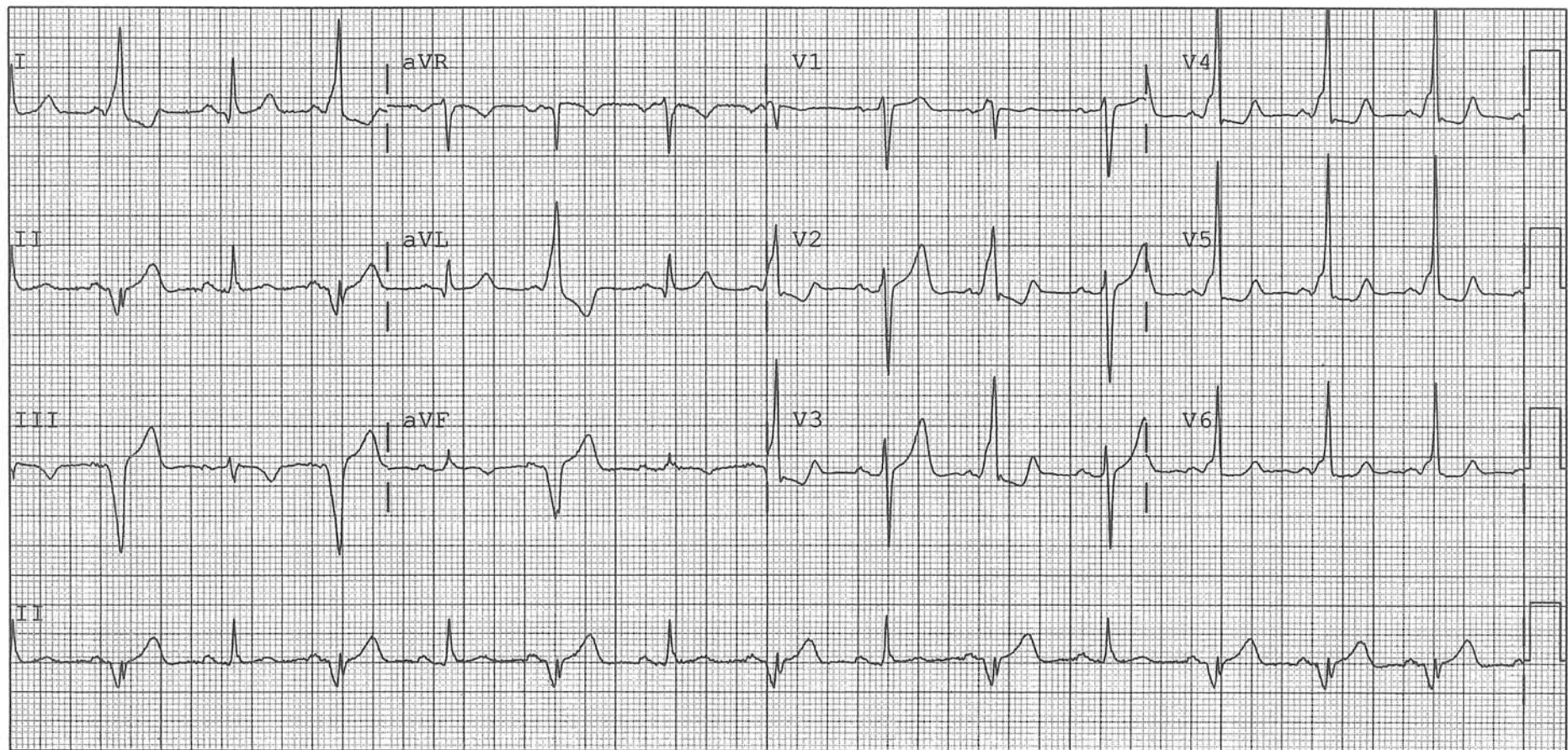
E





Ventricular preexcitation (Wolff-Parkinson-White) ECG pattern is recognized by a short PR interval and a slurred upstroke (or downstroke) of the initial portion of the QRS complex called a delta wave (A on the previous page). Some QRS complexes, without being preexcited, have a slurred upstroke like a delta wave, which can be called a pseudo delta wave, as illustrated in B-E. If this happens with ventricular paced complexes (E) or ventricular premature complexes (PVCs) without a P wave in front of them (D), it does not cause any confusion. If it happens with QRS complexes during sinus rhythm (B), it does not pose any problem either because the PR interval is not short, and the QRS complex is not wide. However, if it happens with a PVC with a sinus P wave in front of it (C), it can cause confusion by simulating a preexcited complex.

In the tracing below, during the first three fourth of the tracing, every other QRS complex has a short PR interval, a slurred upstroke and is wide. The tracing may reflect either ventricular bigeminy with a pseudo delta wave or preexcitation of every other beat and it cannot be settled. Fortunately, the last three consecutive QRS complexes have identical short PR interval and slurred upstroke, proving that it is preexcitation involving every other beat during the earlier part of the tracing.





# Concealed Conduction

## Introduction

Depolarization of the AV junctional tissue does not register any signal on the surface ECG because only a minute amount of tissue is involved. Thus, when there is a premature junctional depolarization (H') that fails to conduct to either the atria or ventricles because of physiologic refractoriness of the atrial and ventricular tissue, its presence is hidden from the surface ECG, and it is hence "concealed." However, by rendering the AV conduction system partially or completely refractory, this concealed H' exerts its effect on the conduction of the subsequent atrial impulse and causes either a prolonged PR interval or a blocked P wave. It is through this alteration of subsequent impulse conduction that a concealed H' can be suspected on the surface ECG.

The importance of recognizing a concealed H' is that it can simulate type I or type II 2° AV block.

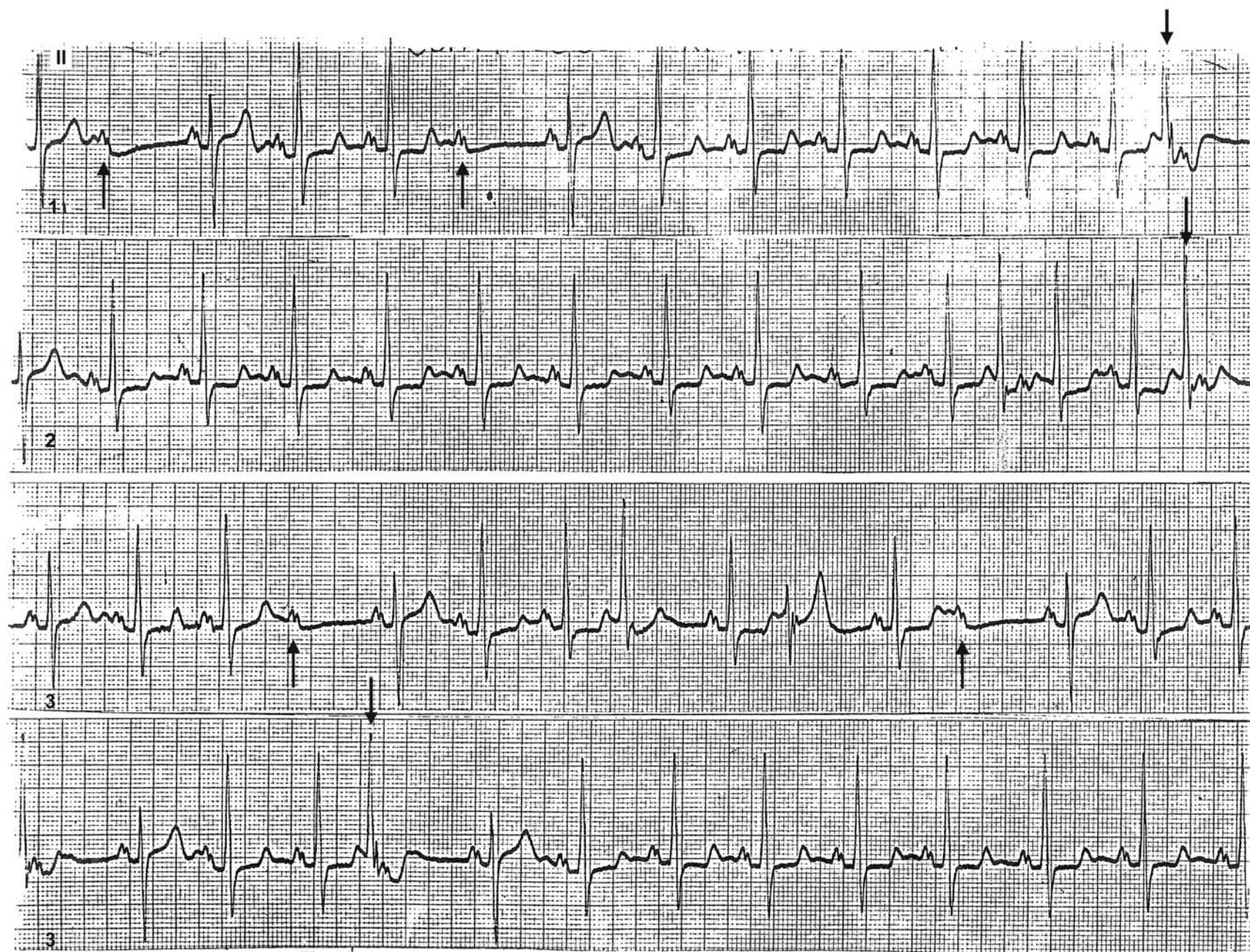
Another use of the term "concealed" is in "concealed bypass tract." In this situation, the patient has a bypass tract which is used only for retrograde conduction, setting up a re-entrant tachycardia. Since it is not used for anterograde conduction, the PR interval is not short and there are no delta waves during sinus rhythm. Thus, when in sinus rhythm, the surface ECG does not reveal the presence of this bypass tract; since it is "hidden" from the surface ECG, it is called a "concealed" bypass tract.

During atrial fibrillation, many atrial impulses penetrate into the AV junction. However, only some of these are conducted to the ventricles while many others are blocked. These blocked atrial impulses also exemplify "concealed" conduction because, from the surface ECG, these blocked atrial impulses are not seen.



## Concealed Junctional Premature Impulses Simulating Type II 2° AV Block

Many P waves (↑) are blocked suggesting Mobitz type II 2° AV block. Careful observation reveals frequent junctional premature complexes (J' ↓) with AV dissociation. If J' occurs at a time when the intraventricular conduction system is refractory, the impulse won't be conducted to the ventricles and no QRS will result. Thus, J' is completely hidden from the surface ECG (hence, concealed). In that case, the sinus P wave will stand alone, mimicking type II 2° AV block, as shown in this tracing. The consequence of not making the correct diagnosis may result in the patient unnecessarily receiving an artificial pacemaker, which unfortunately was what happened in this young patient.





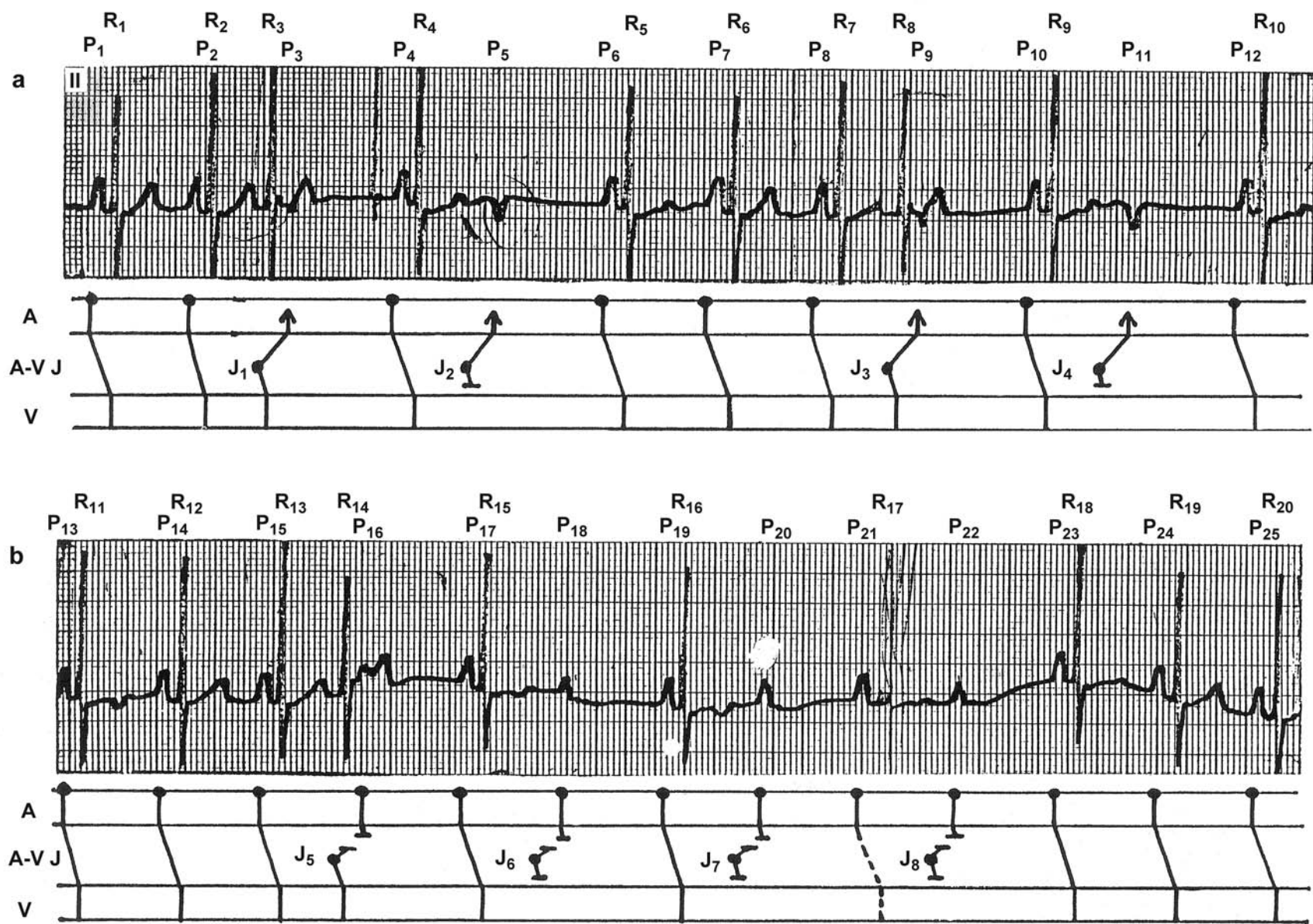
## Concealed Premature Junctional Impulses Simulating Type II 2° AV Block

This patient has many junctional premature beats with retrograde conduction to the atria (J1 and J3) or with AV dissociation (J5). When the junctional premature impulse is conducted to the atria, but not to the ventricles (J2 or J4), a negative P wave (P5 or P11) stands alone and is not accompanied by a QRS, suggesting AV block. The timing of J5 is such that it fails to capture the atria that have already been activated by the sinus impulse. The result is a positive P wave (P16), instead of a negative P wave, and there is AV dissociation at that moment. In this setting, if the junctional premature impulse fails to conduct to the ventricles, as happens with J2 or J4, it will be completely hidden or concealed from the surface ECG, i.e., there is no QRS or retrograde P wave from the junctional premature impulse (J6). In that situation, a positive P wave induced by the sinus node impulse (P18) will stand alone and not be accompanied by a QRS, mimicking Type II 2° AV block. That is what happens with J7 and J8 as well, simulating a bout of 2:1 AV block.

Without the manifest junctional premature complexes (R3, R8 or R14), the same conclusion may not have been reached.

The reason J1, J3 and J5 are conducted to the ventricles while J2, J4, J6, J7 and J8 are not is explained by the fact that the latter junctional premature impulses are preceded by a longer R-R interval compared to J1, J3 or J5 and land in the refractory period which has now lengthened (the length of the refractory period is proportionally related to the preceding R-R cycle length). Two additional observations are also worth mentioning. First, there are two families of T waves; one is tall and upright, while the other is low or diphasic. This is due to the different preceding R-R cycle lengths, which affect the ventricular repolarization. The low or diphasic T waves are always preceded by a longer R-R cycle, while the tall and upright T waves are preceded by a regular R-R cycle. The second observation is that R17 is not registered. However, since a T wave is present, albeit of low voltage, one can be certain that the R17 indeed occurred. The stylus of the ECG machine simply failed to burn the paper because it was folding at that very moment.

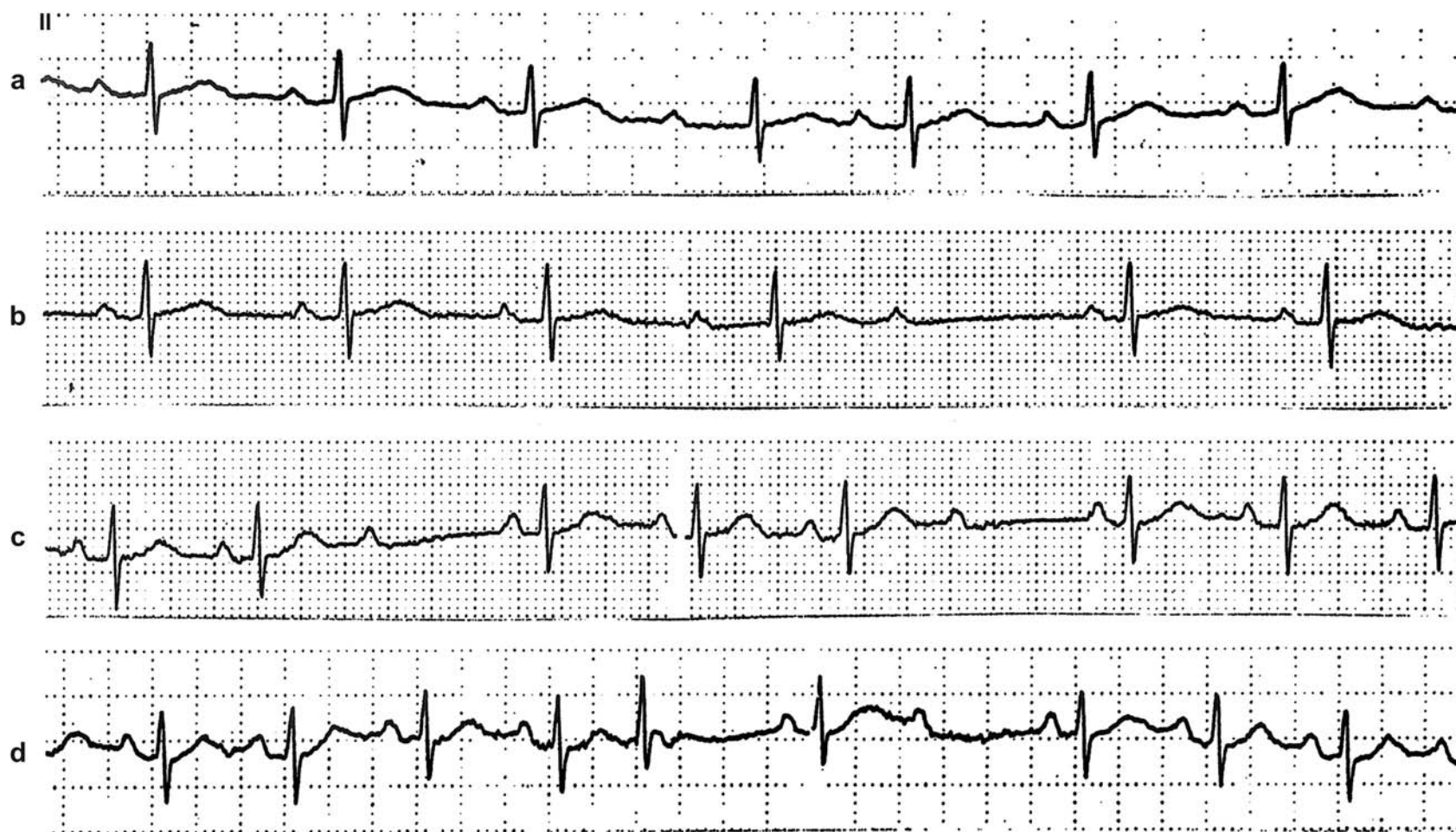
This interesting example contains all the tools to visualize the concept of concealed conduction.



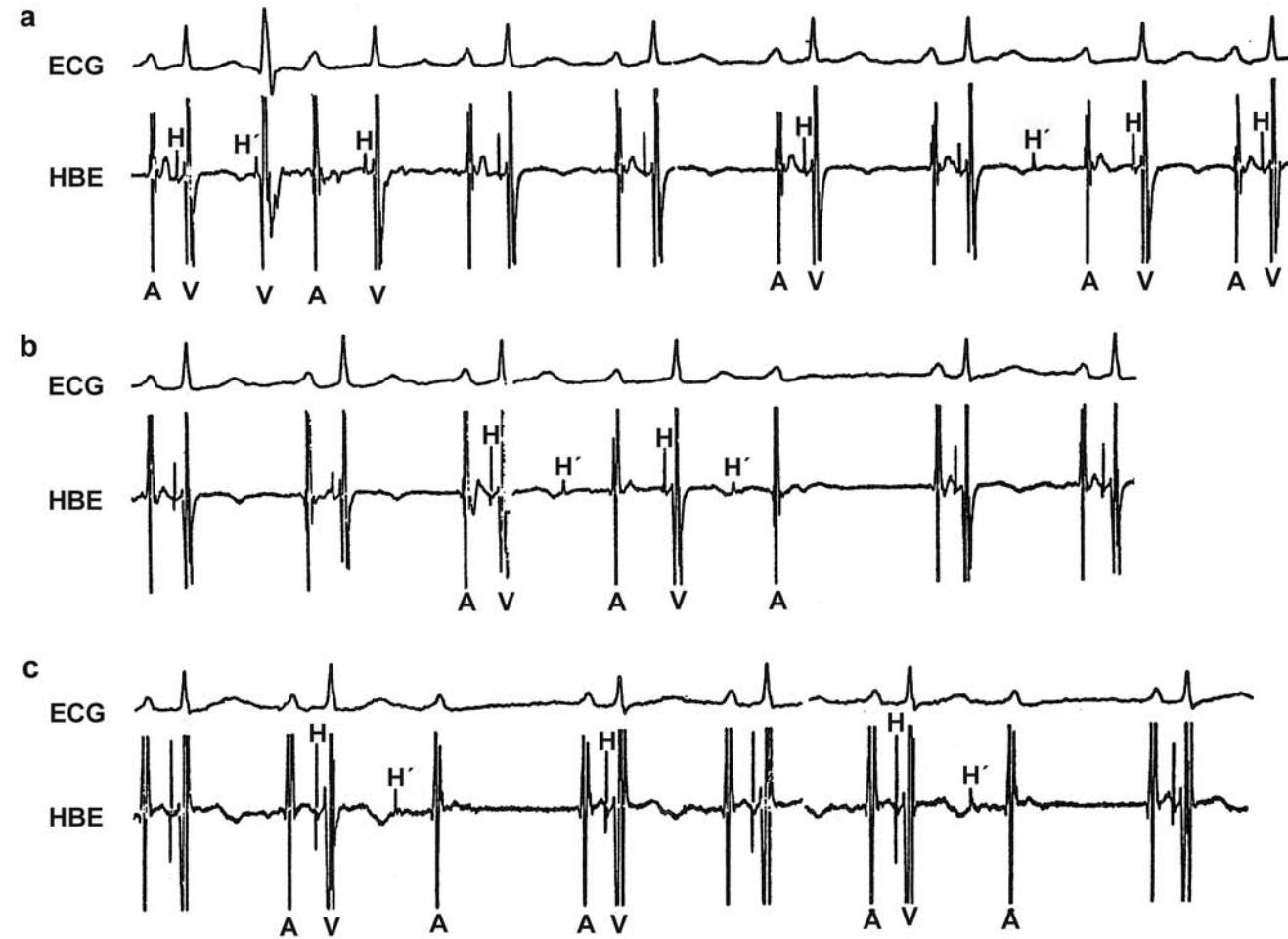


## Various Manifestations of Concealed Junctional Beats

ECG strips from a Holter recording. (a) Sudden, unexplained prolongation of the PR interval with the fourth P wave. (b) the PR interval is short with the third P wave, long with the fourth P wave, and the fifth P wave is blocked (apparent type I second-degree AV block). (c) The third and seventh P waves are blocked without preceding PR prolongation (apparent type II second-degree AV block). (d) The fifth QRS complex occurs prematurely with a slightly different morphology, suggestive of an AV junctional premature beat with aberrant conduction. See corresponding His recordings on next page .



His bundle recording from the same patient shown on the preceding page.

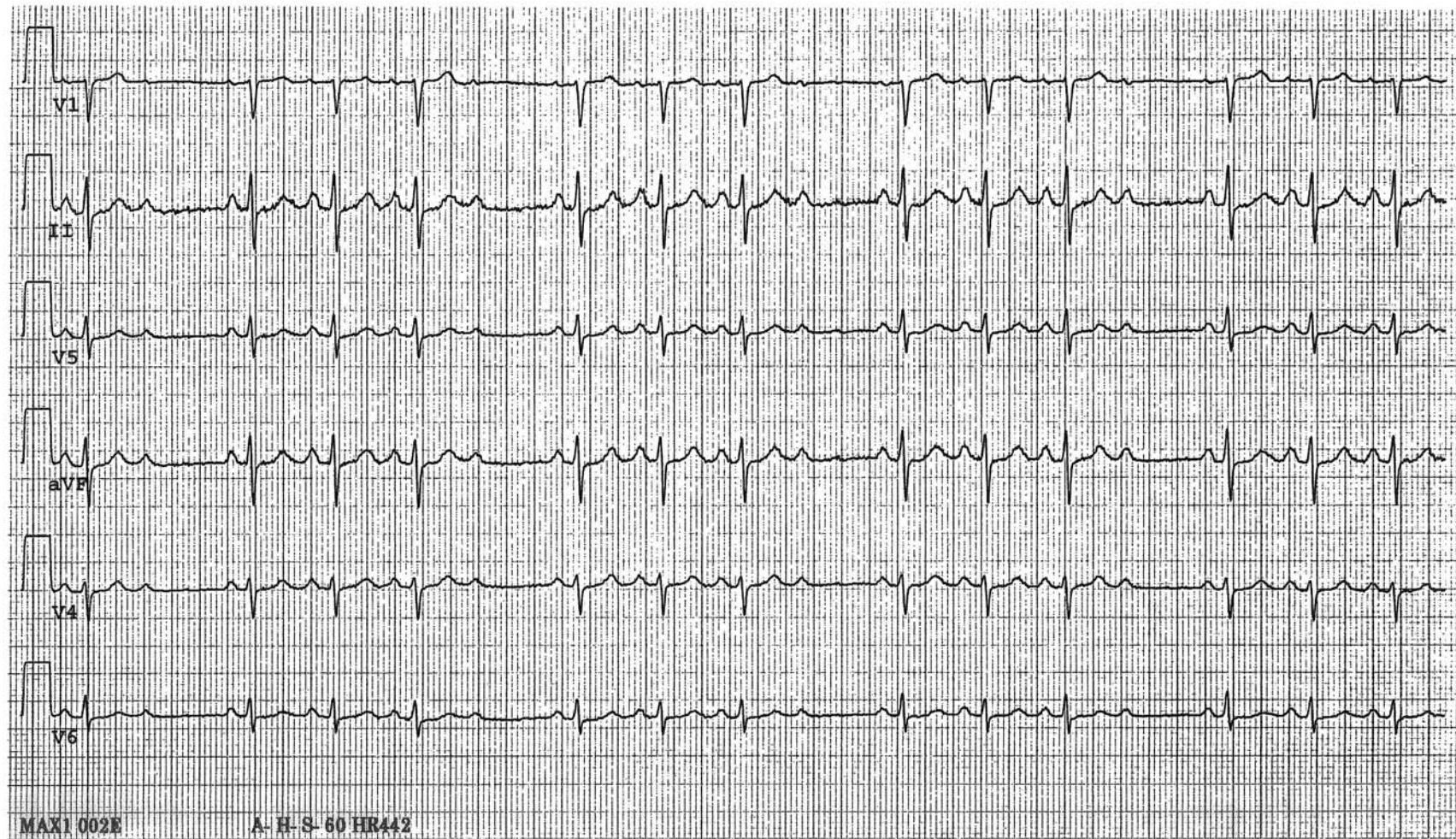


Strips of simultaneously recorded ECG lead I (ECG) and His bundle electrogram (HBE) from patient on preceding page. (a) The second QRS is preceded by an H', indicating that it is a premature junctional beat with aberrant conduction. This causes the subsequent PR interval to be prolonged. Another H' near the end of the strip is non-propagated (concealed) but causes prolongation of the subsequent PR interval, just as the manifest H' does at the beginning of the strip. (b) The first H' causes the following PR interval to be prolonged. The next H' causes the following P waves to be blocked, simulating type I second-degree AV block on the surface ECG. (c) Both H's cause their following P waves to be blocked, simulating type II second-degree AV block on the surface ECG.

A: Atrial depolarization; V: ventricular depolarization; H: His bundle depolarization from normal sinus impulse; H': premature His bundle depolarization.

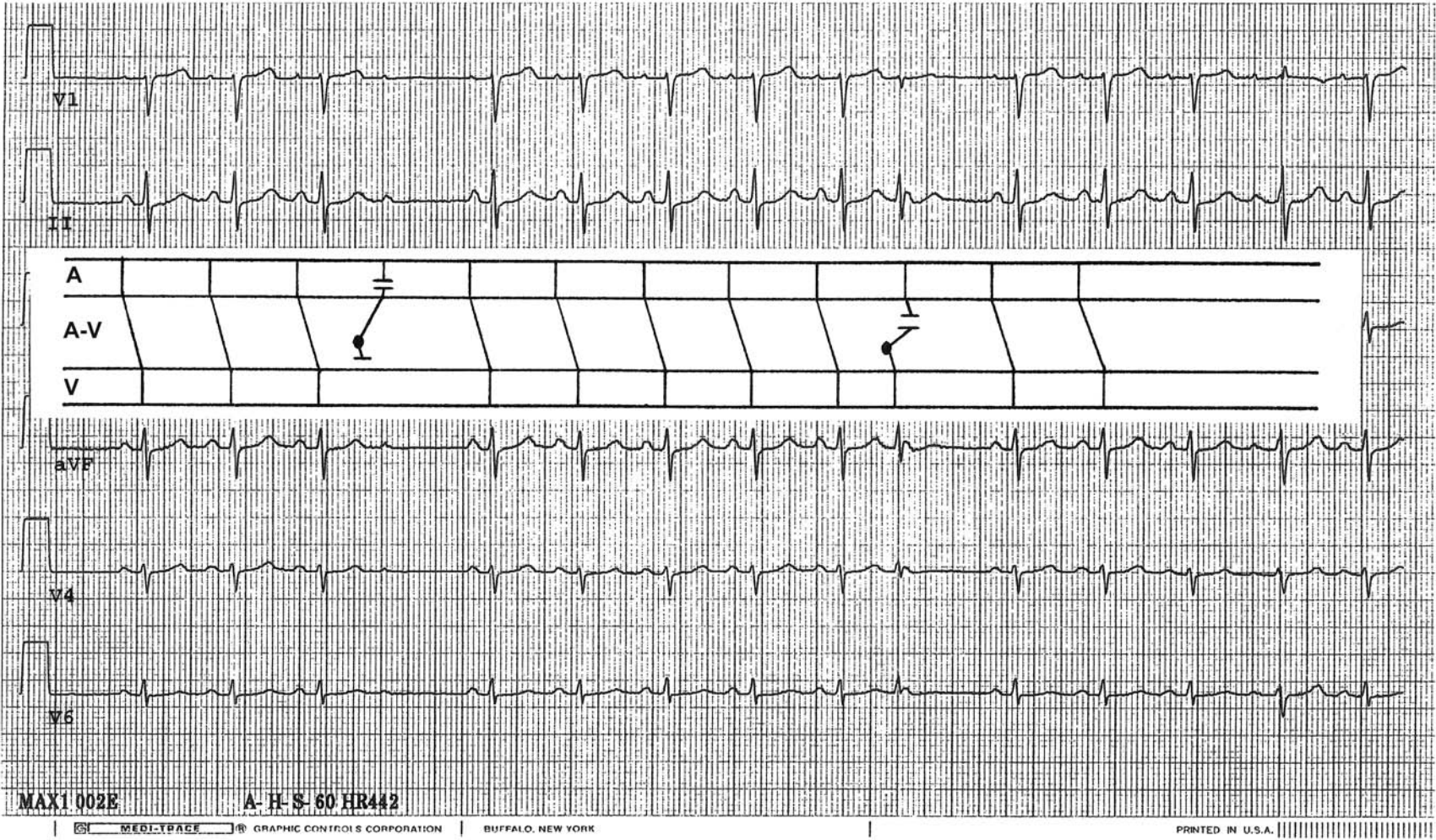


## Concealed Junctional Premature Impulses Causing Findings Suggestive of Type II 2° AV Block

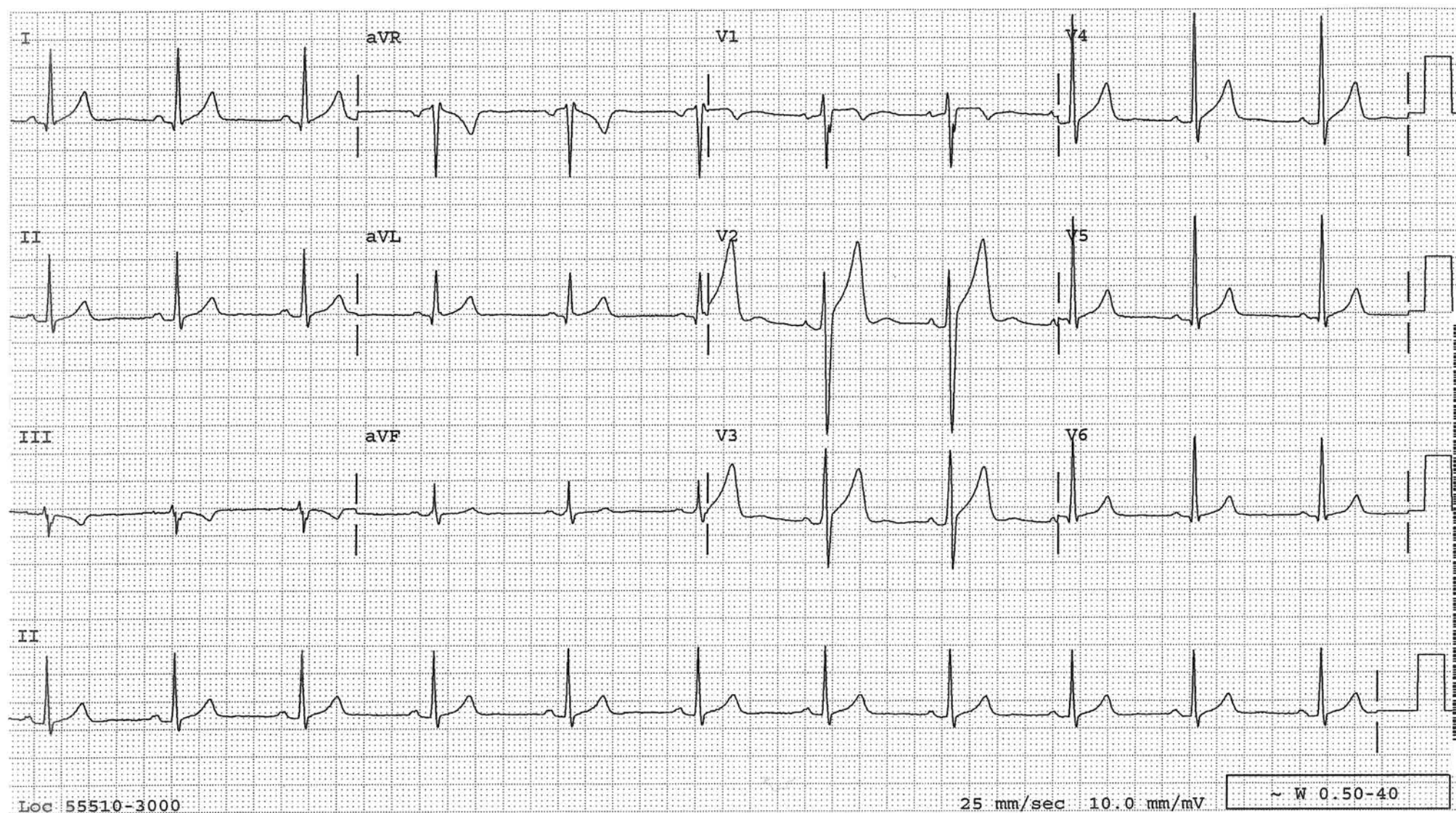


During a treadmill stress test, every 4<sup>th</sup> P wave is blocked without PR intervals lengthening suggesting Type II 2° AV block. The stress test was stopped for the fear of myocardial ischemia manifesting this way. However, it turned out to be due to concealed (non-conducted) junctional premature impulses evidenced by a manifested junctional premature beat as diagrammed in the latter part of the next tracing. The morphology of the "blocked" P wave in the early part of the tracing is different from other P waves indicating it is an atrial fusion, which also supports the presence of a concealed (non-conducted) junctional premature impulse at that time.



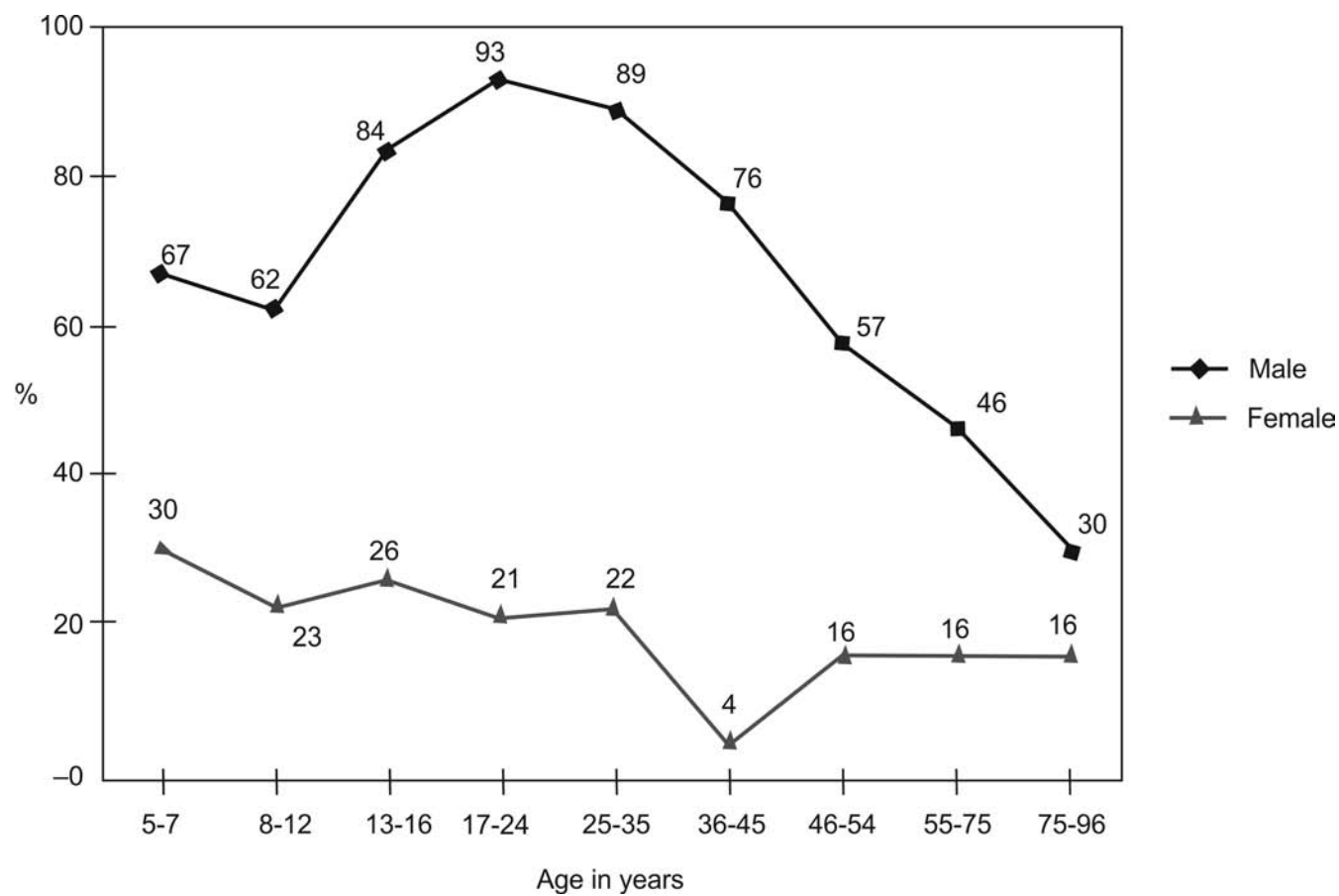






### Prevalence of Normal ST-Elevation in V1-4

Prevalence of  $\geq 1$  mm ST-elevation in one or more V1-4 leads (normal male pattern) in normal ECGs from 529 males and 544 females.



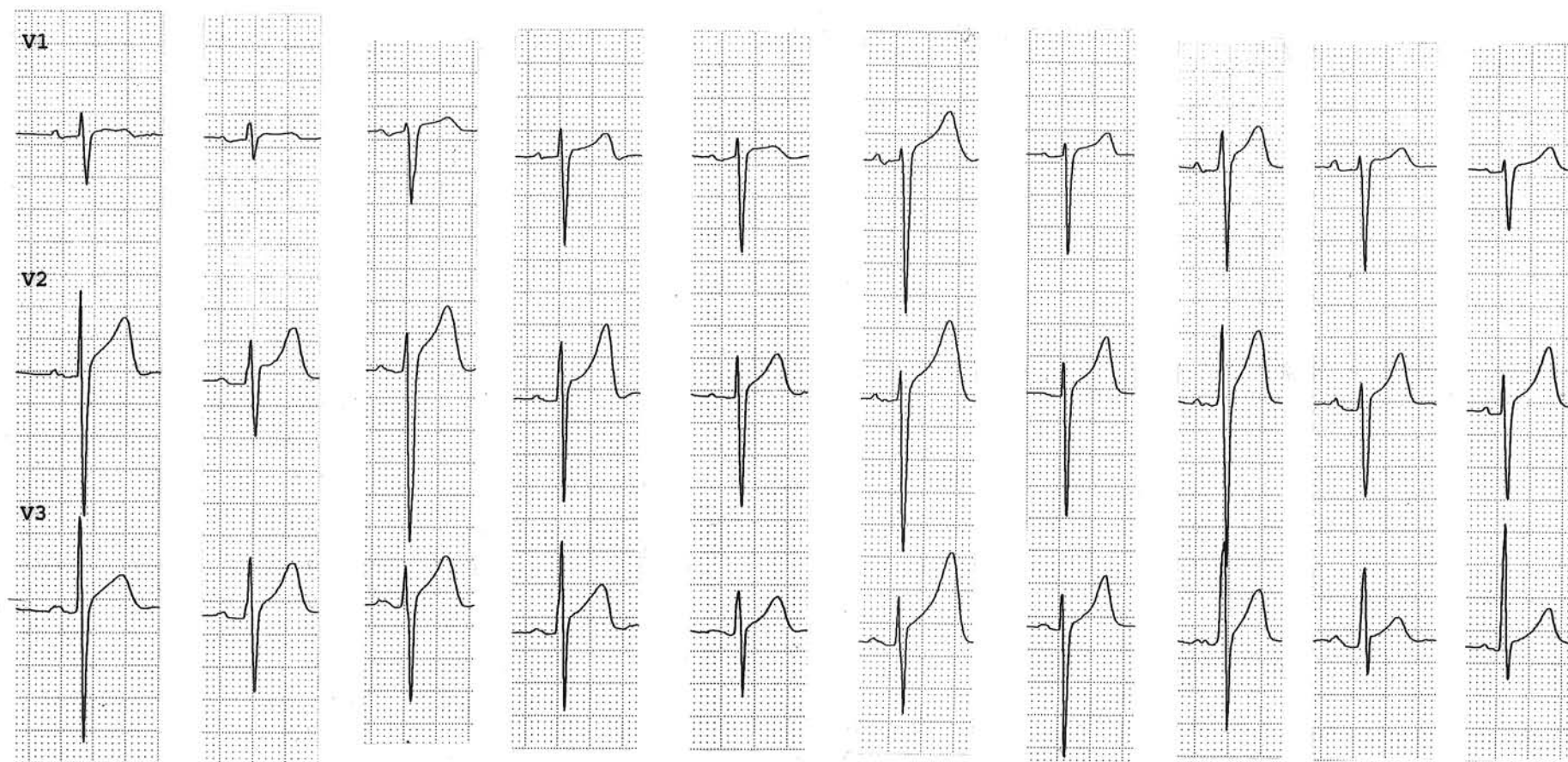
Surawicz et al. JACC. 2002;(40):1870.

From another study, 91% of 6,014 healthy men (age 16-58 years) in the US Air Force had 1-3 mm ST-elevation in one or more precordial leads.

Hiss et al. AM J Cardiol. 1960;(6):200.



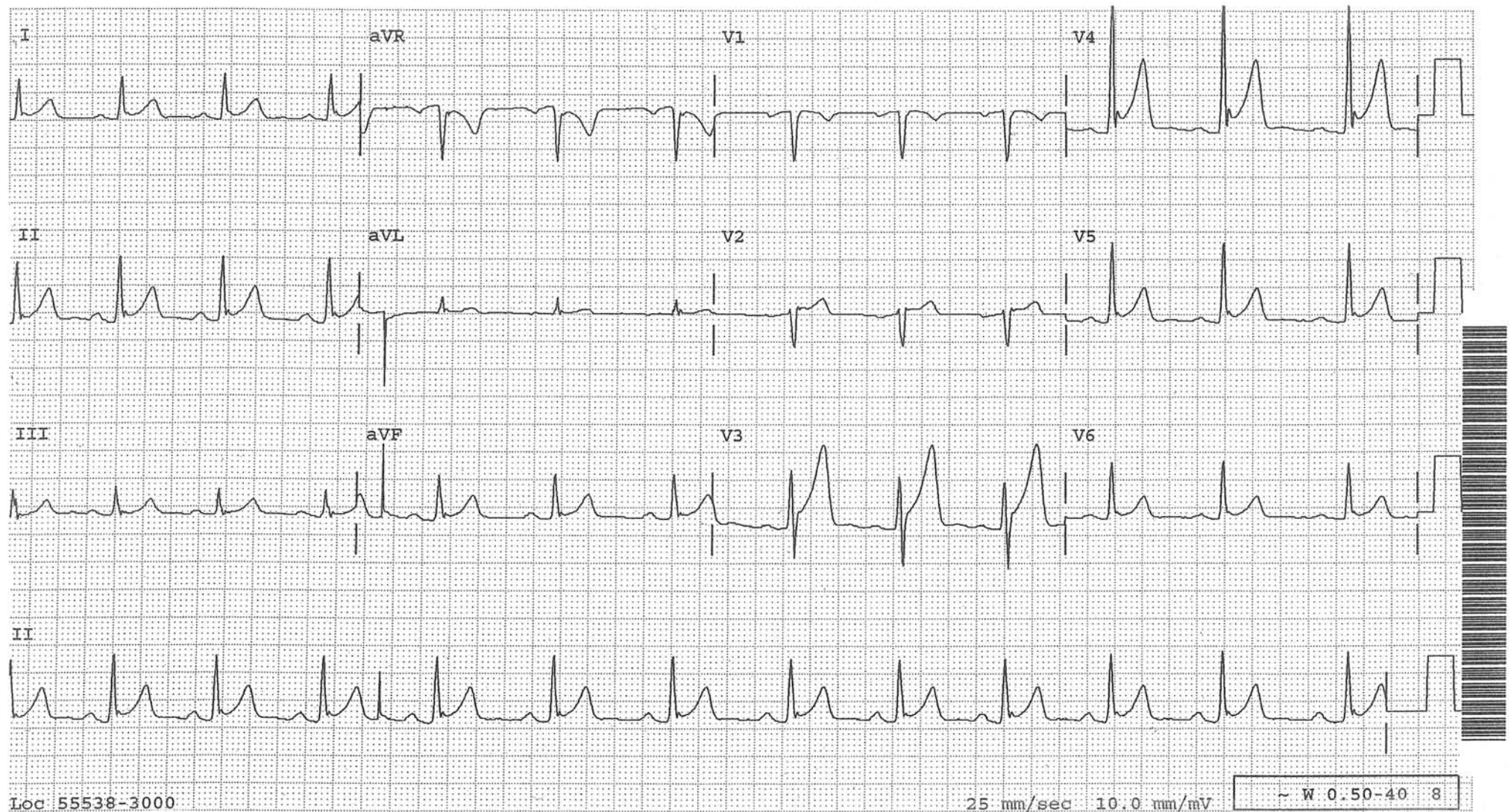
More examples of normal ST-segment elevation in leads  $V_{1-3}$  from ten different patients with no cardiac problems. Note that the ST-segments are concave upward.





## Early Repolarization Pattern as a Normal Variant

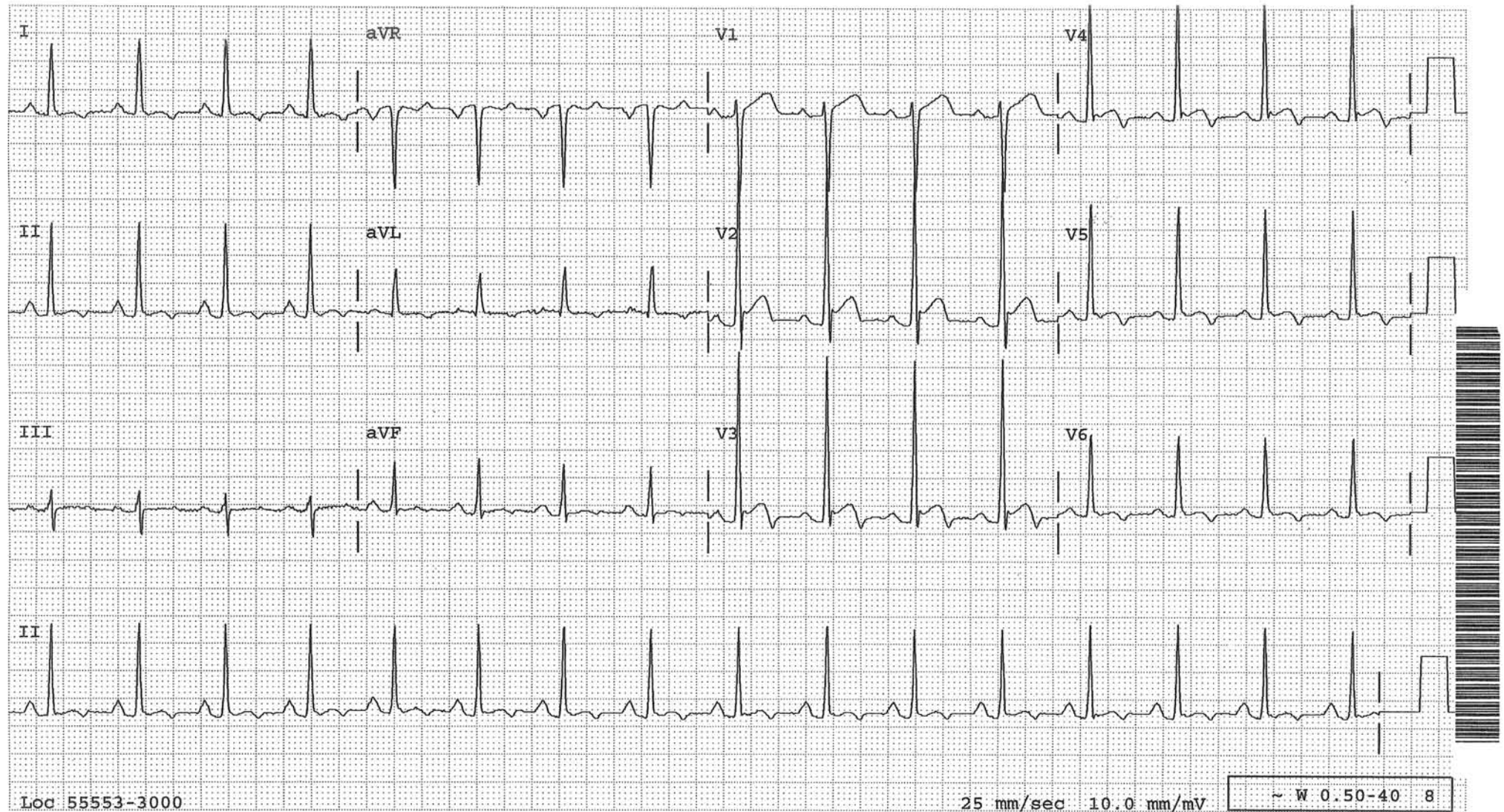
ST segments are elevated in many leads, especially in V3 and V4. There is a notch at the J point in V4. T waves are upright and tall. The PR segment is mildly depressed. Often limb leads are also involved. If so, the ST segment is more elevated in lead II than in lead III.





## ST Elevation of “The Other” Normal Variant

This is another form of ST-elevation as a normal variant. ST segments are elevated in mid precordial leads. There is a notch at the J point in  $V_{3-4}$ . This entity is distinctly different from the early repolarization pattern in that T waves are upright and tall in the latter while they are inverted in this entity. The ST segment tends to be coved, while it is concave in the early repolarization pattern. The QT interval tends to be short. Limb leads can also be involved. The ECG findings certainly can be mistaken for acute pericarditis or infarction if one is not aware of this entity. This entity occurs almost exclusively in black men (4%) It is seen in 1% of black women and hardly any in other races.

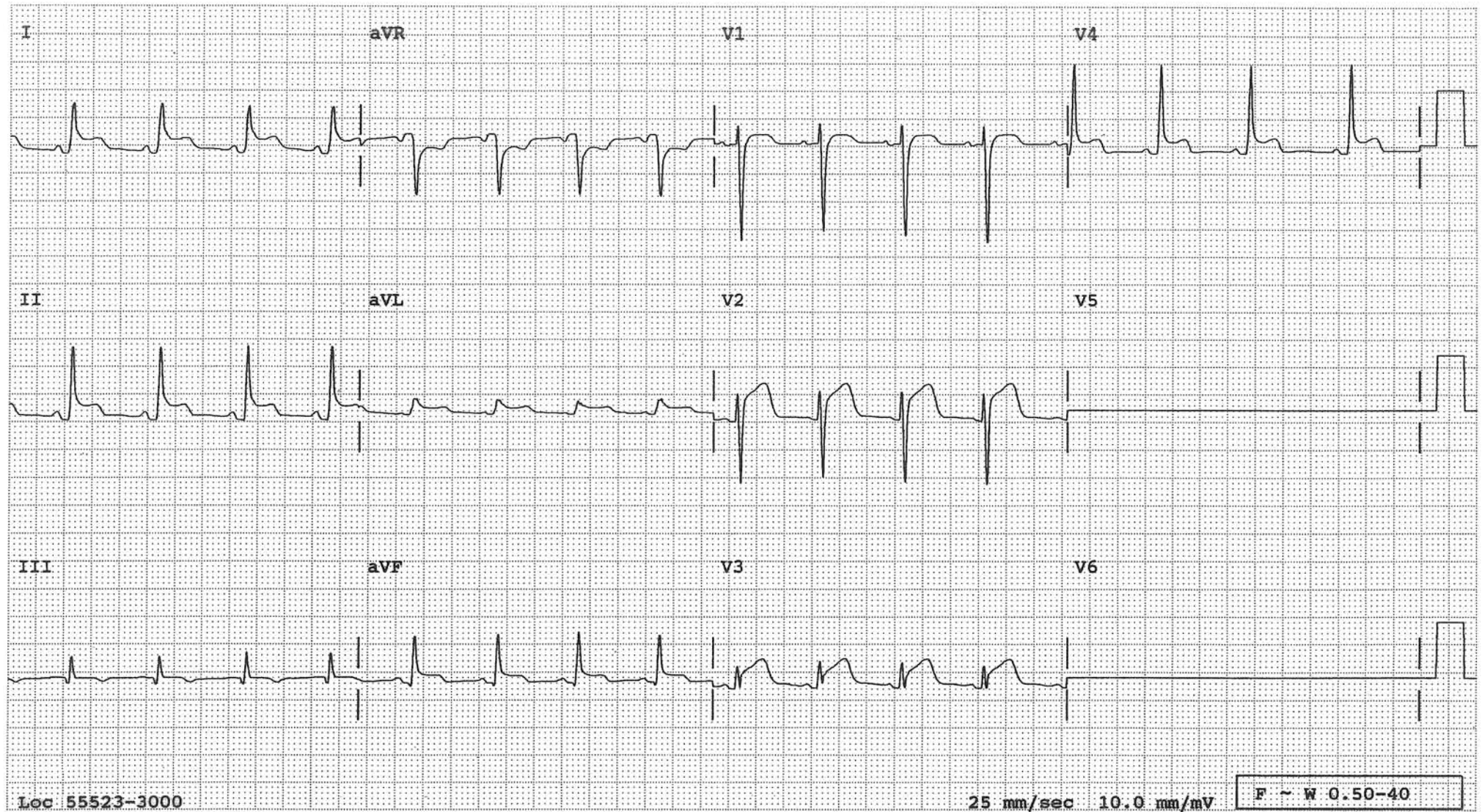




## Acute Pericarditis

- Diffuse ST elevation involving more than one coronary vascular territory.
- PR-segment depression (atrial counterpart of ST elevation)

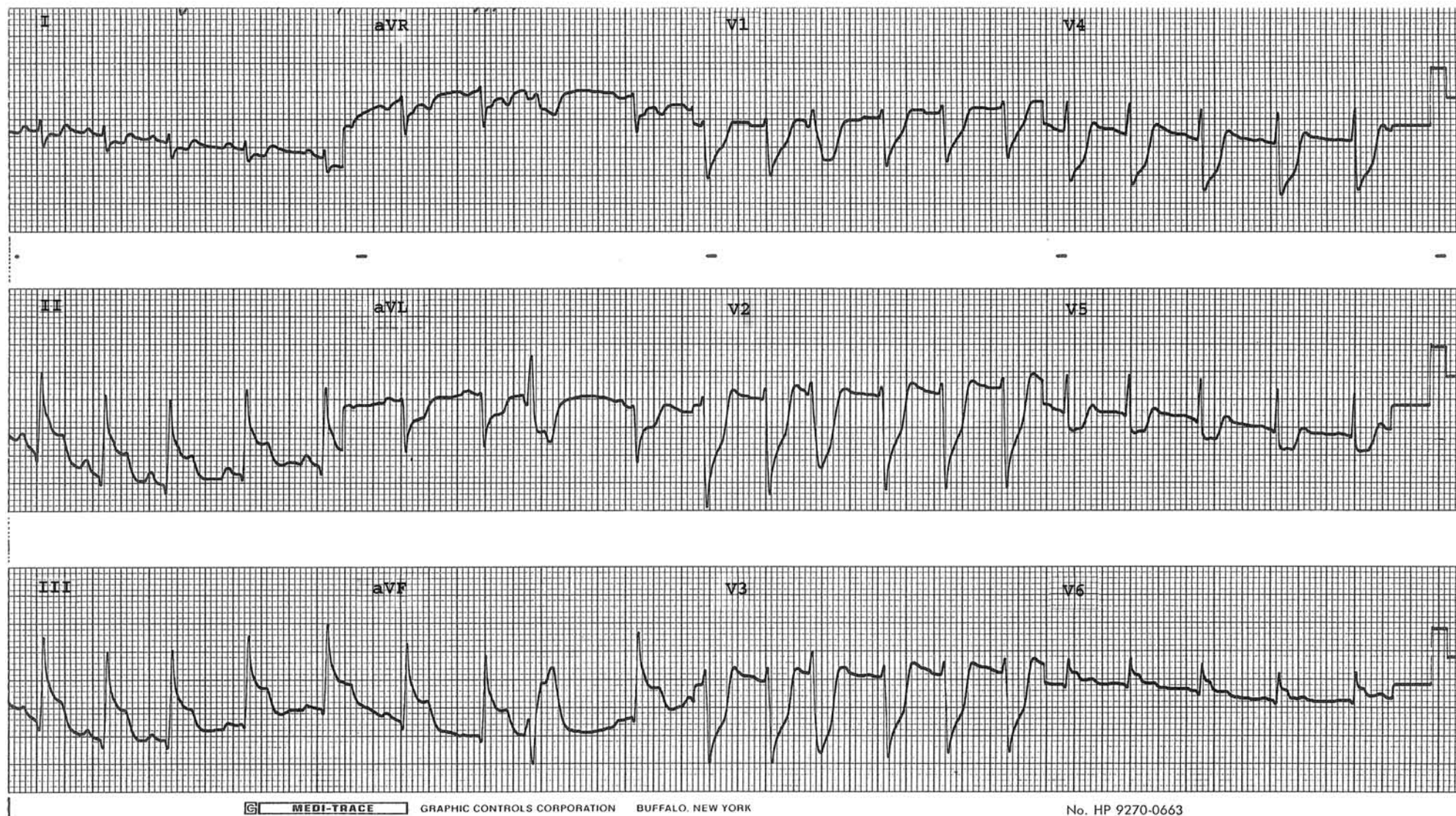
The axis of the ST segment in pericarditis is parallel to the anatomical axis of the heart, which is approximately  $45^\circ$  on the frontal plane. Therefore, the ST segment will often register as ST elevation in both leads III and aVL. (In inferior or lateral infarction, the ST elevation in one lead will register as depression in the other lead.) Besides, the ST elevation is more marked in lead II than in lead III.





## Prinzmetal's Angina

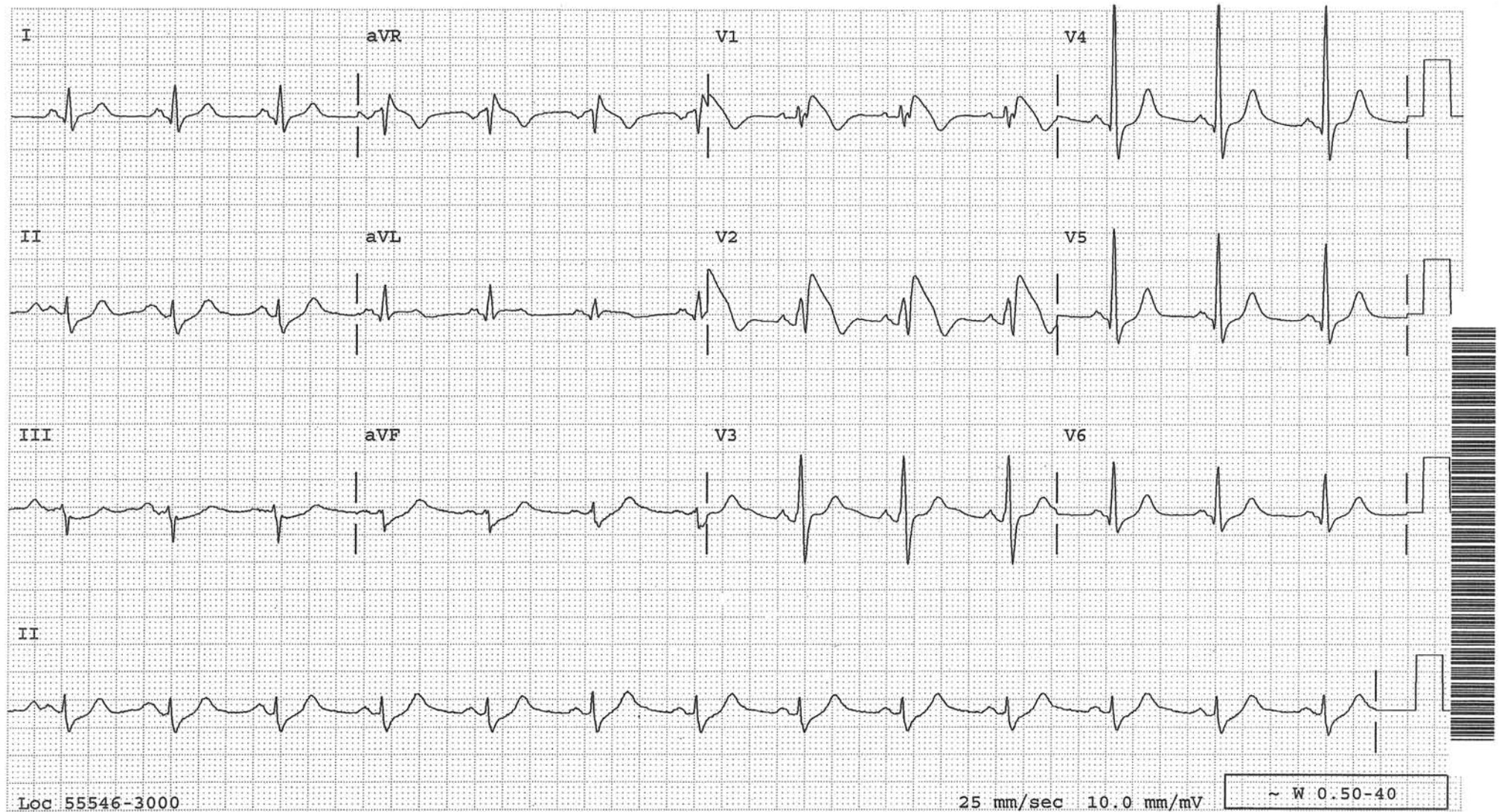
Marked ST elevation in the inferior leads and ST depression in the precordial leads reflecting transmural infero-posterior ischemia during the right coronary artery spasm. A repeat ECG 30 minutes later reveals normalization of all these changes.





## Brugada Syndrome

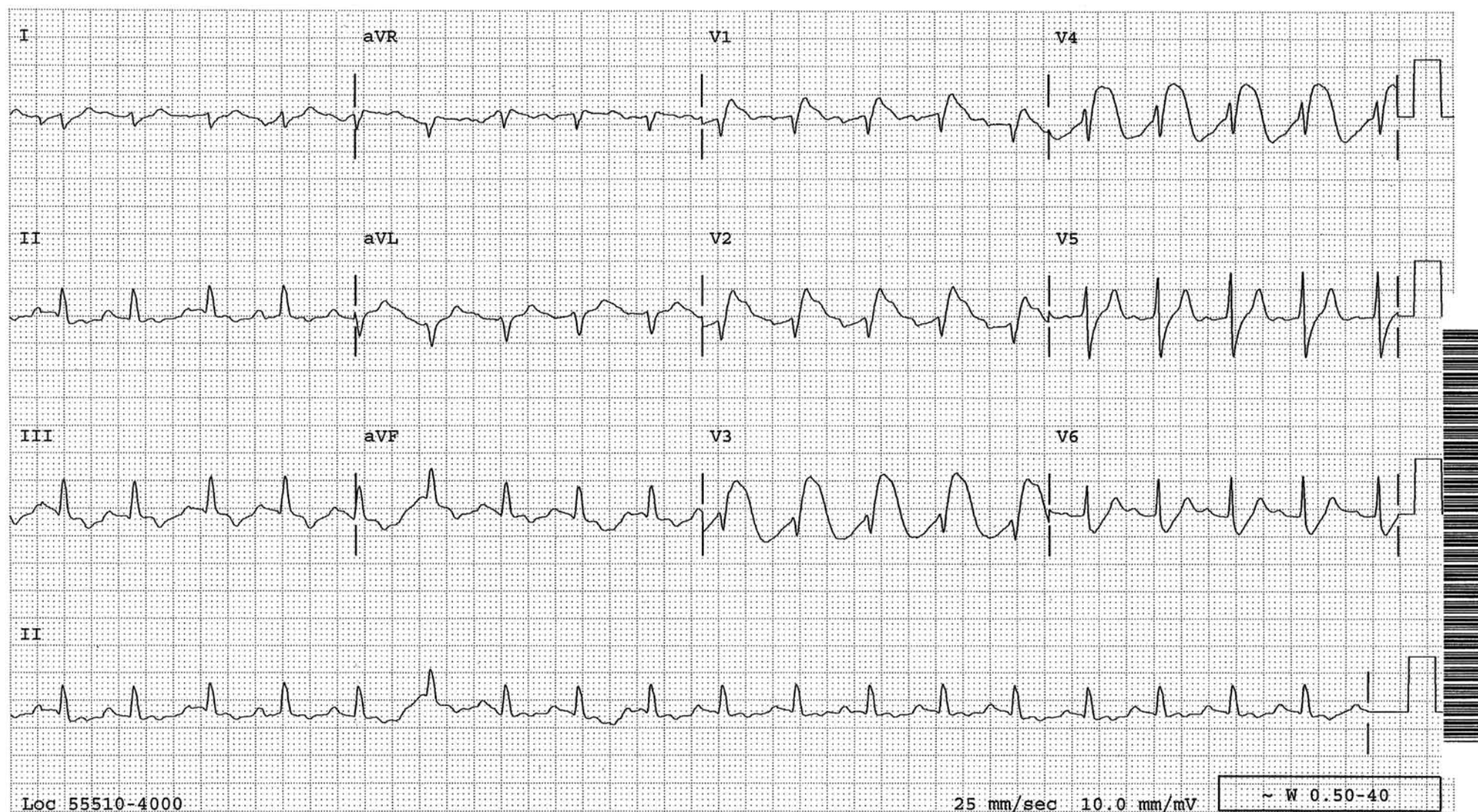
Typical or atypical RBBB, downsloping ST segment which begins from the top of R', ending with an inverted T wave, primarily seen in leads V1-2, are characteristic features of this syndrome. This syndrome has been linked to mutations in the cardiac sodium-channel gene (a channelopathy), and accounts for 40 to 60 percent of all cases of primary ventricular fibrillation.





## Massive Pulmonary Embolism Simulating Acute Anterior Infarct

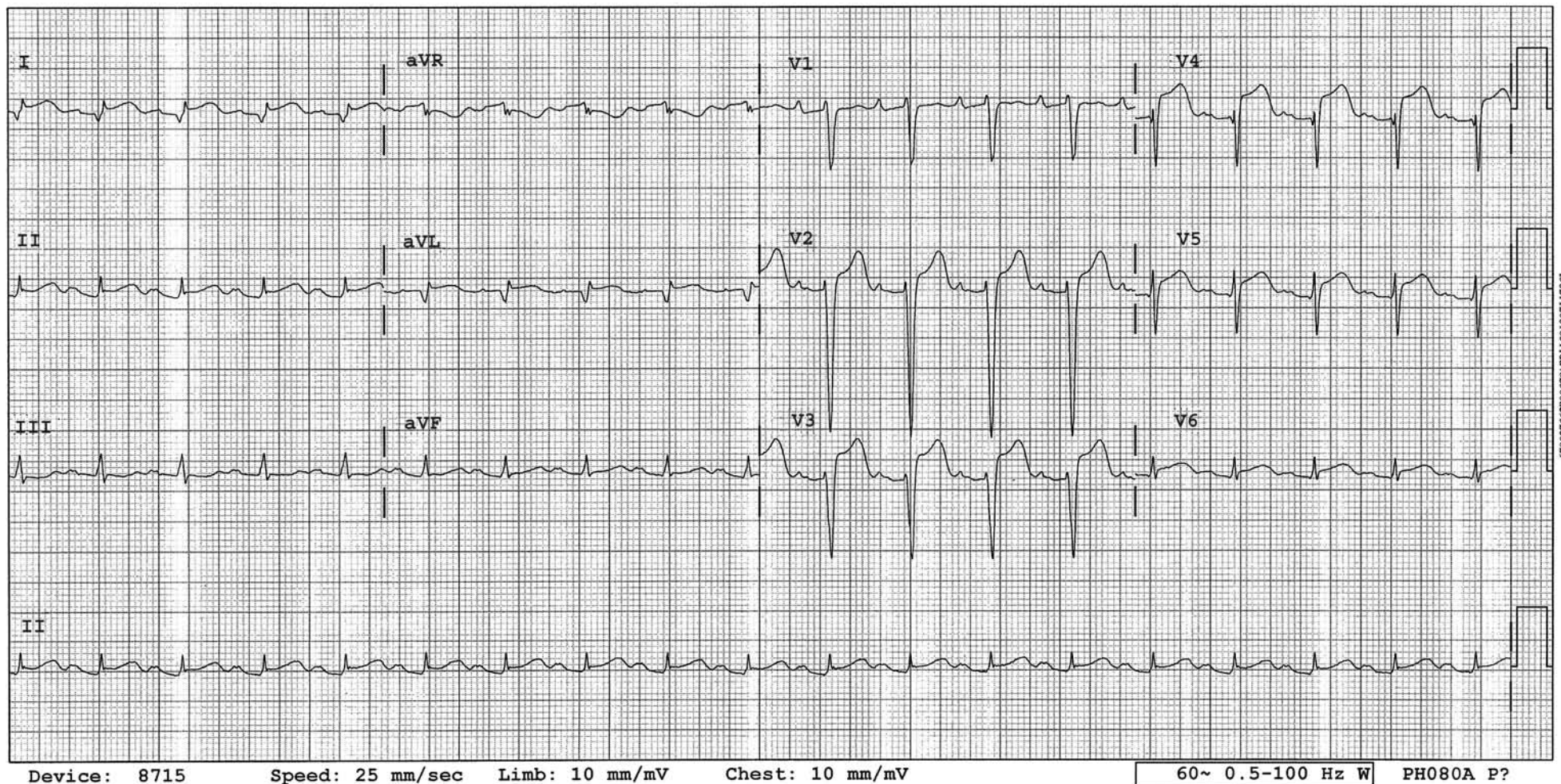
The ECG findings were highly suggestive of acute anterior infarction. However, the coronary angiogram was completely normal. Pulmonary angiogram showed massive pulmonary embolism. ECG findings reflect whatever is happening beneath the electrodes. Most likely the overloaded and ischemic right ventricle was markedly dilated at the time occupying most of the anterior portion of the heart which lies beneath V1-V4 leads resulting in the ECG findings seen here.





## Stress Cardiomyopathy

Intense emotional or physical stress or CNS events can precipitate an acute and rapidly reversible left ventricular dysfunction, more often in elderly women, called stress cardiomyopathy. This tracing is from an elderly woman who lived alone, fell in the bathroom and could not get up for several hours while staying alert the whole time; a perfect setup for this entity. The ECG on admission showed ST-segment elevation in antero-lateral leads highly suggestive of acute infarction. However, the coronary angiogram was normal. On the left ventriculogram and echocardiogram, the distal half of the left ventricle was ballooned out which is a typical finding in this entity, hence also called transient apical ballooning syndrome, or since the left ventricular cavity contour resembles a Japanese octopus trap, takotsubo, takotsubo cardiomyopathy. Typical ECG features are diffuse, deep T wave inversion with a long QT interval, the so-called neurogenic T wave changes. However, initially ST-segment elevation which is indistinguishable from that of acute infarction may be seen as in this case. Mild troponin rise is common. The mechanism is not well understood, but catecholamine surge seems to be the common denominator of this entity.

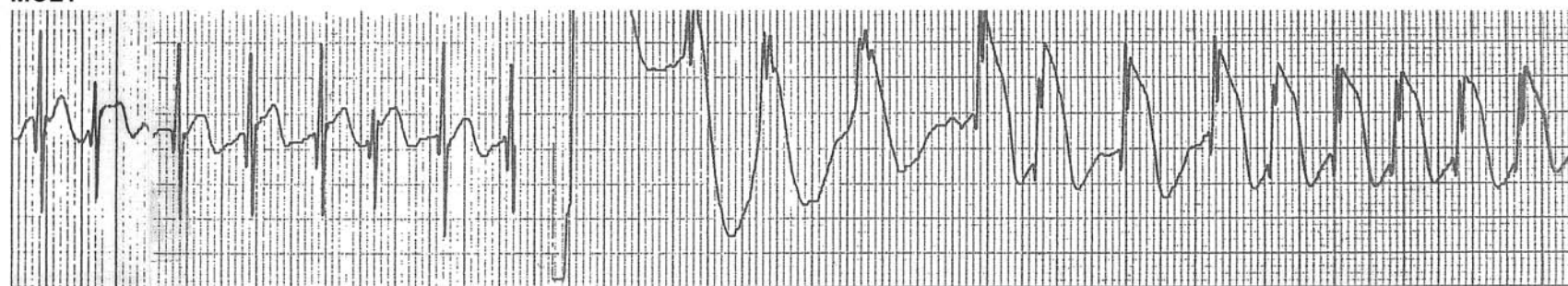




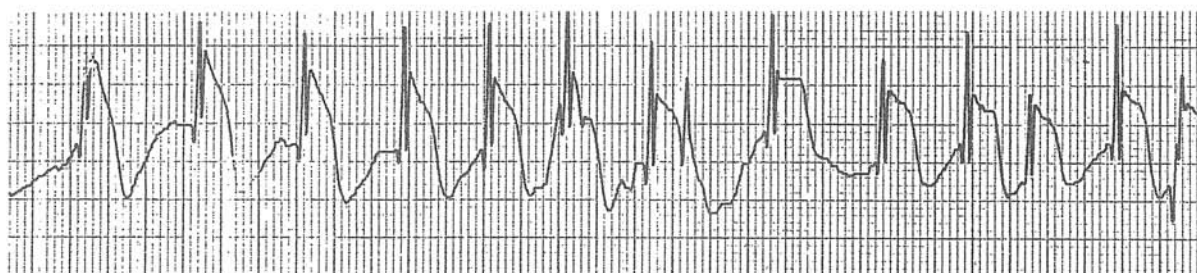
### Transient ST Elevation Following D.C. Shock

Transient, marked ST elevation following D.C. cardioversion without any apparent evidence of myocardial damage.

MCL1



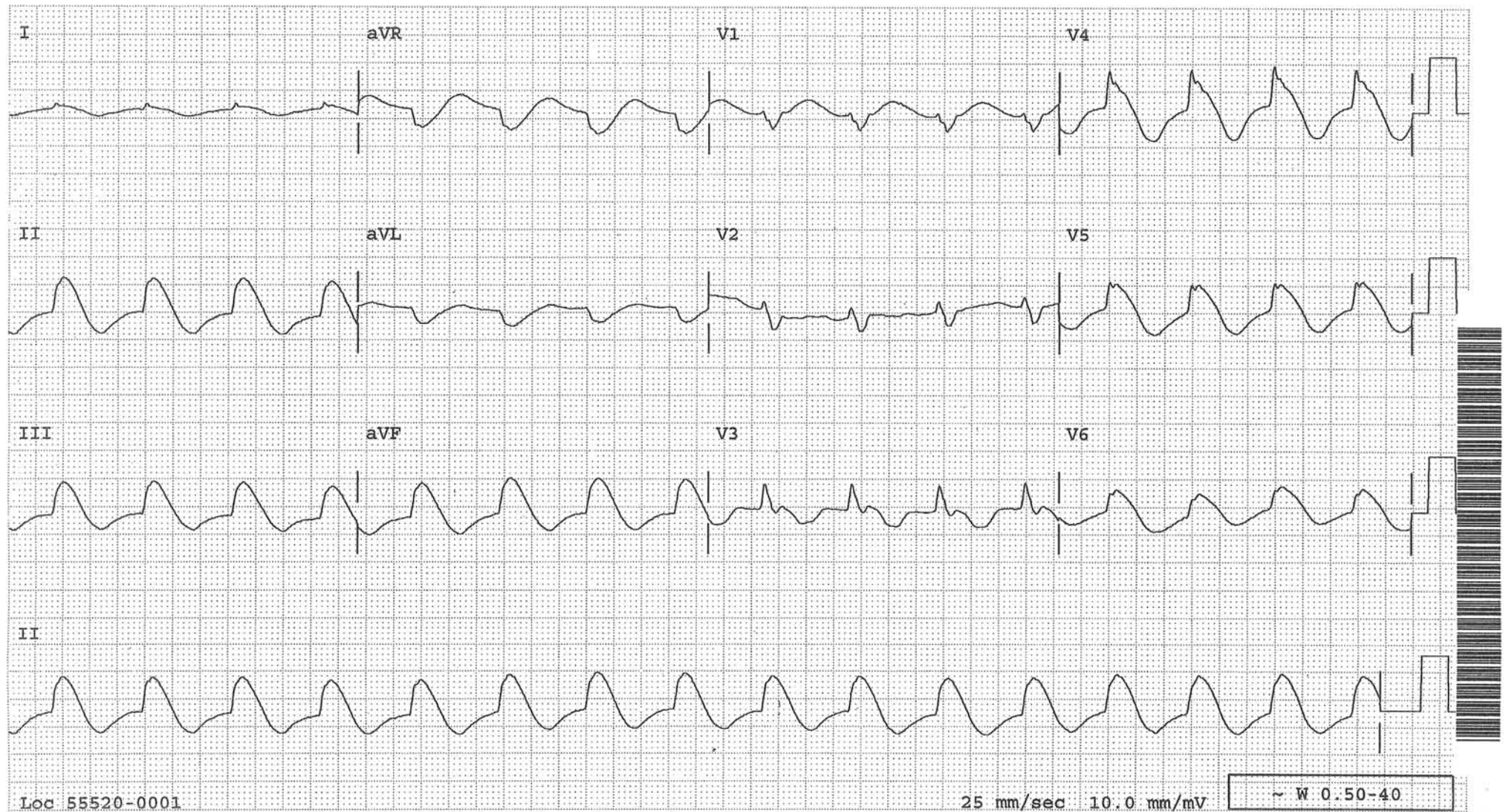
D.C. Shock





## “Metabolic” ST Elevation

ST-segment is elevated in many leads. It begins from the top of the R wave and is downsloping, ending with an inverted T wave. These findings are seen in a variety of severe metabolic derangements. The elevated ST segment from an acute infarction is more often upsloping or plateauing with a shoulder, not down sloping. This tracing is from a patient who had rhabdomyolysis, renal failure, acidosis, and hyperkalemia from smoke inhalation and burns.

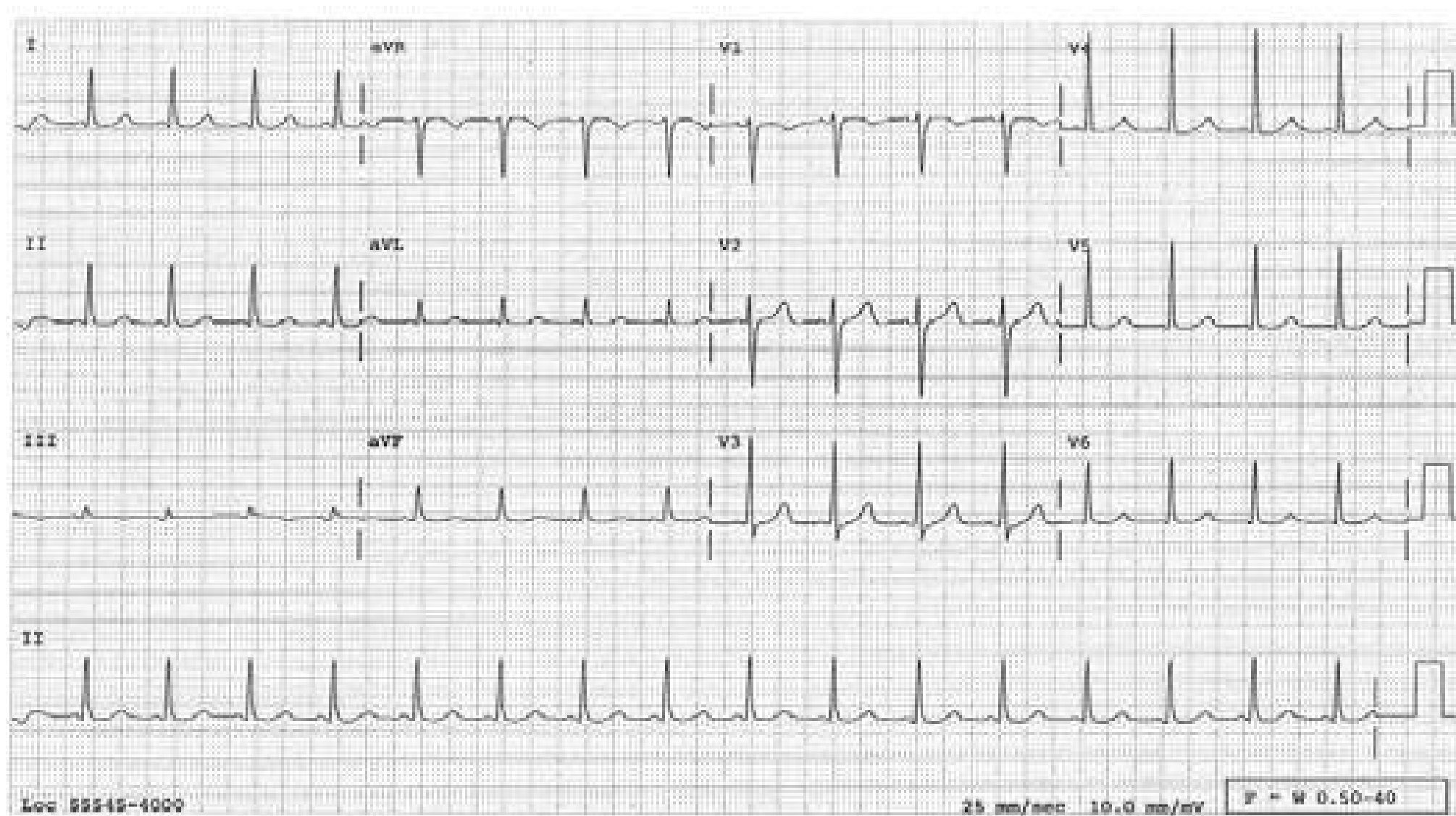




## MISCELLANEOUS

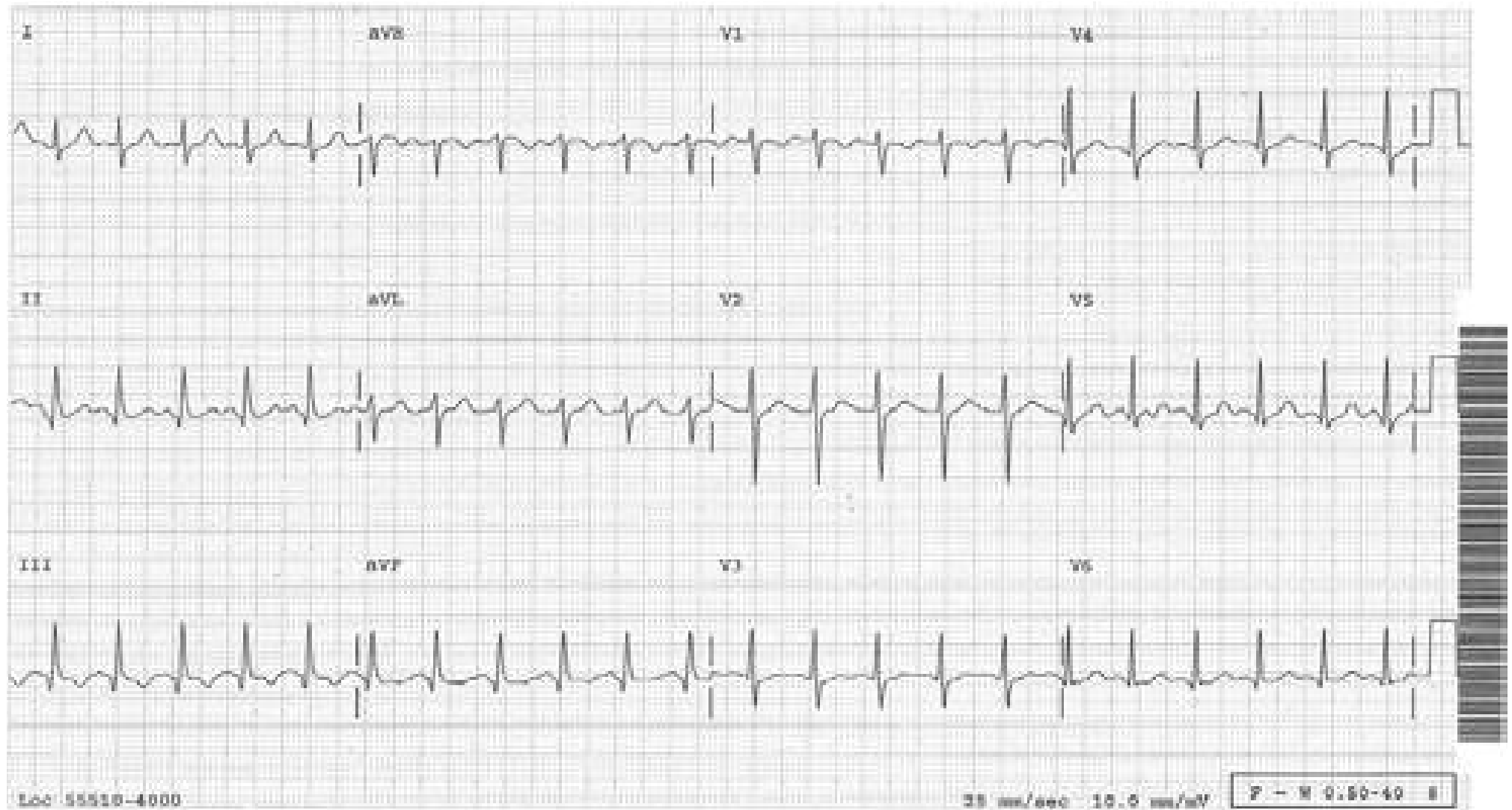
### Accelerated AV Conduction

The P wave vector is normal but the PR interval is shorter than 120 msec with no delta waves. The short PR interval may be due to enhanced AV nodal conduction ("greasy" AV node) and is considered as one end of the normal spectrum for PR interval, and is benign.



## Acute Cor Pulmonale

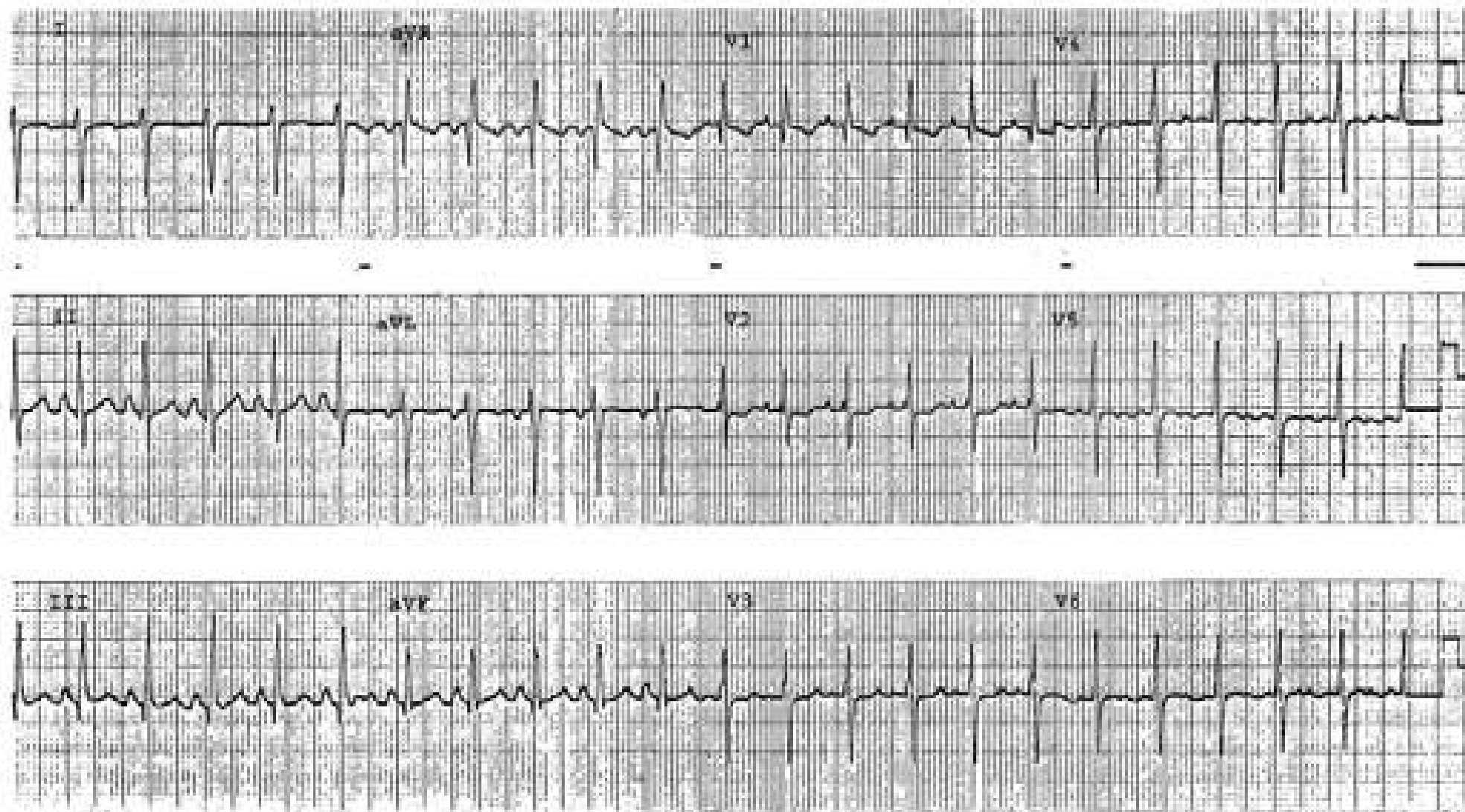
An S wave is present in lead I. In lead III, there is a q wave and the T wave is inverted, hence called  $S_1Q_3T_3$  pattern. This pattern combined with sinus tachycardia is highly suggestive of pulmonary embolism. This pattern is the ECG manifestation of acute right ventricular overload. The Q wave is not wide in this pattern.





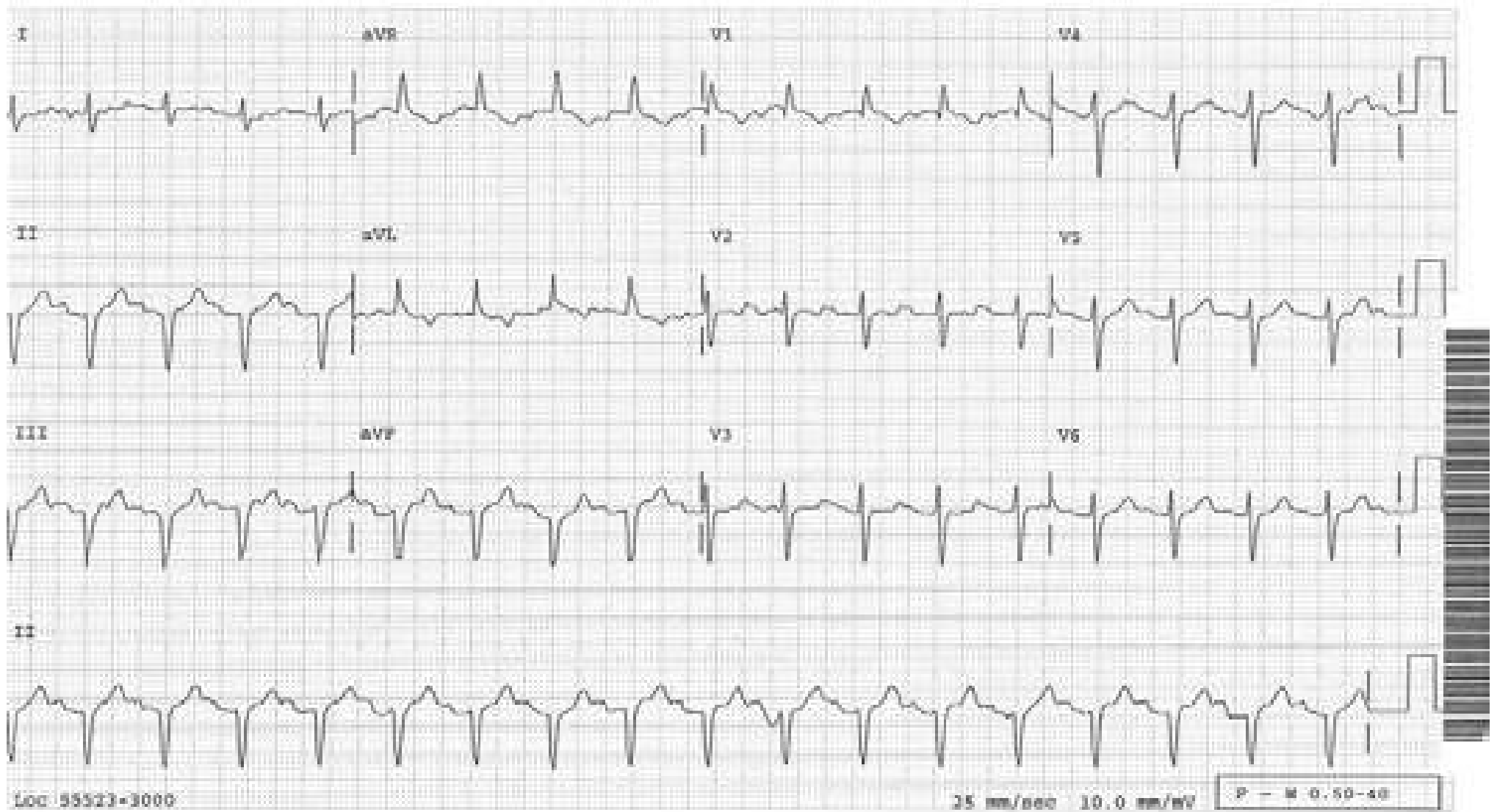
## Acute Cor Pulmonale

New IRBBB with sinus tachycardia is another manifestation of acute right ventricular overload and is highly suggestive of pulmonary embolism.



## Artrial Septal Defect, Primum

Note incomplete RBBB and left axis deviation

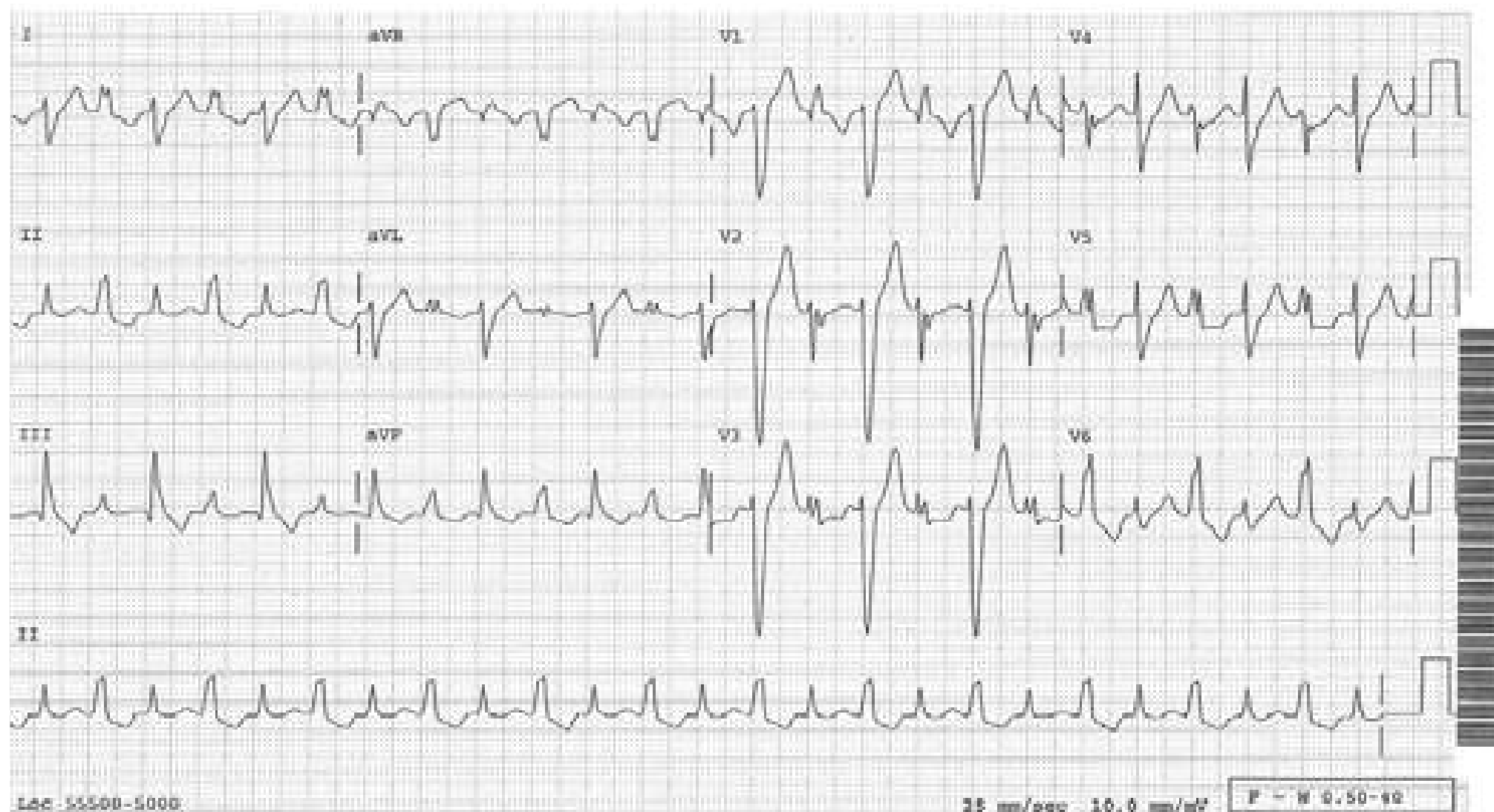






## Bidirectional Tachycardia

Regular (not bigeminal) wide QRS tachycardia at a rate of 150/min and alternating QRS morphology; this rhythm is called bidirectional tachycardia, and is seen in conditions such as digitalis toxicity or herbal aconite poisoning. The rhythm is either ventricular tachycardia with alternating conduction over two different pathways, or AV junctional tachycardia with alternating conduction over two different pathways such as right bundle branch and left bundle branch. This patient had aconite poisoning and the rhythm spontaneously reverted to normal sinus rhythm. Lidocaine or flecainide has been effective in reported cases. If this rhythm is due to digitalis toxicity, Digibind is effective.






## Cardioinhibitory Response

Long “pause” due to the transient intense vagotonic state caused by such conditions as:

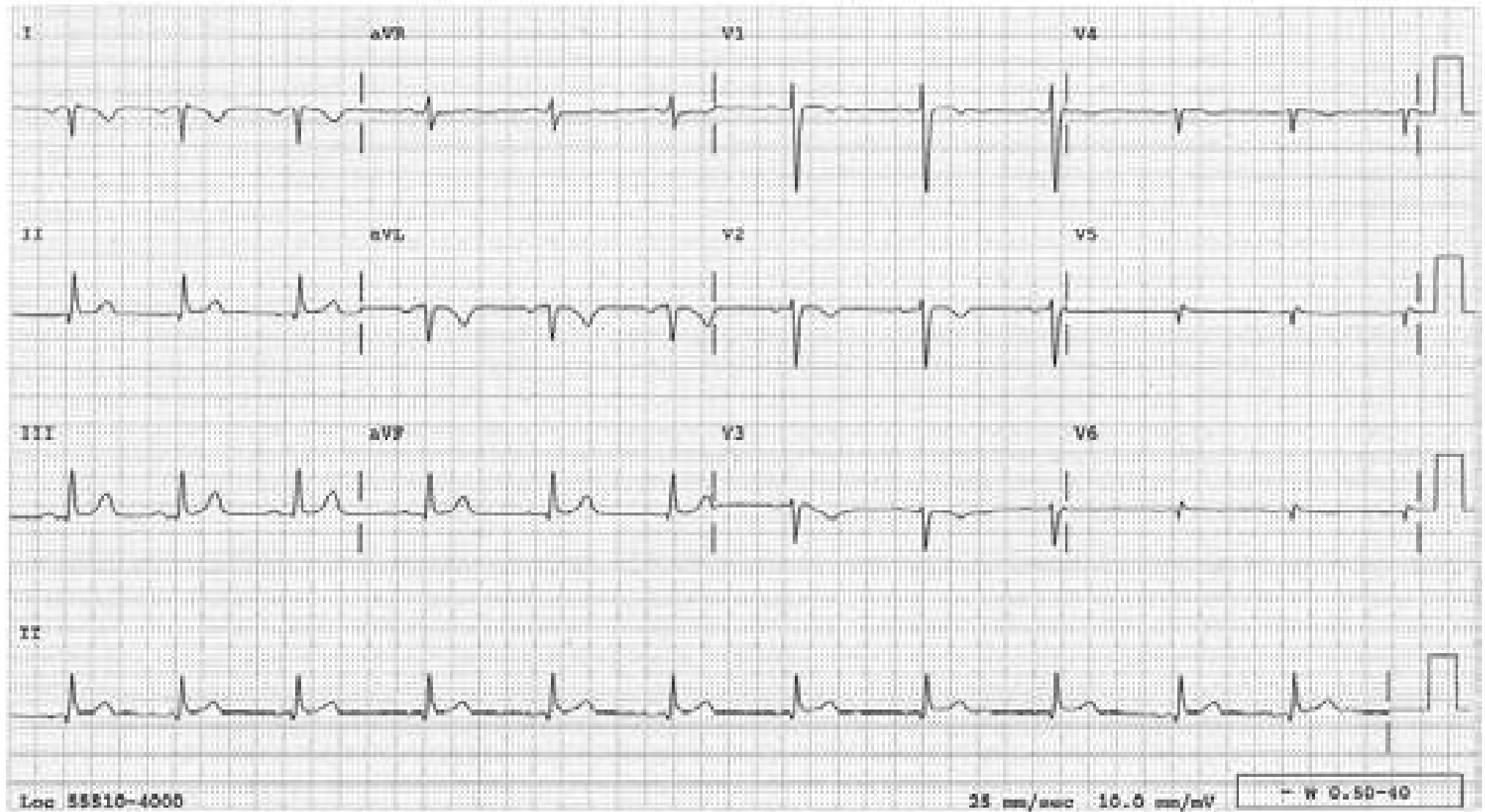
1. Neurocardiogenic syncope (vasovagal syncope)
2. Spontaneously or during carotid sinus massage in a patient with hypersensitive carotid sinus syndrome.
3. Paroxysms of cough
4. Micturition
5. Retching, vomiting, nausea
6. Tracheal suctioning, etc.

This is manifested by the sinus node being suppressed with no escape mechanism from either the AV junction or the ventricle because they are also suppressed.



## Dextrocardia

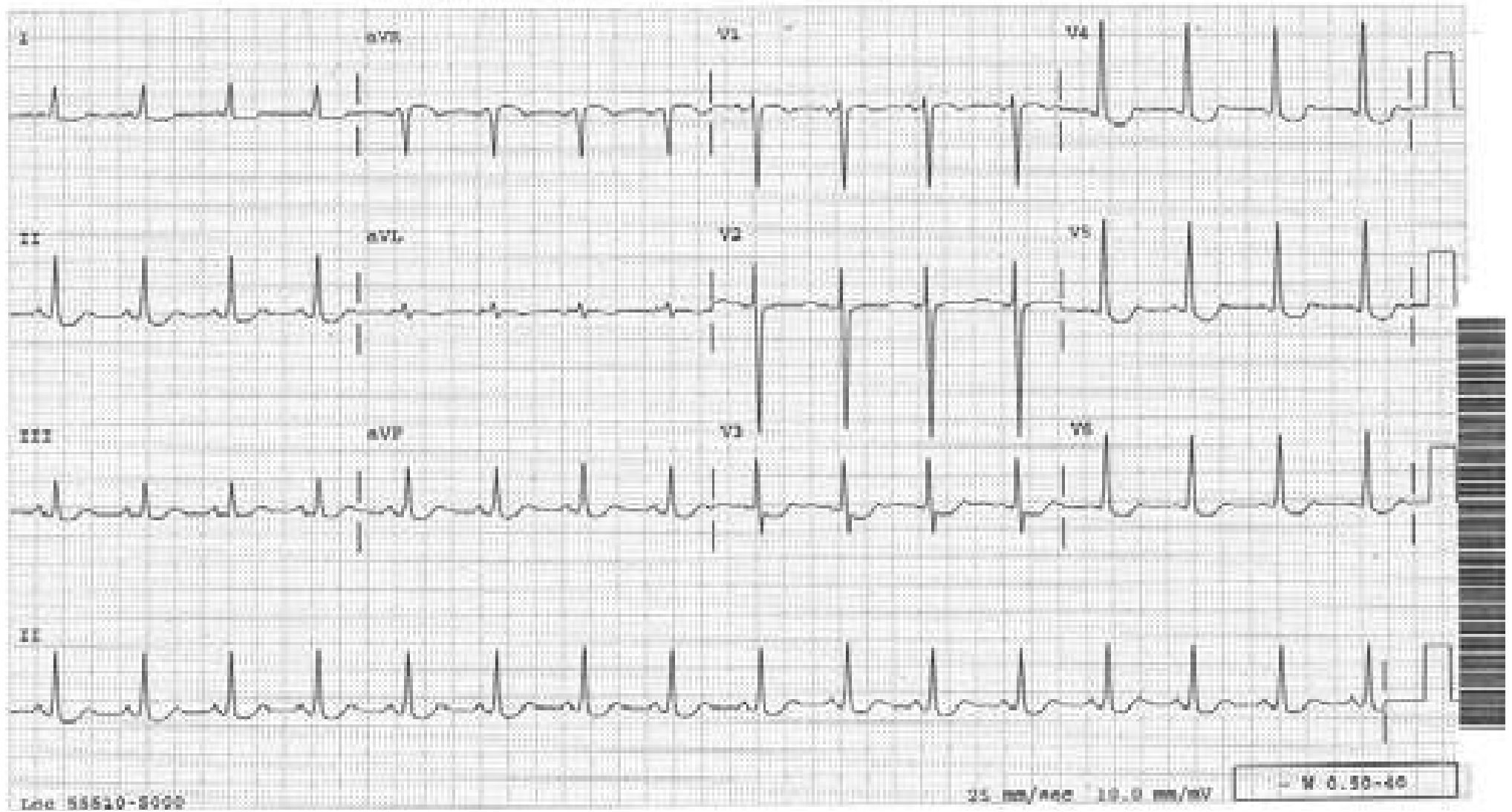
In lead I, the P wave, QRS and T wave are all inverted. Two conditions can cause this: reversed arm leads and dextrocardia. The findings in the precordial leads will determine which it is. If the R waves progress normally, it is reversed arm leads; if the R waves regress, as in this case, it is dextrocardia.





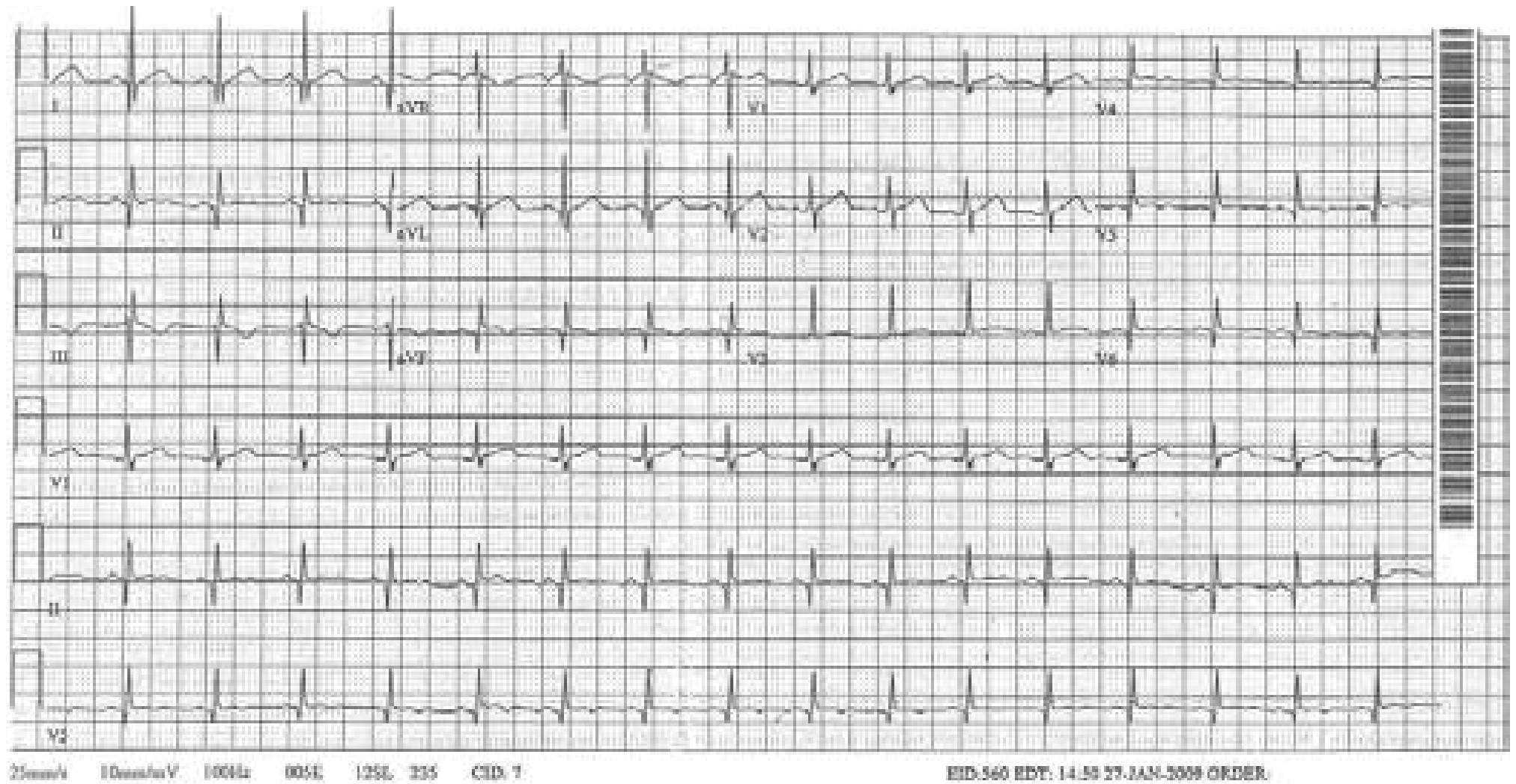
## Digitalis Effect on the ST Segment

The ST segment depression is sagging and rounded as if pulled down with a finger.



## Duchenne Muscular Dystrophy

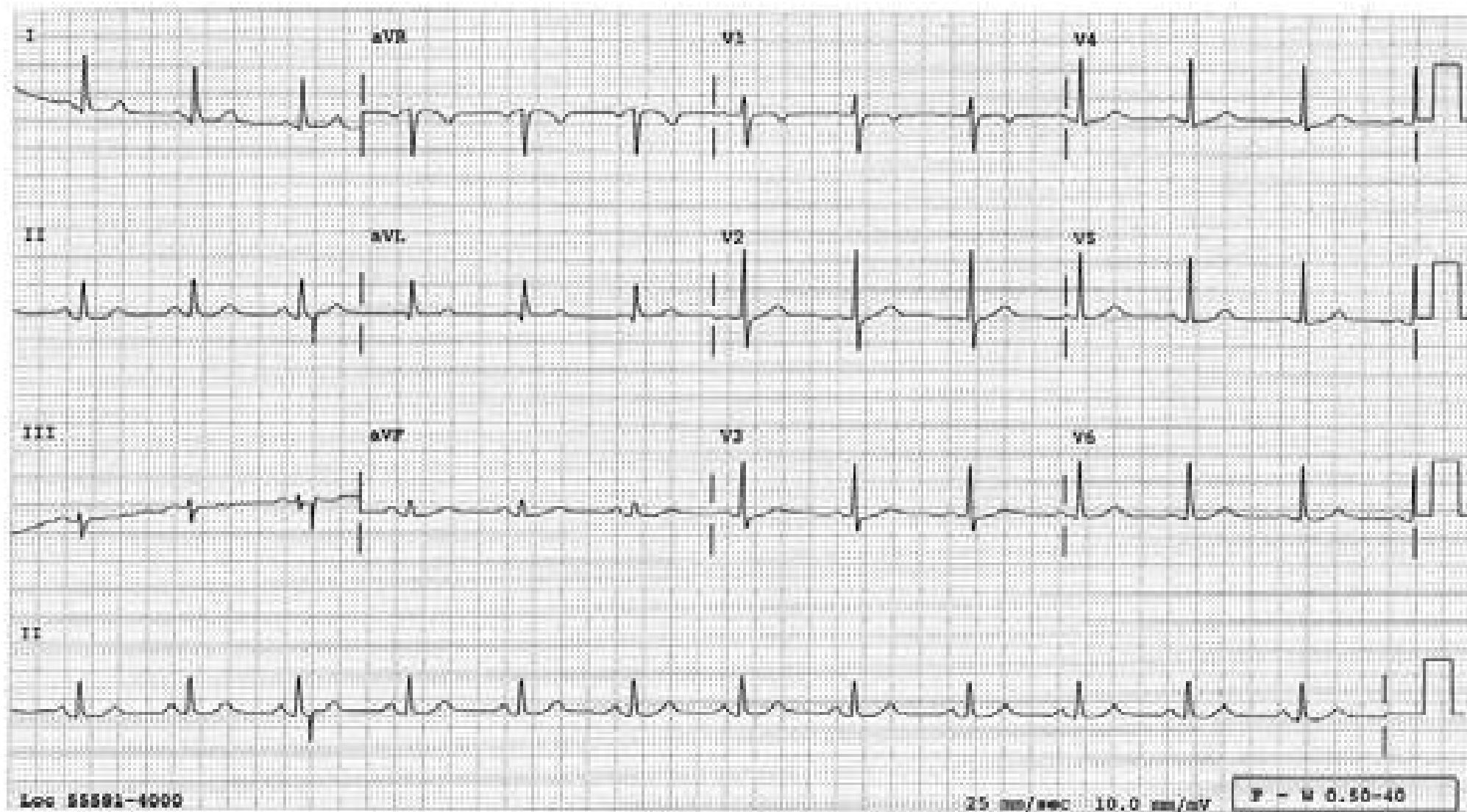
Tall R waves in  $V_1$  and deep, narrow Q waves in leads I, aVL and  $V_{5-6}$  related to the characteristic posterolateral left ventricular involvement.





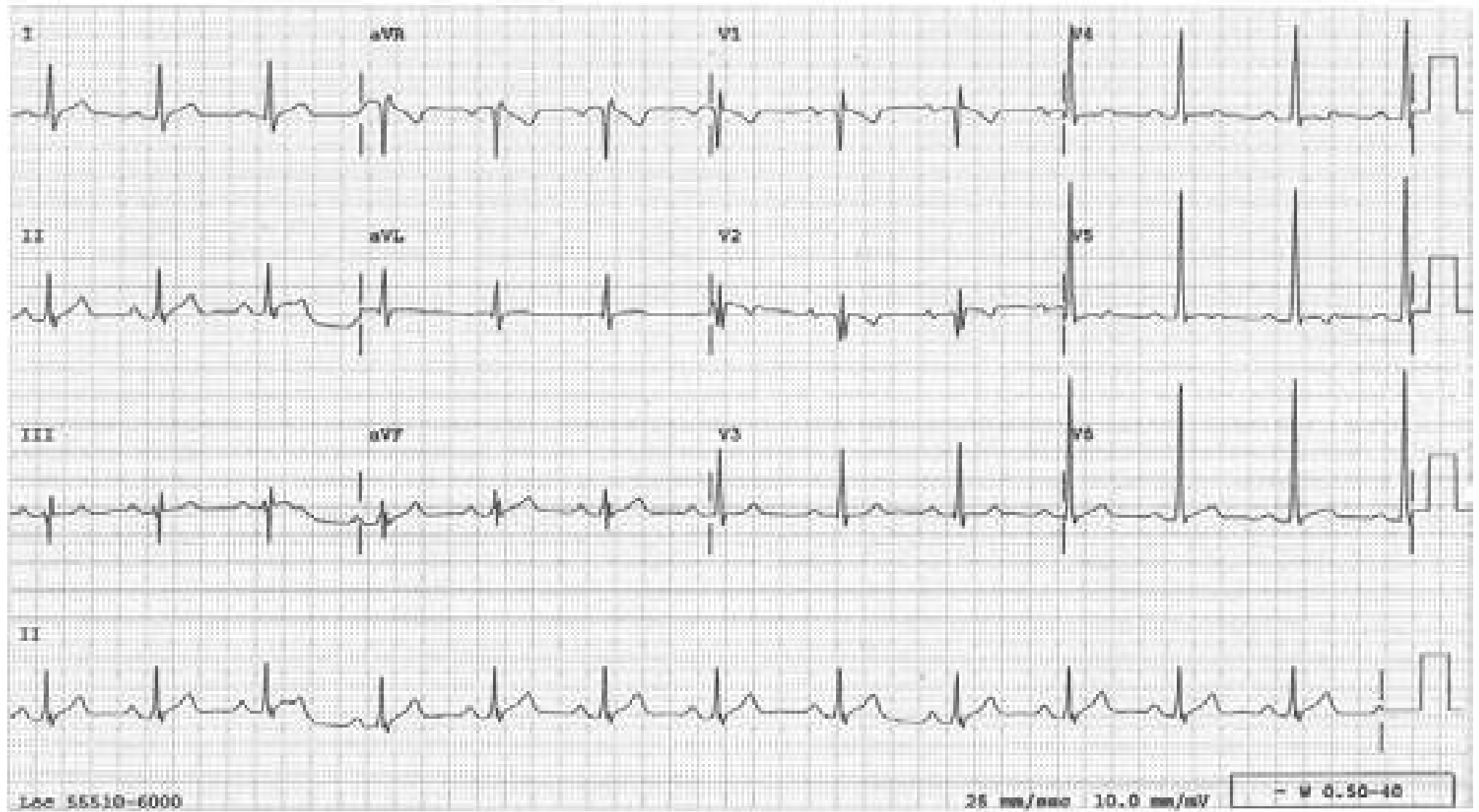
## Early Transition

Normally, the transition of R/S ratio of  $<1$  to  $>1$  occurs between  $V_3$  and  $V_4$ . If the R/S ratio is  $>1$  in  $V_1$  and/or  $V_2$  in the absence of RBBB, “early transition” is called. RVH, posterior MI, some cases of WPW syndrome, placing the precordial leads too low on the chest wall, and reversed precordial leads can cause an early transition; it can also be a normal variant.



## Ebstein's Anomaly

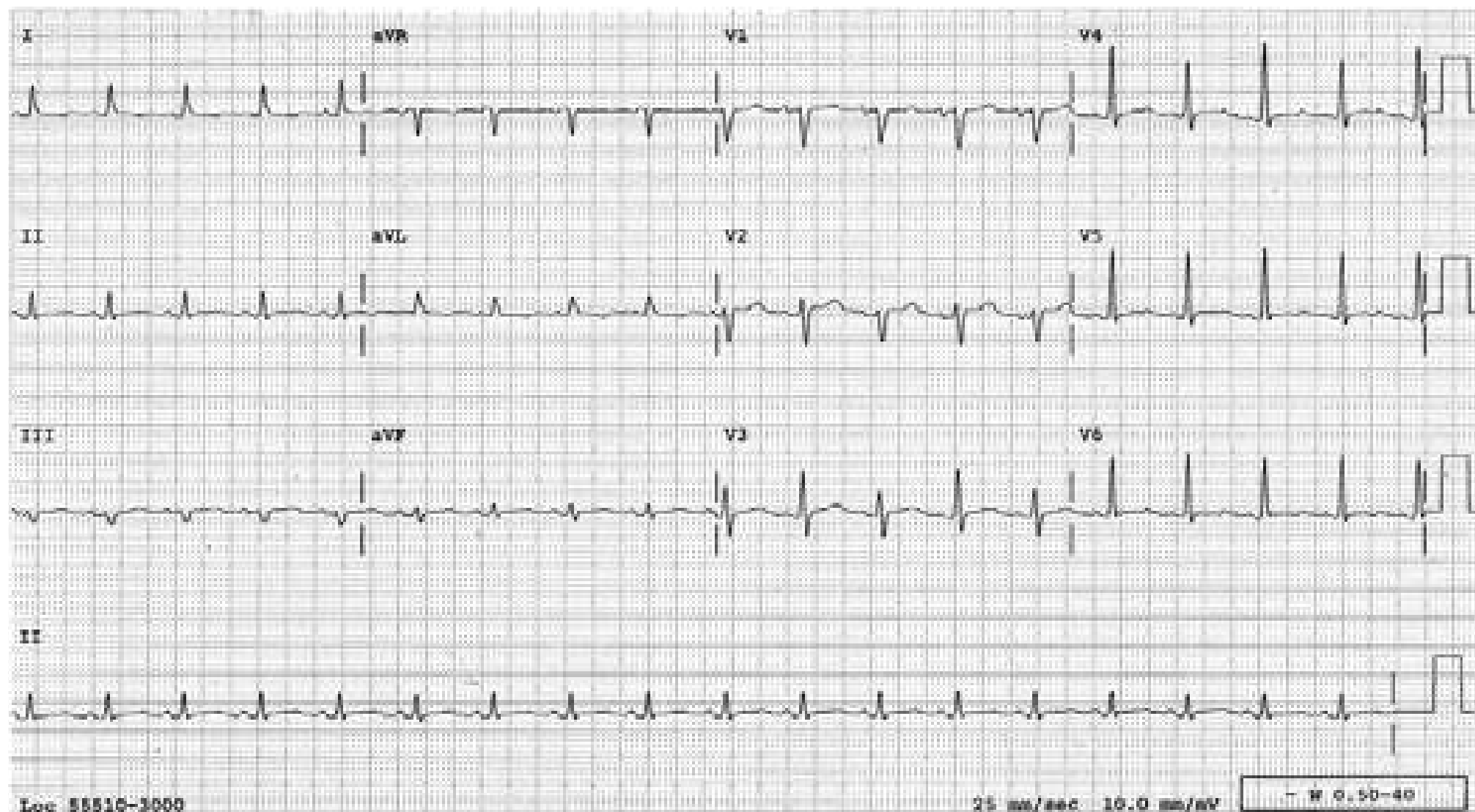
Note the incomplete RBB and qRs (W shape) pattern in  $V_2$ .





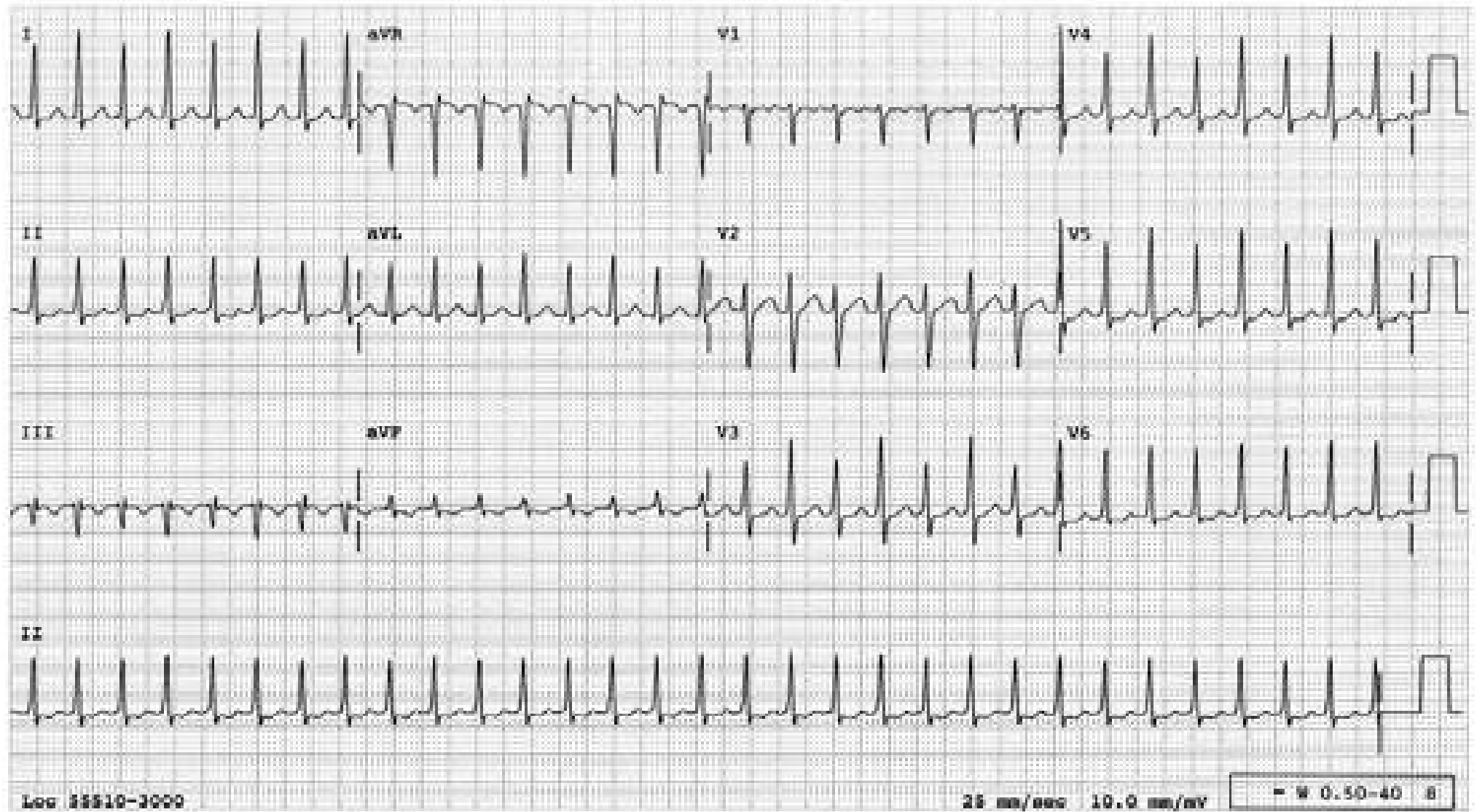
## Electrical Alternans

Electrical alternans is evident in V2-4. During sinus rhythm, this finding is highly specific for a large pericardial effusion or cardiac tamponade. Electrical Alternans can occur in some cases of SVT, atrial flutter or ventricular tachycardia and does not reflect pericardial problems (see following three tracings.)



## Electrical Alternans During SVT

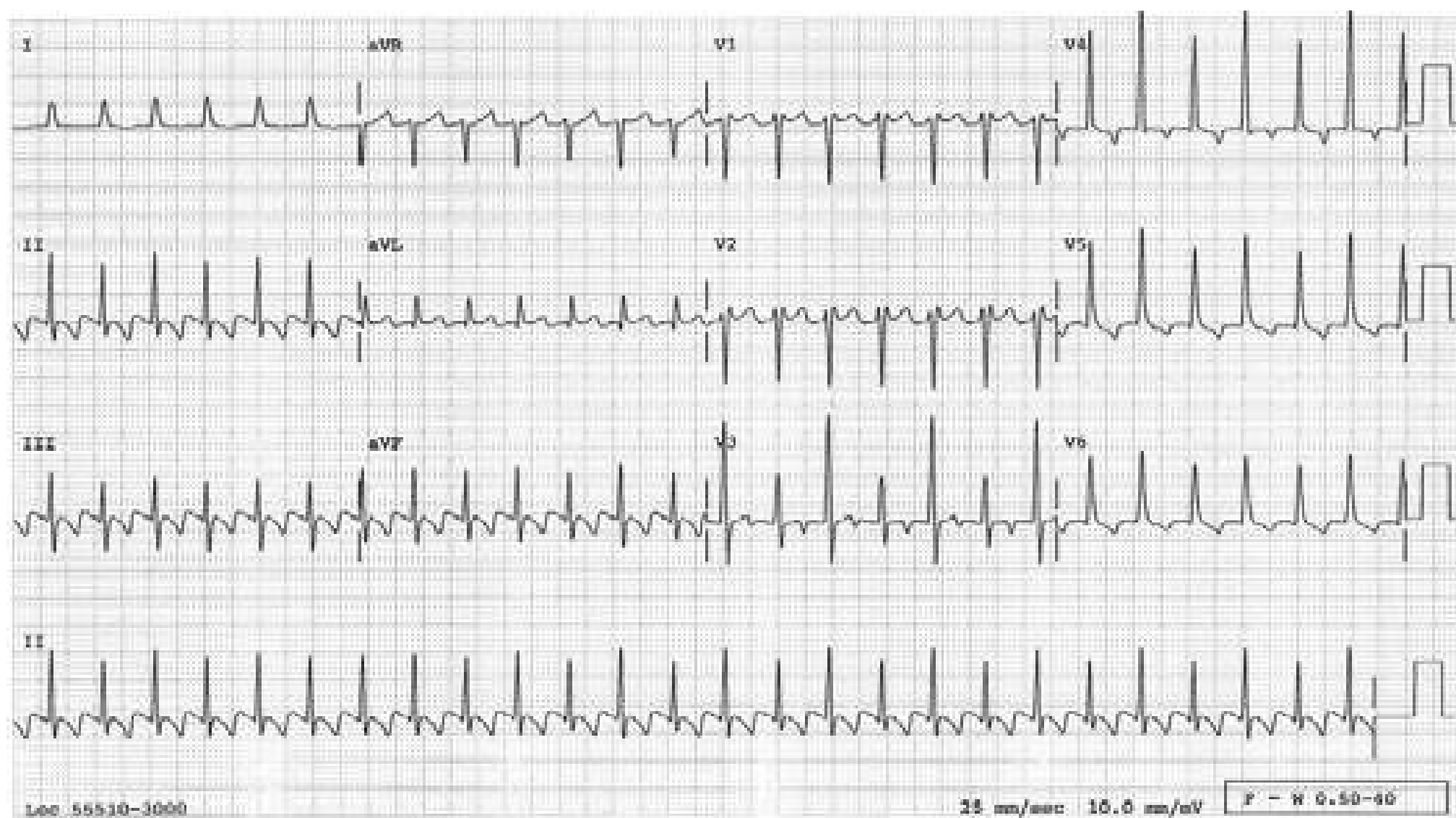
This tracing presents SVT at a rate of 185/min with electrical alternans present in many leads (see lead  $V_3$  especially). Electrical alternans during SVT does not indicate tamponade as it does during sinus rhythm.





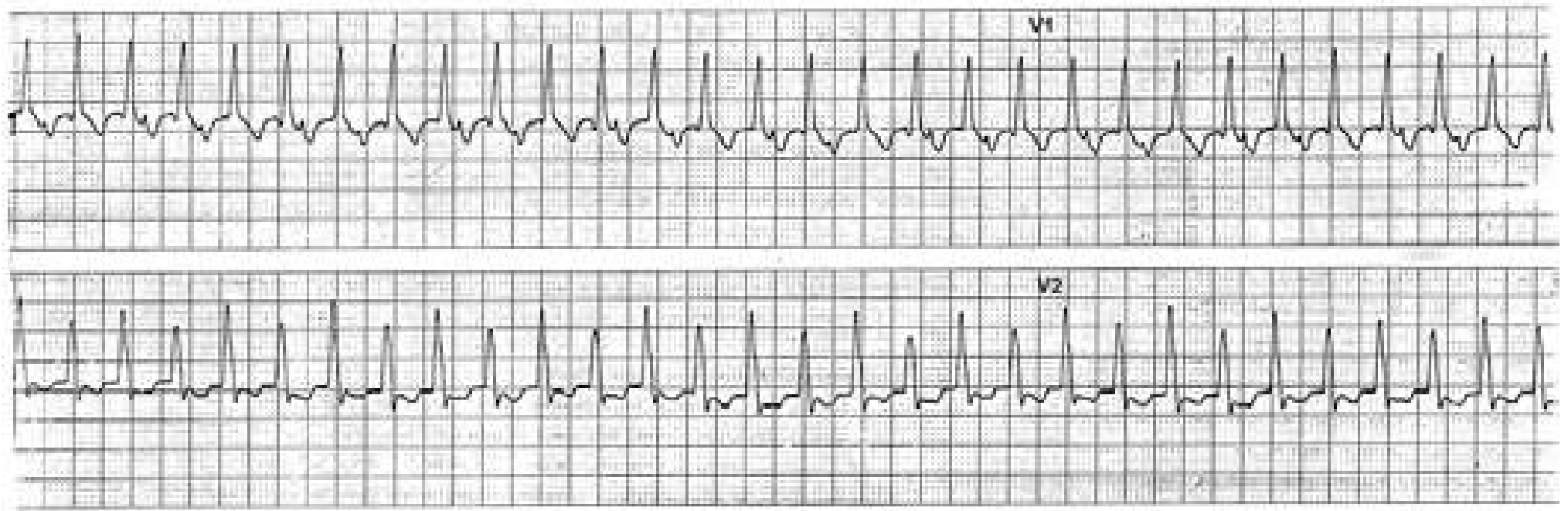
## Atrial Flutter with Electrical Alternans

(See discussion on page 246)



## Ventricular Tachycardia with Electrical Alternans

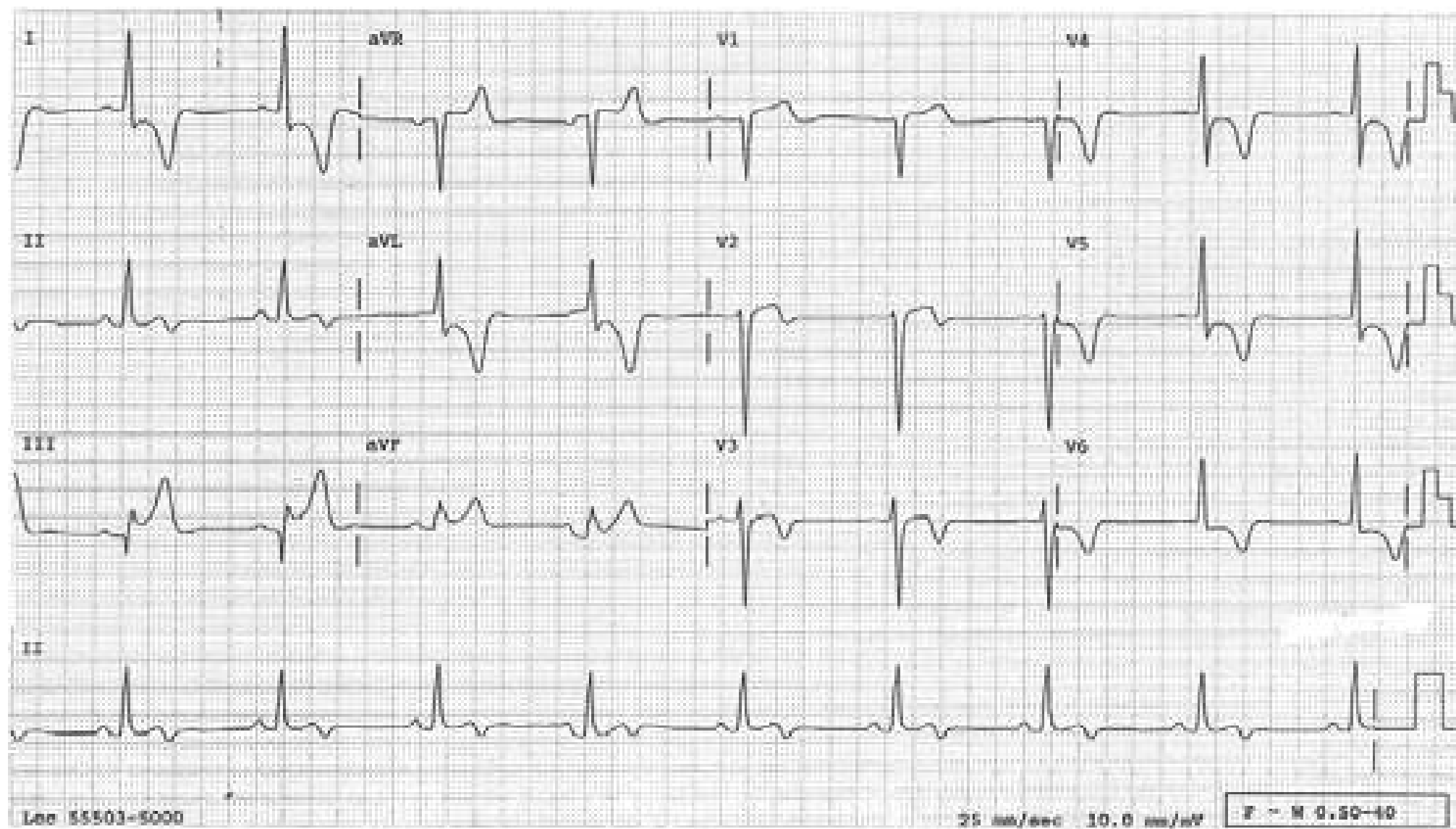
(See discussion on page 246)





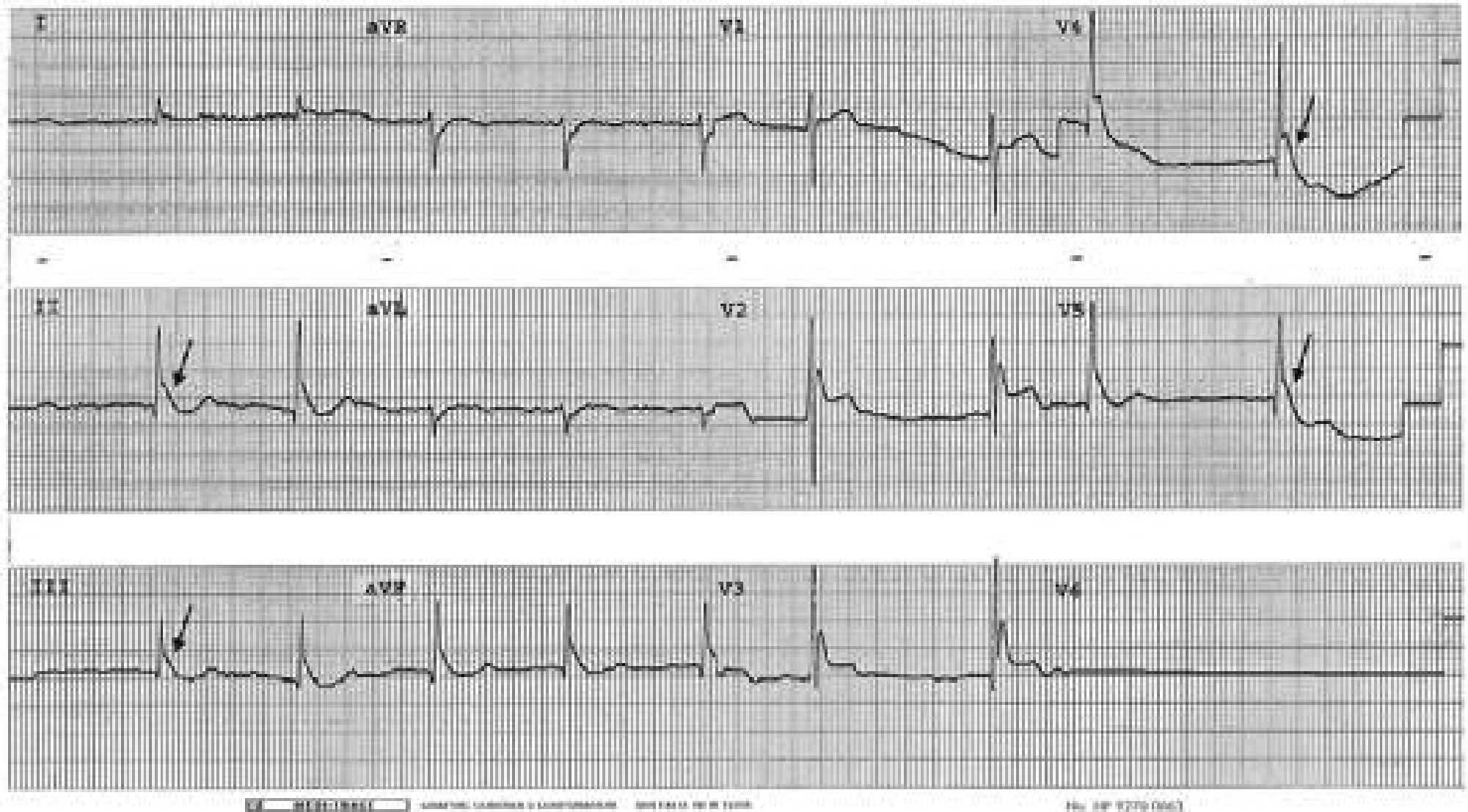
## Hypertrophic Cardiomyopathy

The increased QRS voltage and deeply inverted T waves are characteristic; some may have prominent septal Q waves.



## Hypothermia

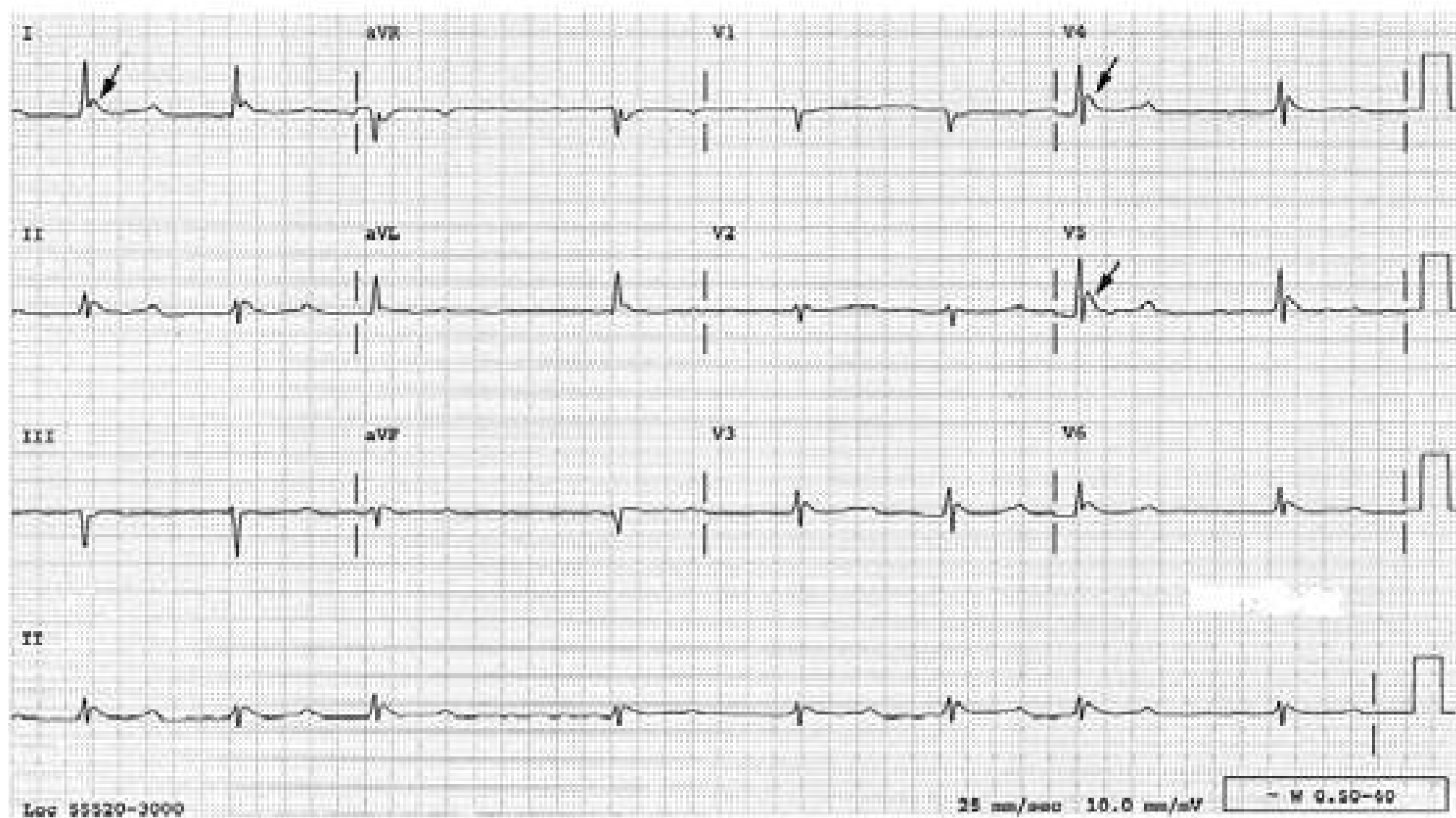
Slurred down stroke at the junction (↓) called J wave or Osborn wave is diagnostic of hypothermia. Atrial fibrillation and a long QT interval are also commonly seen in hypothermia.





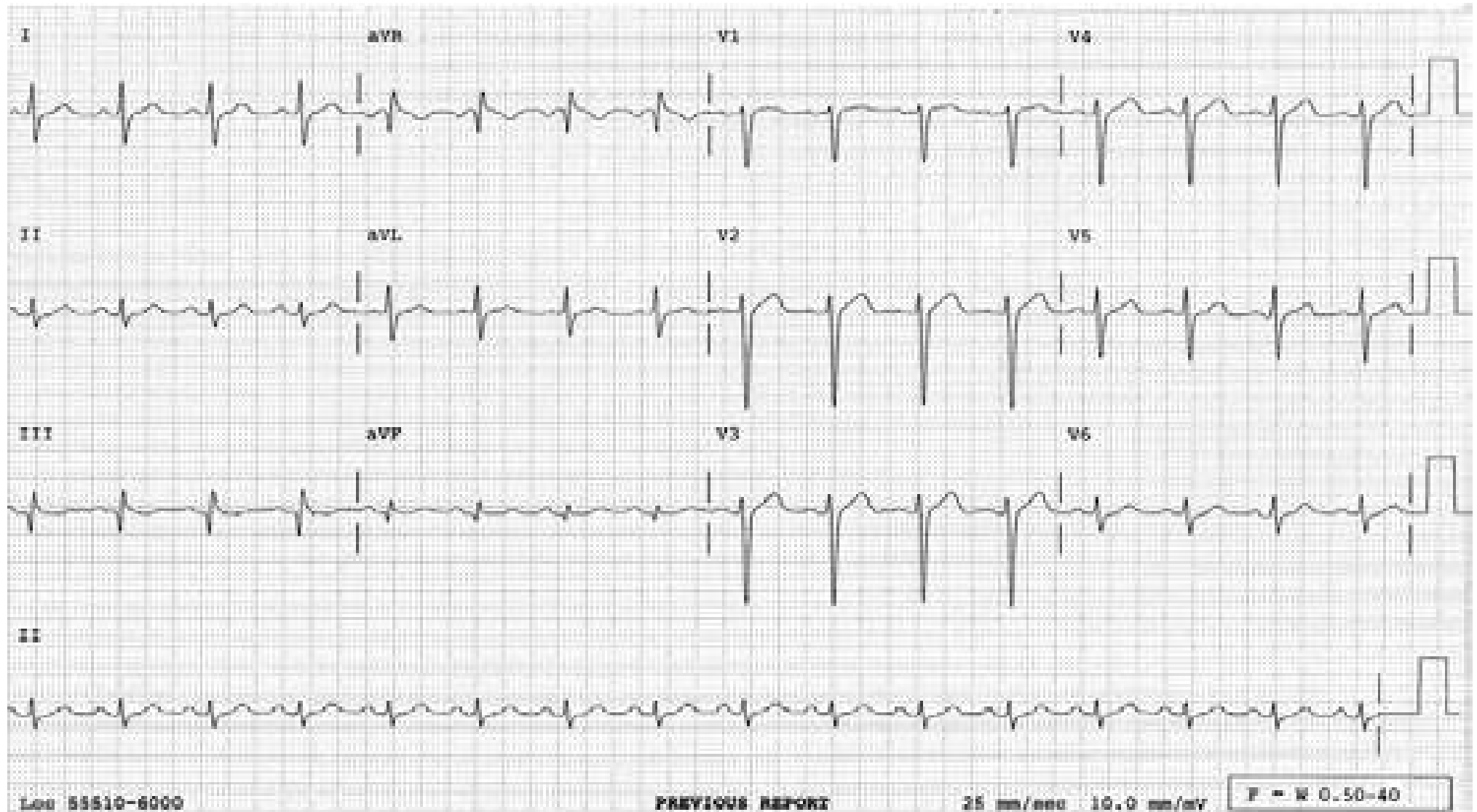
## Hypothermia

Another example of hypothermia showing Osborn waves (↓), long QT interval and atrial fibrillation.



## Late Transition

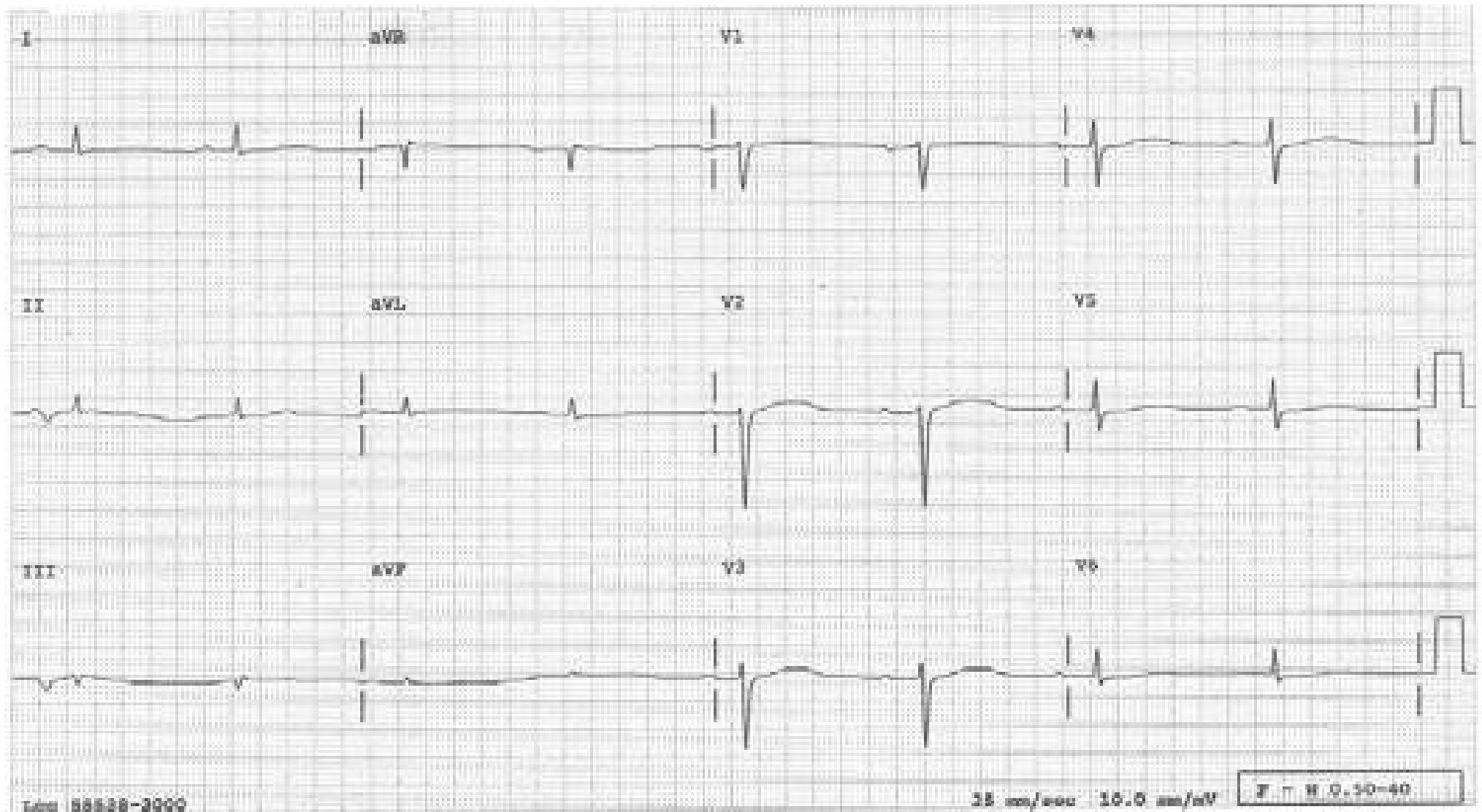
When the transition (the change of R/S ratio from  $<1$  to  $>1$ ) occurs in  $V_5$  or  $V_6$  or never, “late transition” is called. COPD, left anterior fascicular block, anterior MI, diffuse cardiomyopathy and placing the precordial leads too high on the chest wall can cause a late transition; it can also be a normal variant.





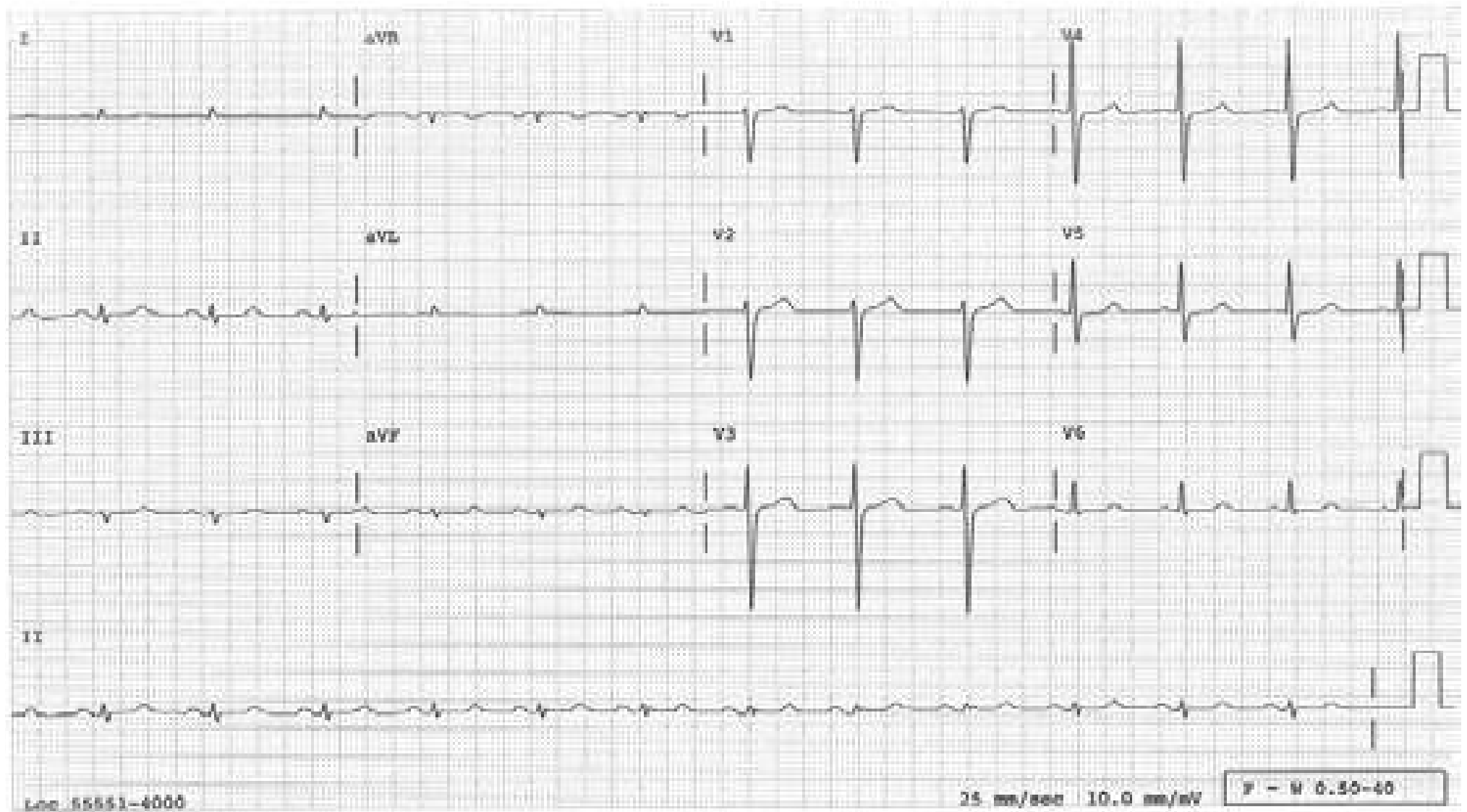
## Long QT Interval

The QT interval here is markedly prolonged to 0.64 s. This patient is at risk of developing torsade de points. A long QT interval may be congenital, or may be secondary to coronary artery disease, mitral valve prolapse, CNS events, autonomic nervous system imbalance, liquid protein diet and numerous drugs including quinidine, procainamide, disopyramide, sotalol, amiodarone, phenothiazines, tricyclic antidepressants, antihistamines combined with ketoconazole or erythromycin, pentamidine, etc. Long QT interval due to hypocalcemia does not cause Torsade de pointes.



## Low QRS Voltage

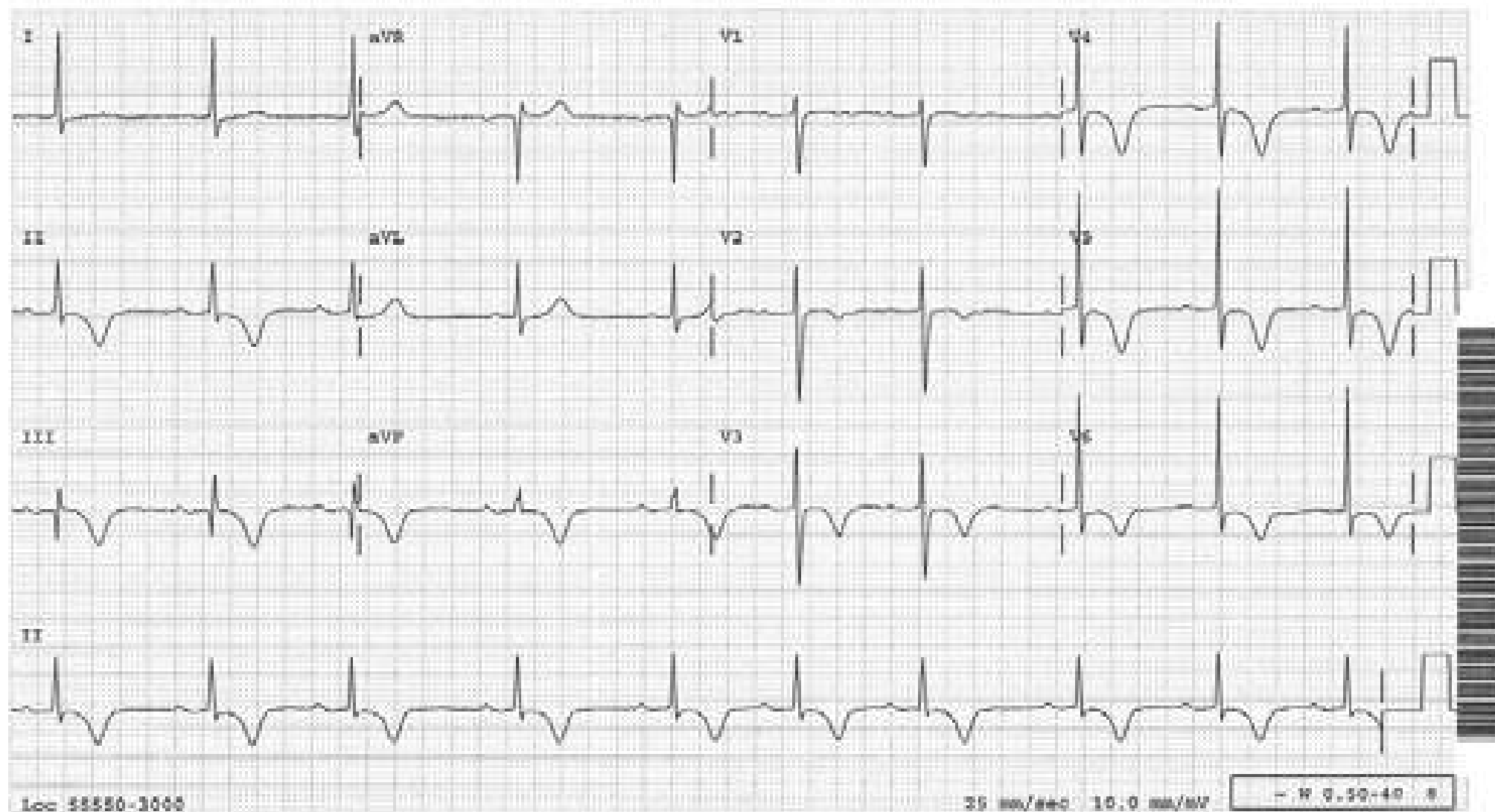
When the QRS voltage is less than 5 mm in every limb lead or 10mm in every precordial lead, the QRS voltage is said to be abnormally low. Conditions such as pericardial or pleural effusion, emphysema, obesity, myxedema, diffuse myocardial damage, and infiltration of the myocardium with amyloid should be considered; it may also be a normal variant.





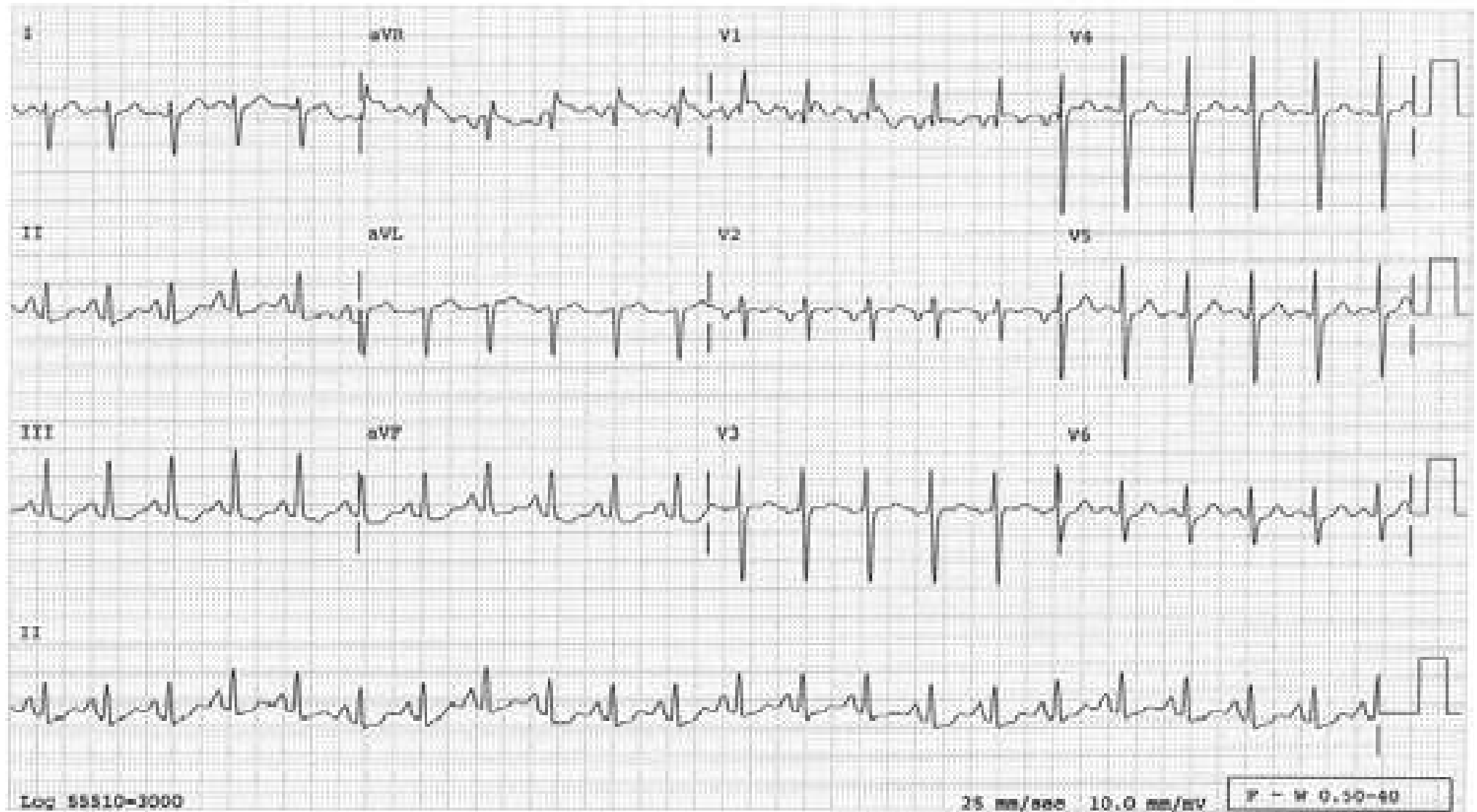
## Memory T Wave

This tracing was taken from a patient who has been electronically paced for sick sinus syndrome and when the pacer was turned off. T waves are deeply inverted in many leads, which lasted for a day. This kind of T-wave change can be seen transiently after SVT, VT, ventricular pacing as in this case, or after LBBB reverts to normal conduction. Such T-wave changes are called memory T waves (the heart remembers the bad times it had !) and are benign.



## Mitral Stenosis

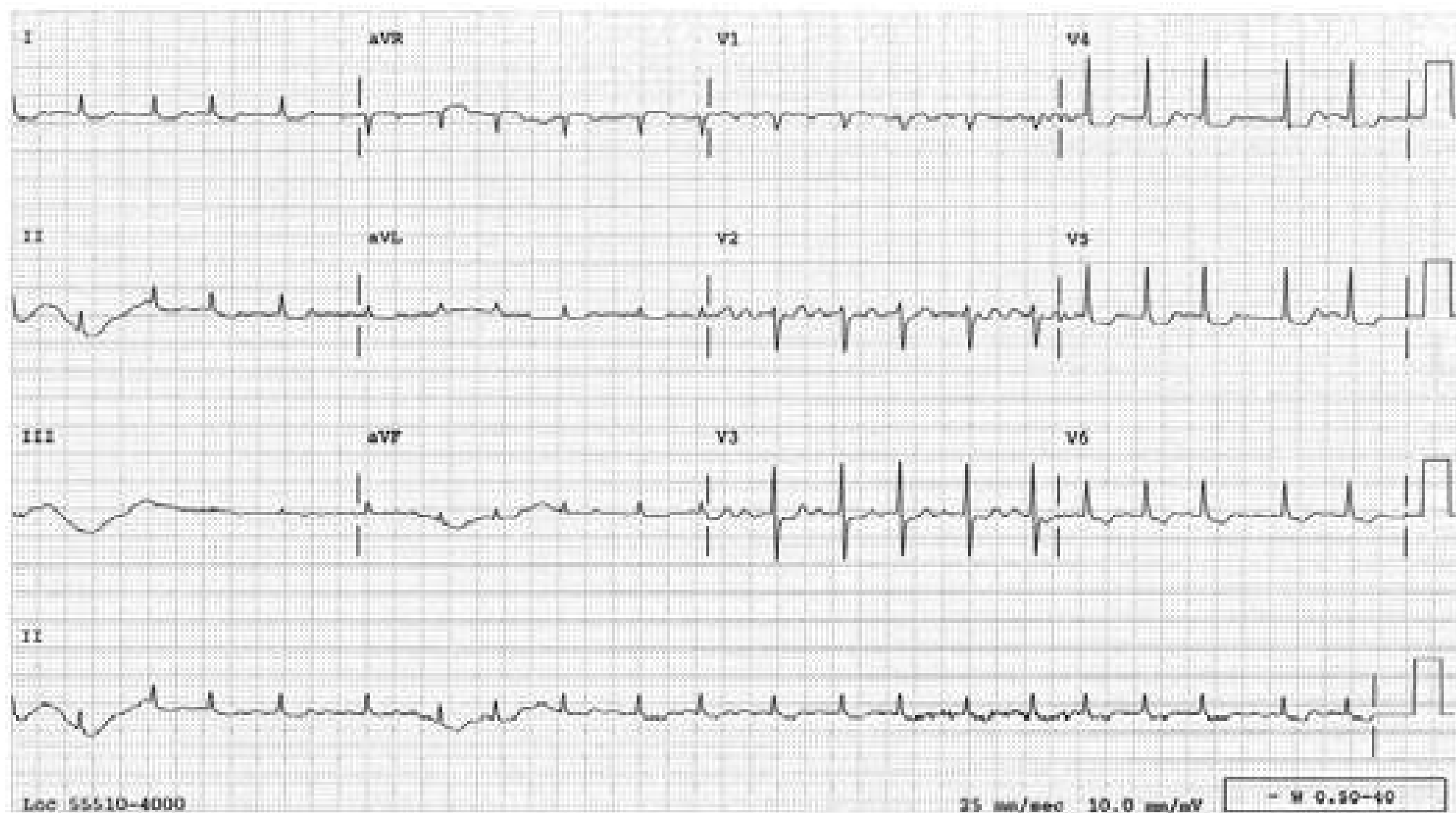
In this tracing, features of RVH are present (RAD, tall R wave in V1, deep S wave in V6 and T wave inversion in V1-2). The P wave in V1 is all negative, indicating left atrial enlargement (LAE). The combination of *right* ventricular hypertrophy and *left* atrial enlargement in the absence of LVH is highly suggestive of mitral stenosis.





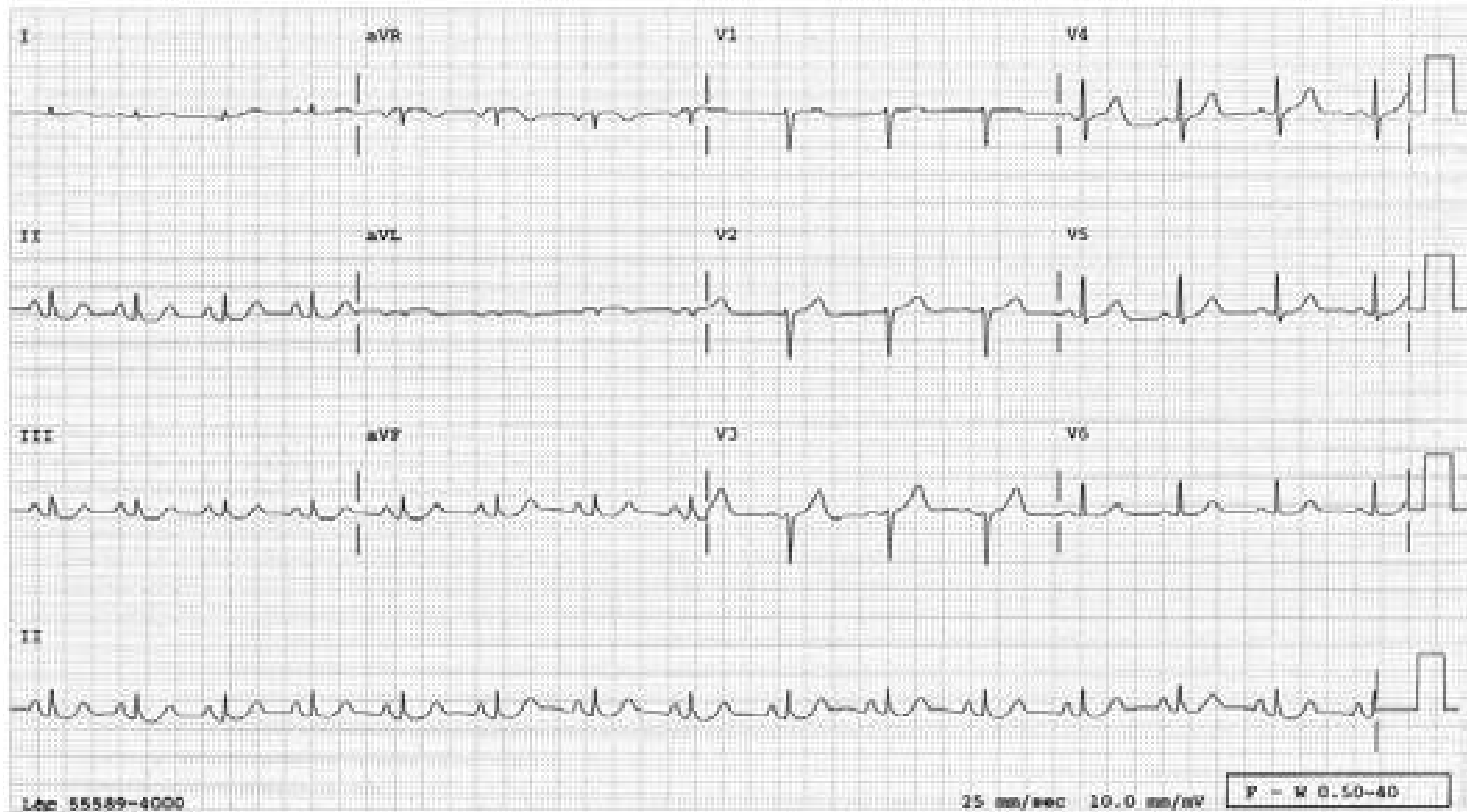
## Nonspecific STT Changes

The ST-segment and the T waves are clearly abnormal. However, one can't be certain as to the specific cause of these abnormalities. Any one or a combination of the following conditions could be responsible: myocardial ischemia, electrolyte abnormalities, digitalis or other medications, tachycardia, autonomic tone, pericarditis, myocarditis, etc.; hence, "nonspecific". The term "nonspecific" does not imply "not significant."



## Poor R Wave Progression

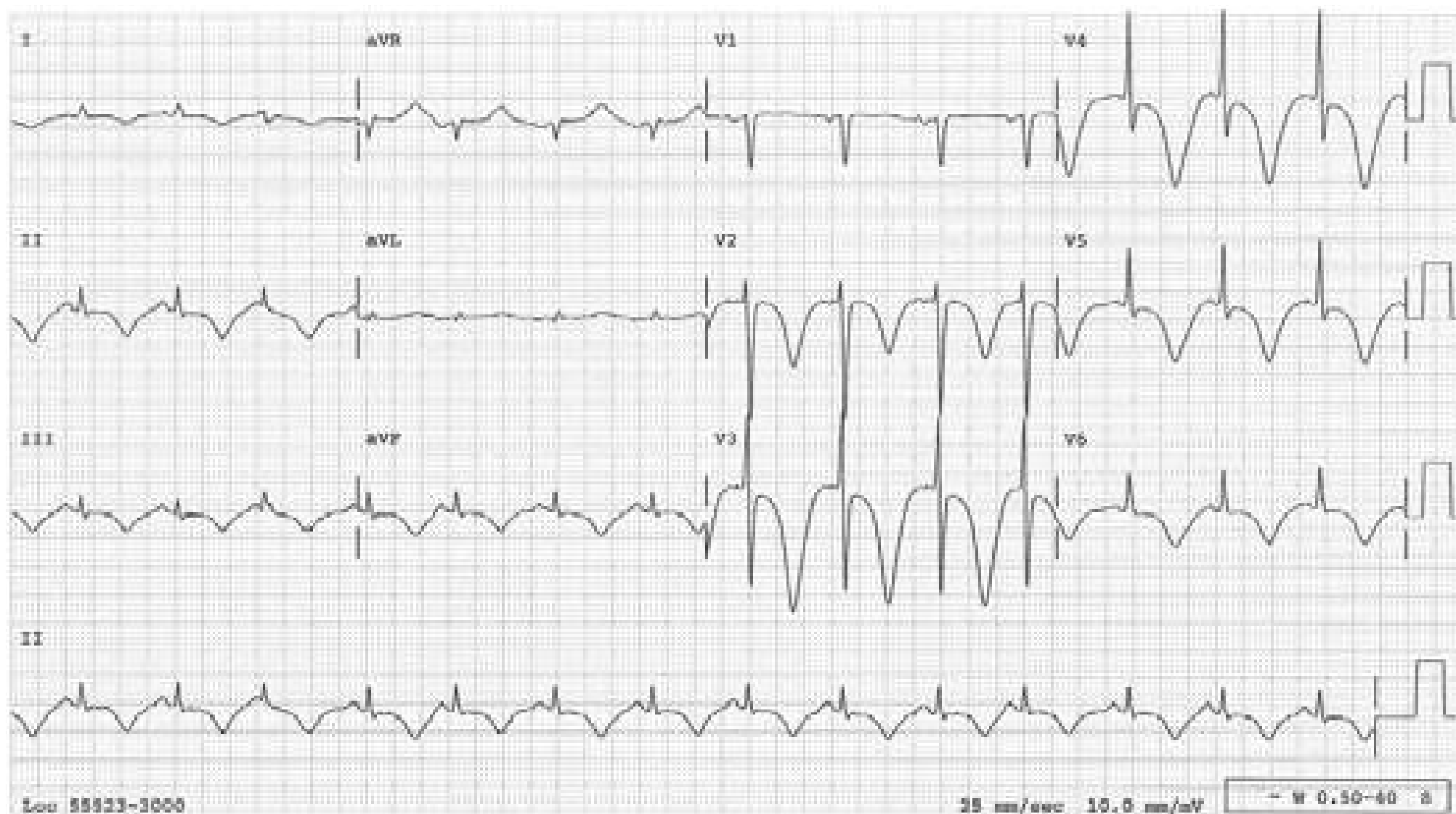
In a normal heart, R waves should become gradually taller from V1 through V5 or V6, with the R/S ratio becoming  $>1$  by V4. If the R waves remain small in V1 through V3 or V4 in the absence of a conduction defect, “poor R wave progression” is called. This differs from “late transition” in that the R/S ratio is usually  $>1$  in V4 in the case of poor R wave progression. Causes for this include: anteroseptal MI, COPD, LVH, diffuse cardiomyopathy and misplaced precordial leads; it is seen normally in some patients.





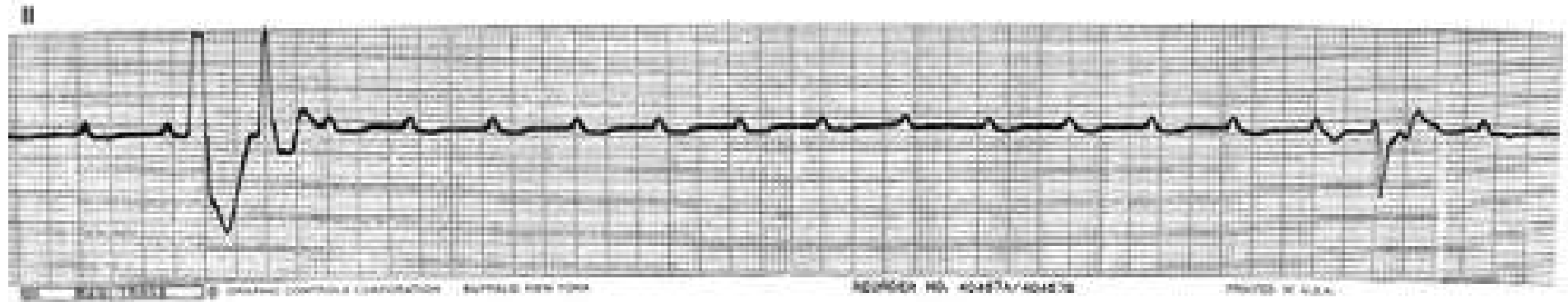
## Stress Cardiomyopathy (Neurogenic T Wave Changes)

Deeply and symmetrically inverted T waves with a long QT interval are often seen in acute CNS events, such as subarachnoid hemorrhage or head trauma. These ECG findings are not unique to CNS events since the same findings have been observed in a variety of other acute medical conditions, including emotional stress, more often in elderly women (stress cardiomyopathy). At the onset, many patients develop mild ST-segment elevation indistinguishable from that of acute infarction. On echocardiogram or ventriculogram the distal half of the left ventricle is ballooned out (apical ballooning syndrome or Takotsubo cardiomyopathy) with a complete recovery. The mechanism is not well understood, but catecholamine surge seems to be the common denominator of this entity.



## High Grade AV Block During Swan-Ganz Catheter Insertion in a Patient with LBBB

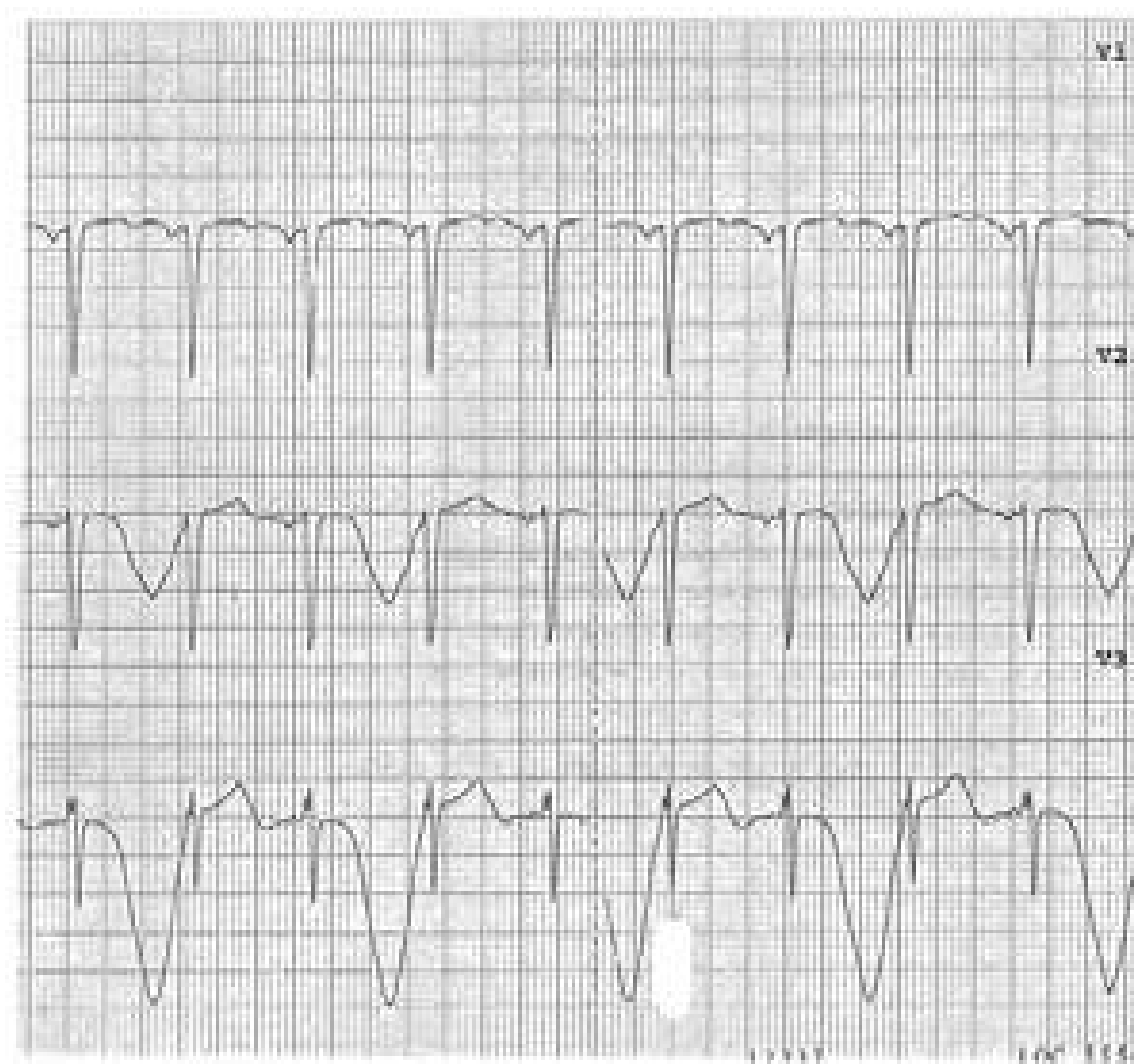
Many consecutive P waves are blocked. This happened when the balloon-tipped catheter tapped on the right side of the ventricular septum, causing transient RBBB as well in a patient who already has LBBB.



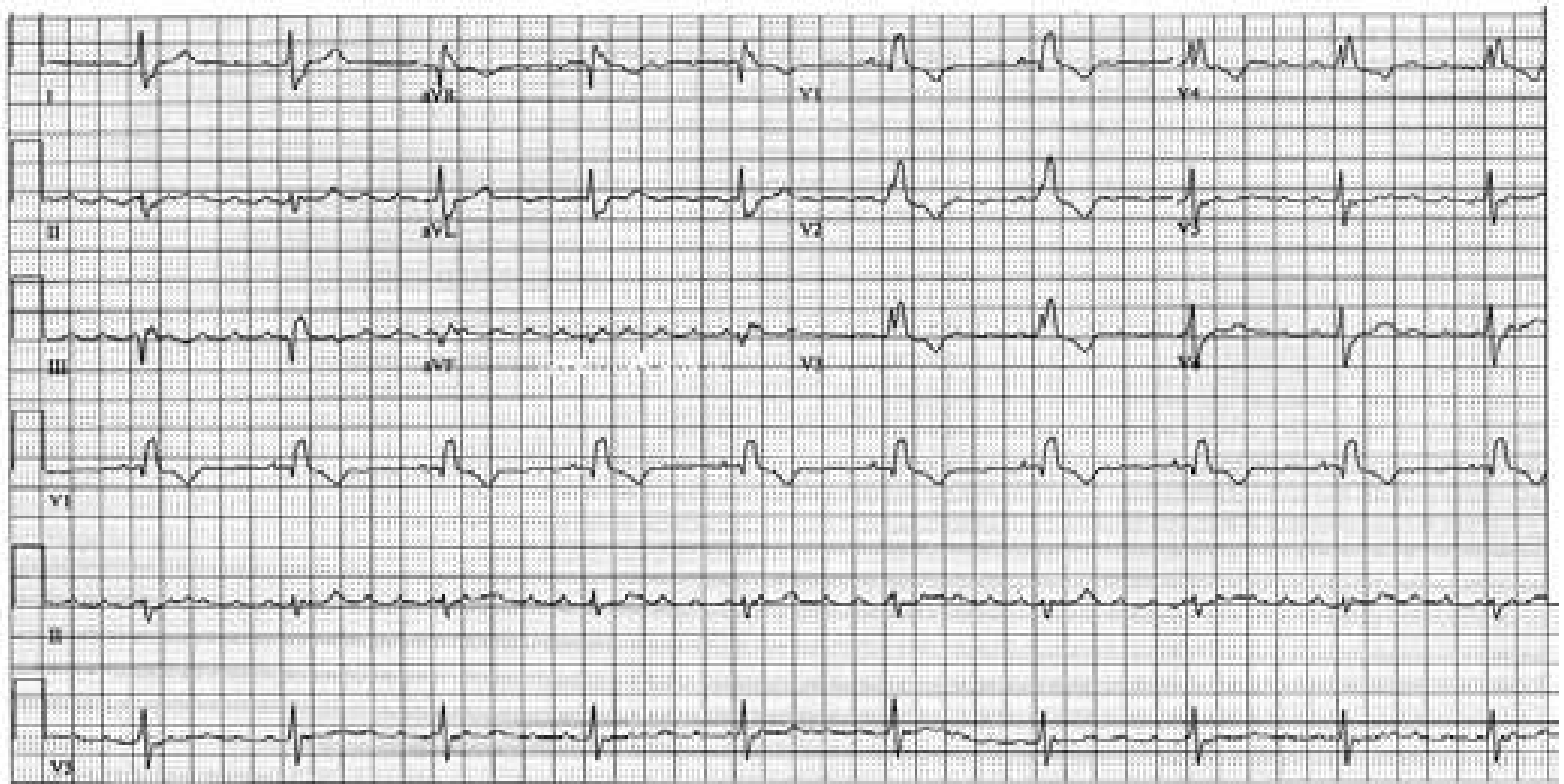


## T Wave Alternans

Deeply inverted T wave with a long QT interval alternates with a positive T wave. These findings are often a prelude to Torsade de pointes, and seen in myocardial ischemia, congenital long QT syndrome, catecholamine surge, and a variety of electrolyte derangements.



## Transplanted Heart

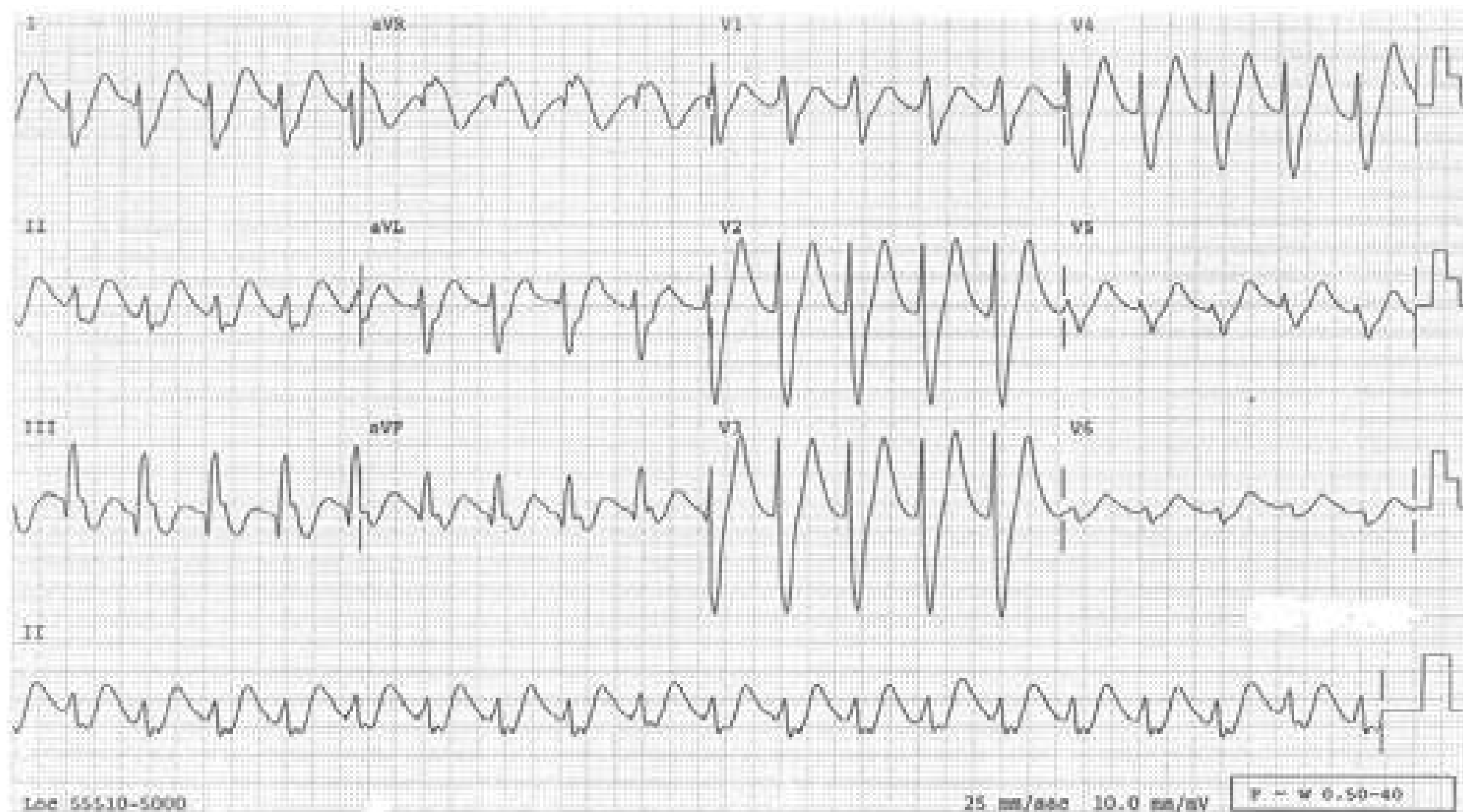


The inferior and many precordial leads have regular atrial activities at the rate close to 300/min suggesting atrial flutter. QRS complexes occur regularly at 70/min. During atrial flutter, regularly occurring QRSs mean a fixed AV conduction ratio, in which case the flutter wave and the QRS should maintain a fixed temporal relationship. That is not the case when one examines the rhythm strip of lead II. Besides, the rhythm strip of V1 clearly shows a P wave in front of each QRS with a fixed PR interval. This tracing is from a patient who had a heart transplant and the recipient atrial cap is in atrial flutter while the donor heart is in sinus rhythm. If it weren't for the heart transplant, one could consider the condition called dissimilar atrial rhythm where the right atrium is in one rhythm while the left atrium is in another. Another possibility that can be entertained is artifact from muscle tremor.



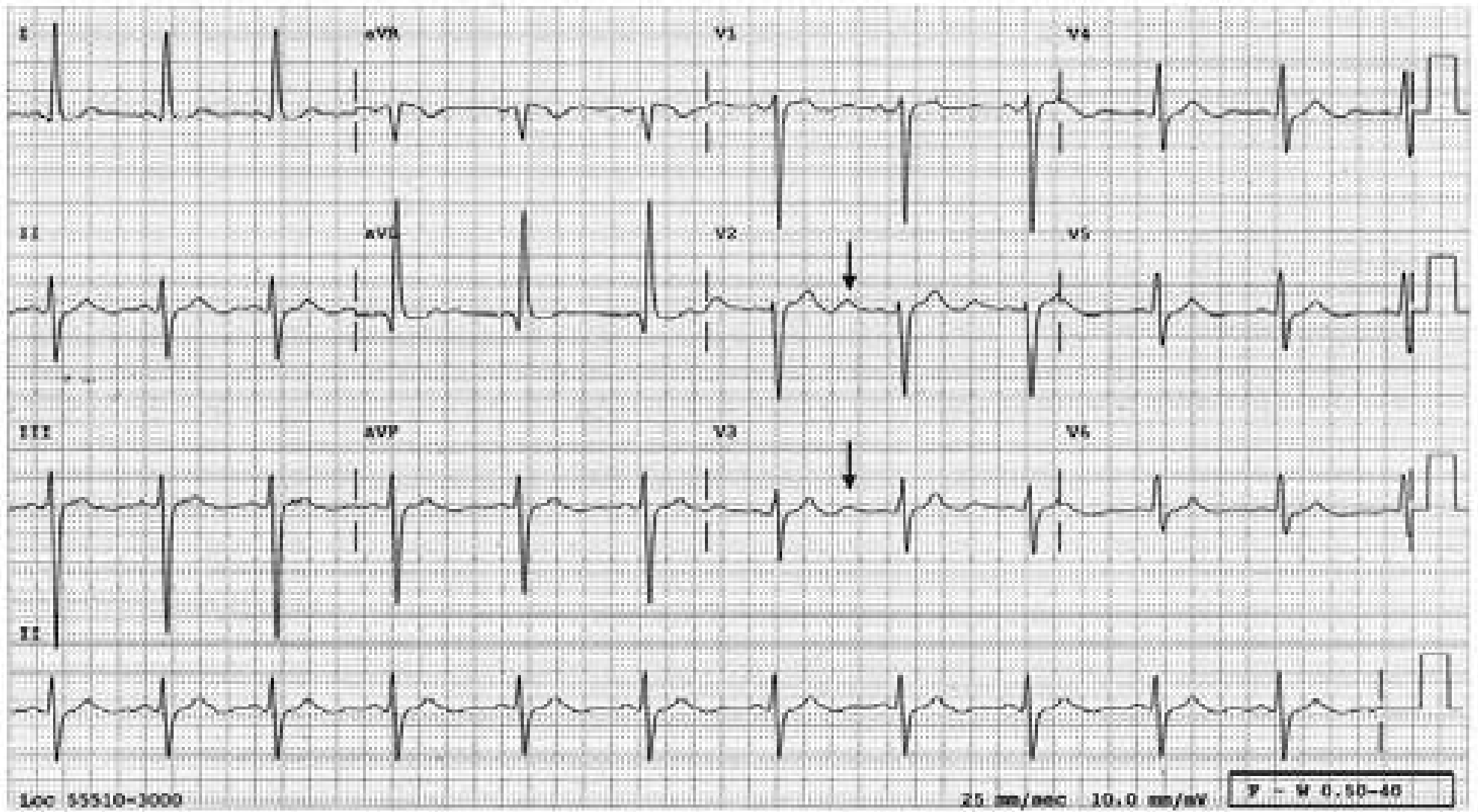
## Tricyclic Overdose

The wide QRSs in this ECG are not typical of either right or left bundle branch block. Sinus tachycardia is usually present.



## Prominent U Waves

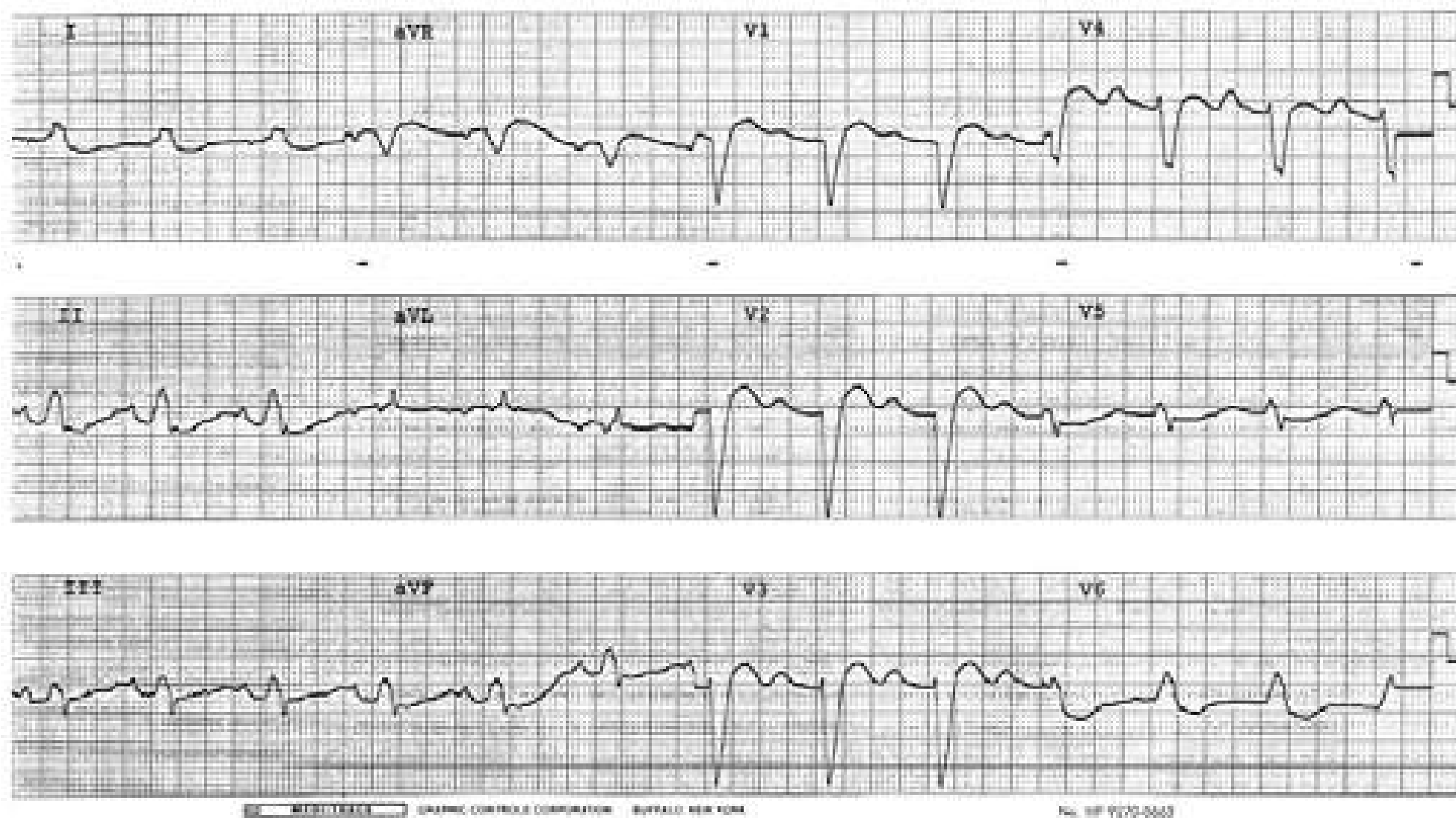The U waves (↓) are prominent. Prominent U waves may be normal or due to hypokalemia or LVH.





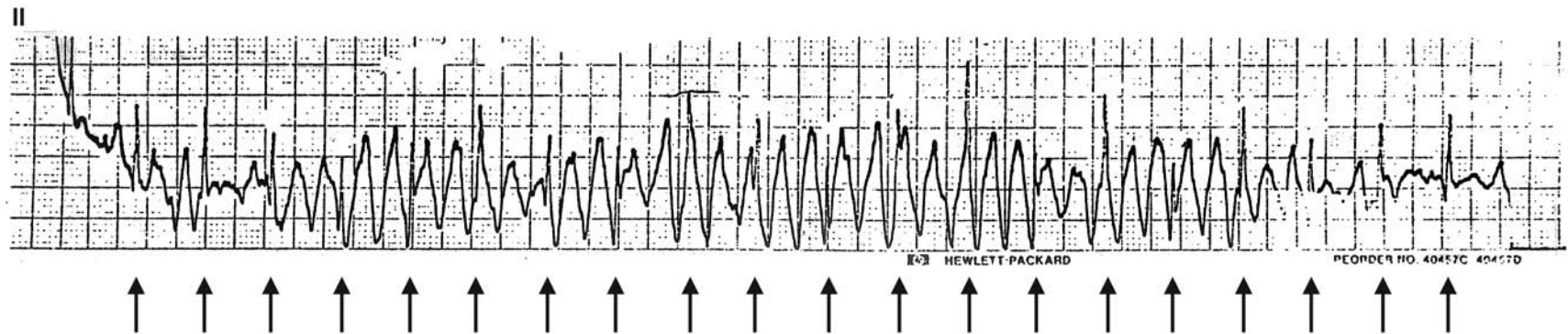
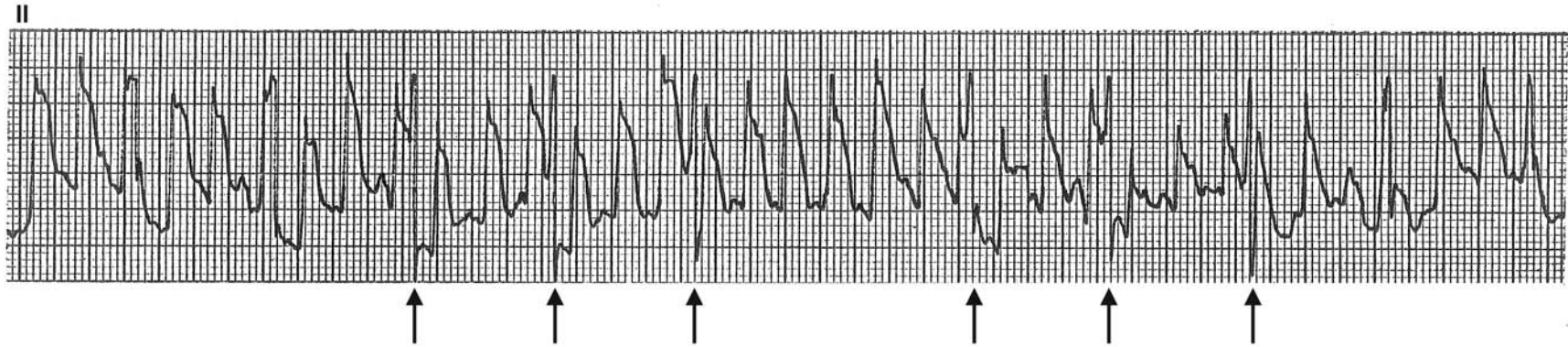
## Prominent U Waves

Prominent U waves mimicking P waves and 1° AV Block



## Artifacts

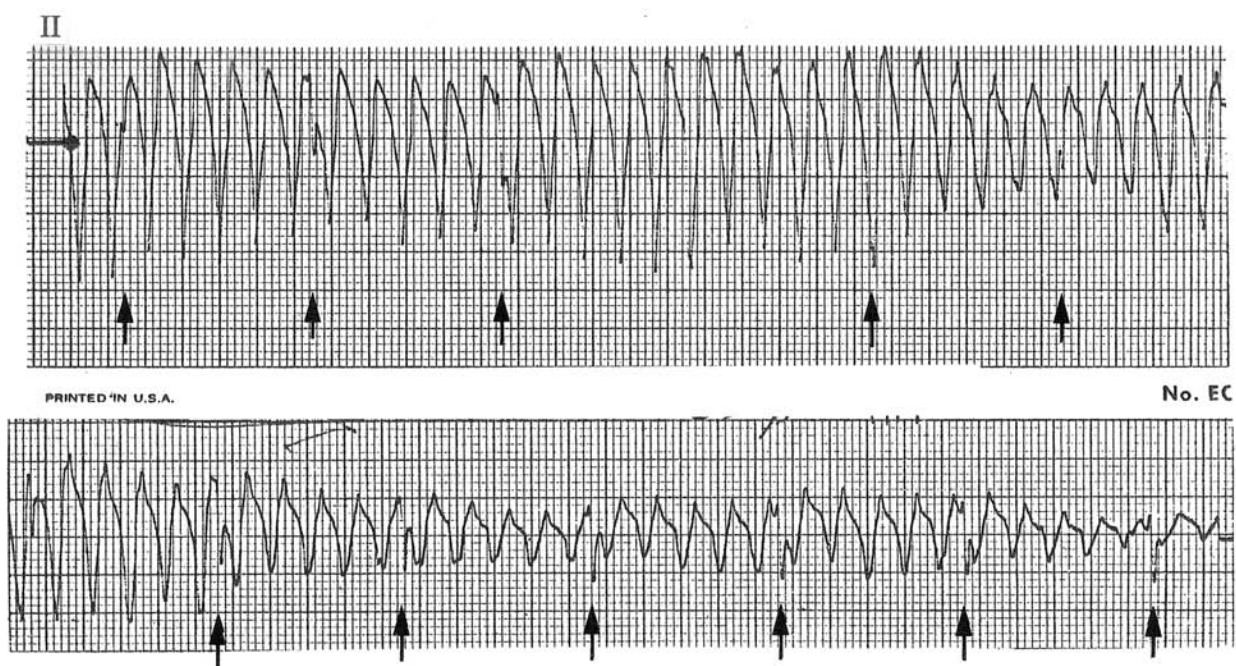
Examples of artifacts mimicking ventricular tachycardia. Regularly occurring QRSs (↑) can be identified in the midst of these artifacts.





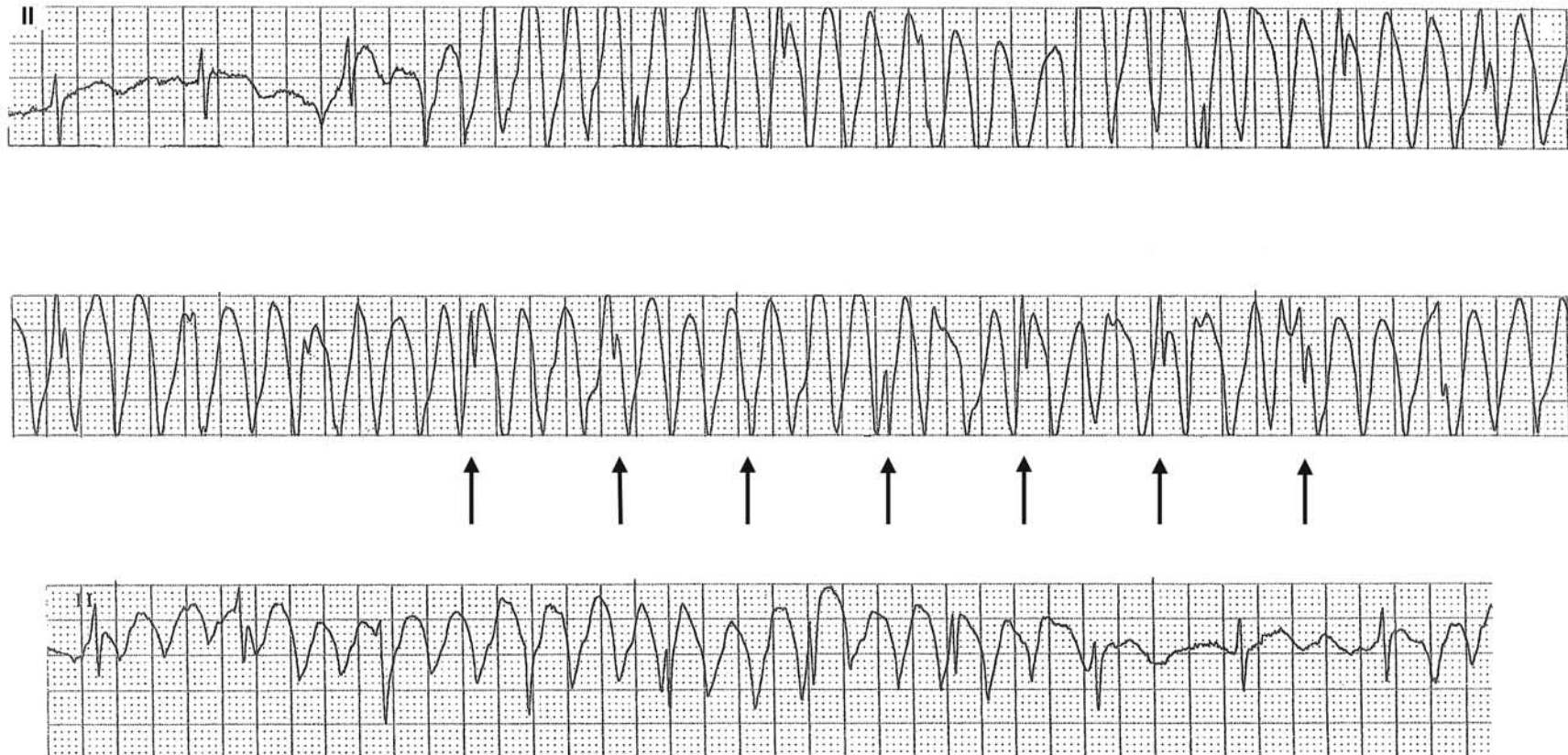
## Artifact

Another example of artifact mimicking either polymorphic ventricular tachycardia or ventricular flutter. Regularly occurring QRSs (↑) can be identified, especially in the bottom strip.



## Artifact Simulating Ventricular Tachycardia

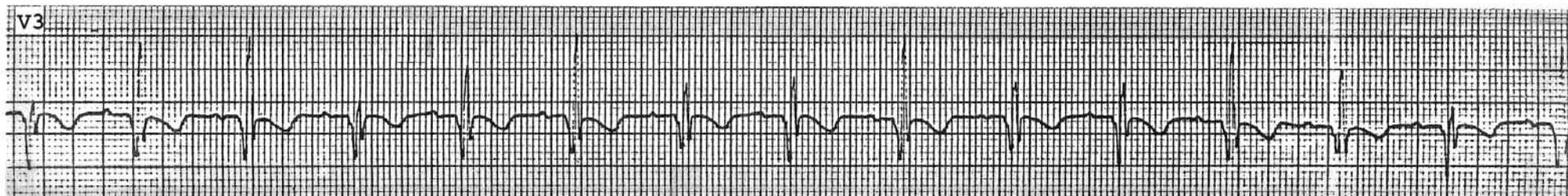
Not everything that one sees in the tracing is generated by the heart. This patient is tapping the chest wall near an electrode, producing what appears to be ventricular tachycardia. Sharp deflections (↑) occur regularly at the same rate as the sinus rhythm present either at the beginning or the end of the tracing, and are undoubtedly QRSs of sinus rhythm.



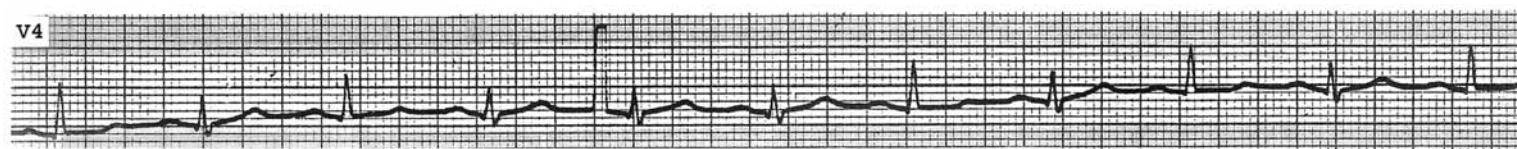


## Respiration Affecting QRS Morphology

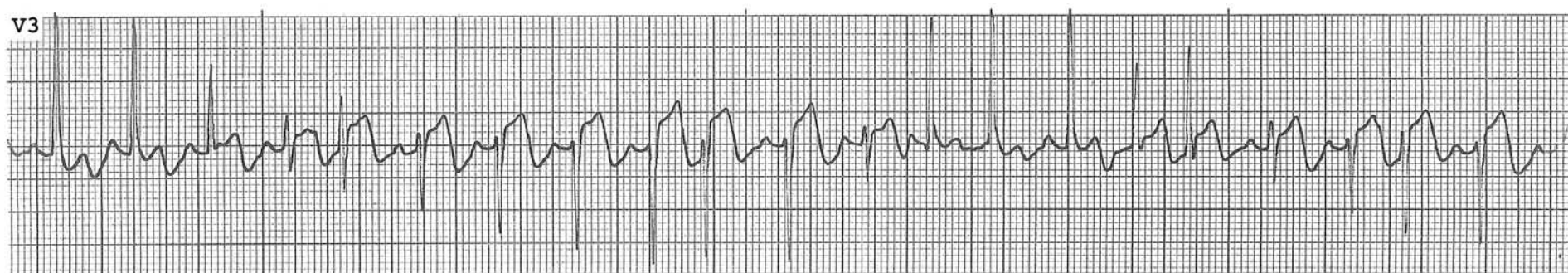Respiratory variation in the QRS morphology may mimic intermittent conduction defect, as shown in this tracing.



Respiratory variation in the QRS morphology may mimic electrical alternans if the respiratory rate is half the cardiac rate, as in this case.



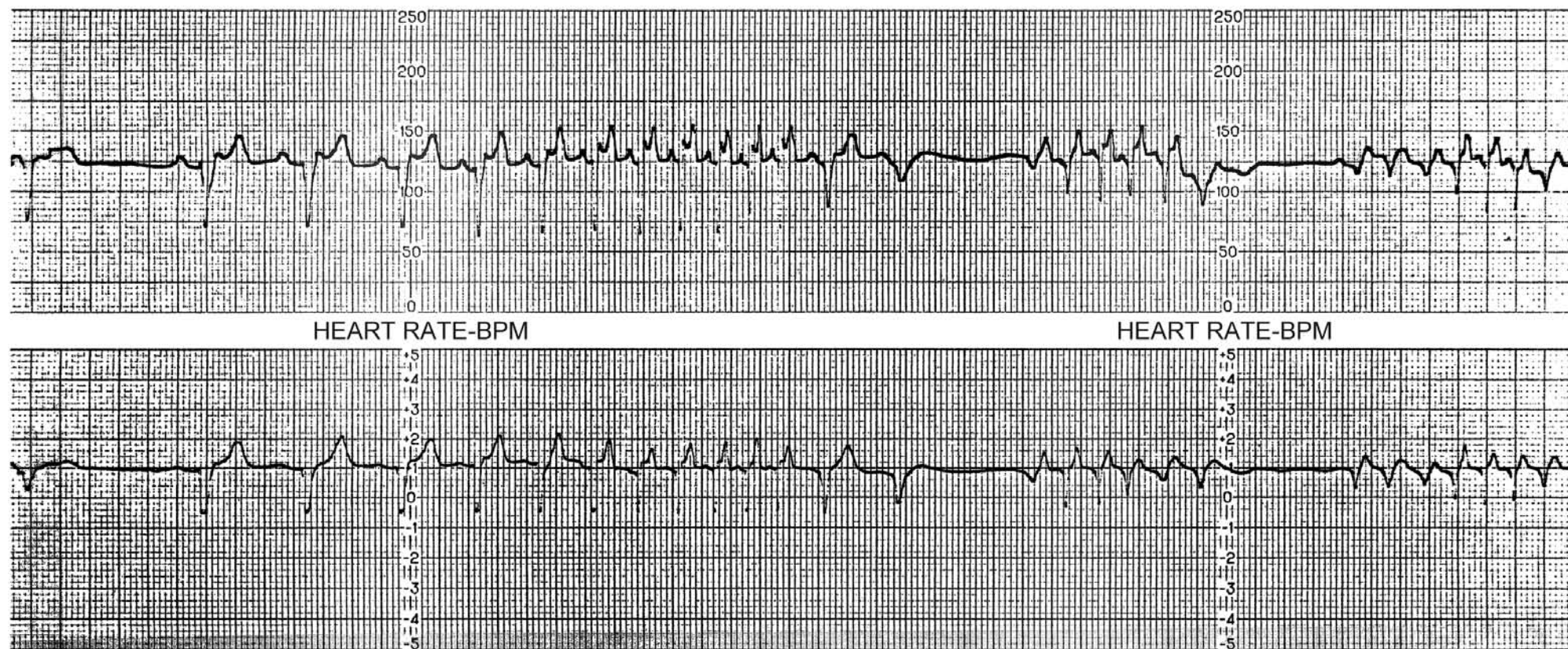
In a transitional lead ( $V_{3-4}$ ), respiratory variations in the QRS morphology can be as marked as in this patient.





## Erratic ECG Monitor Tape Speed

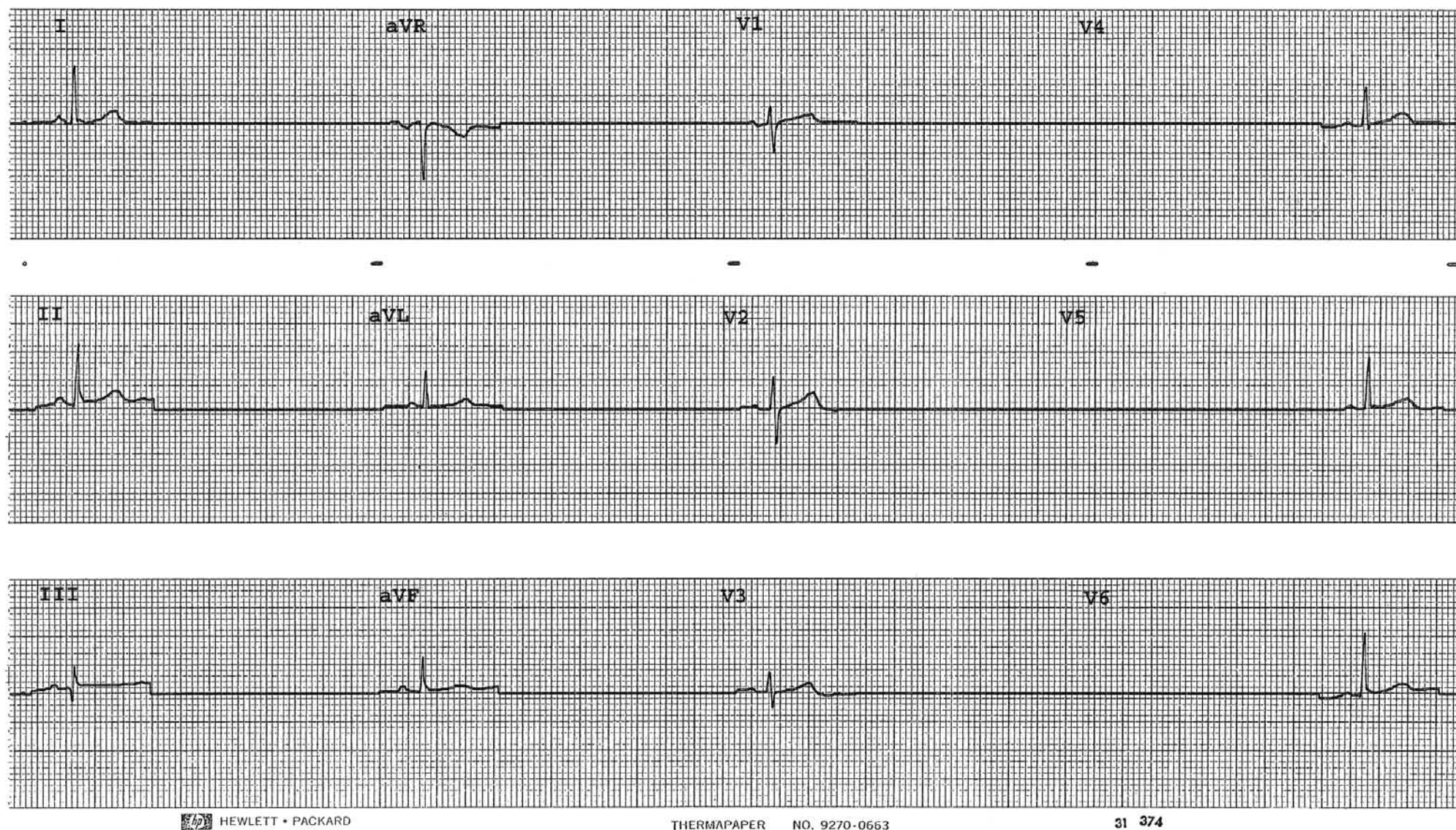
During an ambulatory ECG recording, an erratic tape speed may result in artificially long intervals or extreme “tachycardia” as shown in the tracing below. This erratic behavior can be recognized because components of the tracing are all compressed at the seemingly faster rates, expanded at the slower. The unwary may inadvertently interpret such tracings as a “tachy-brady” syndrome.





## Signal Off, Signal On

When the electrical signal is turned off intentionally or unintentionally, the rhythm strip may simulate long pauses or asystole. In this example, one QRS complex is shown from each lead with the signal blanked out in between. Note that the baseline between the QRSs is as straight as if someone drew a line with a ruler. If there were real pauses or asystole, the baseline would not be as perfectly straight as this.



## Differential Diagnosis of: Narrow-QRS Regular Tachycardia

Sinus Tachycardia:

P wave is diphasic (initially positive, then negative) in V1 and entirely positive in II

Atrial tachycardia:

There is a P wave in front of each QRS but not a sinus-P wave

SVT (junctional tachycardia, AV junctional re-entrant tachycardia, AV re-entrant tachycardia)

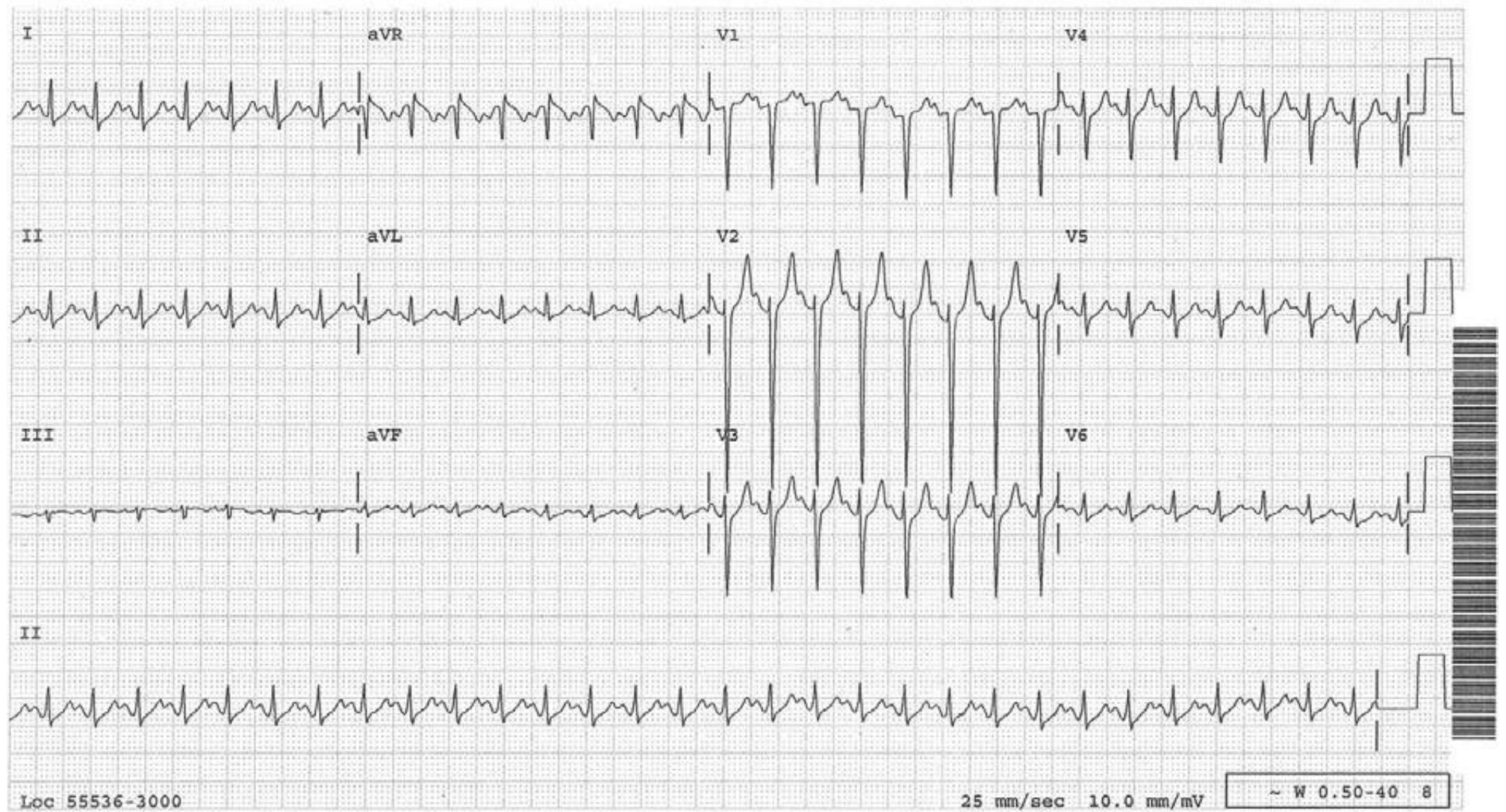
No P wave or inverted P wave in front of or after the QRS

Atrial flutter with 2:1 AV conduction:

In the inferior leads, the baseline continuously slopes up, then slopes down without isoelectric baseline.

V1 or aVR may reveal two atrial activities for each QRS.

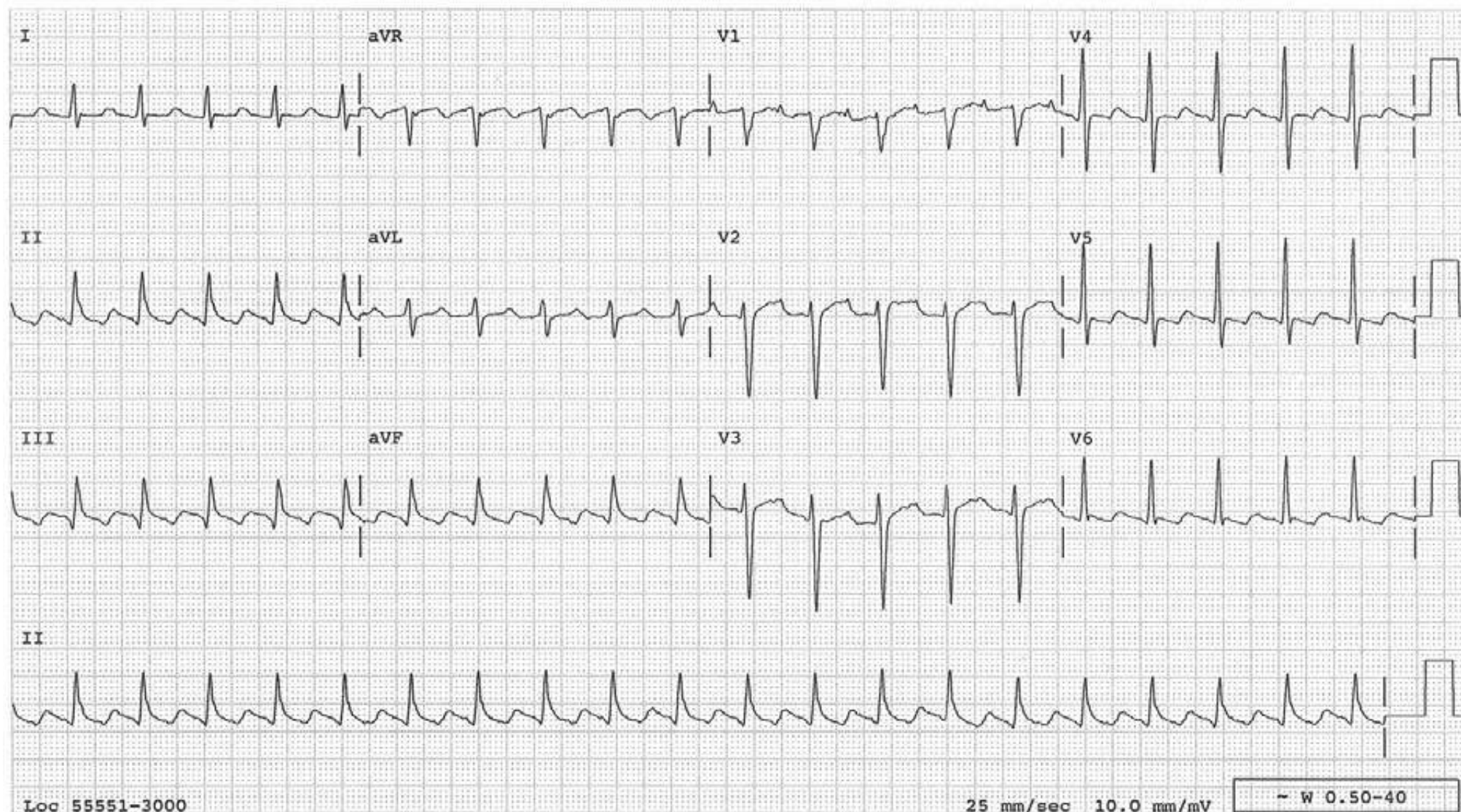




Answer: Sinus tachycardia

Discussion: The P wave is diphasic (positive, then negative) in V1 and is entirely positive in lead II indicating that these are sinus P waves.

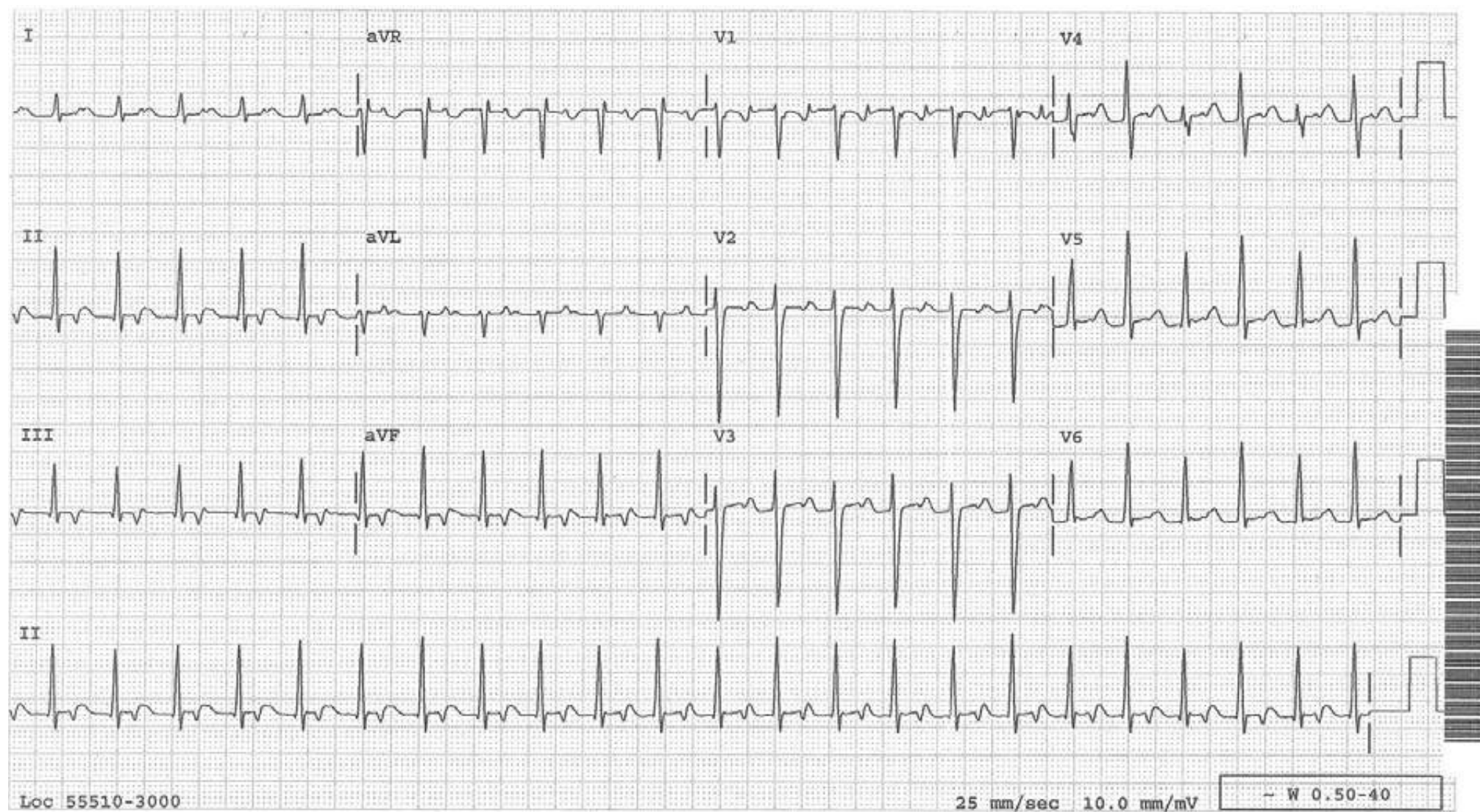




Answer: Atrial flutter with a 2:1 AV conduction

Discussion: One atrial activity is seen between the QRSs in V1. This atrial activity has biphasic (positive, then negative) configuration, highly suggestive of sinus P wave. These findings will certainly raise the possibility of sinus tachycardia with a slightly prolonged PR interval. However in the inferior leads, the baseline slopes up then slopes down in a regular fashion without any isoelectric line in between and this is typical of atrial flutter waves.

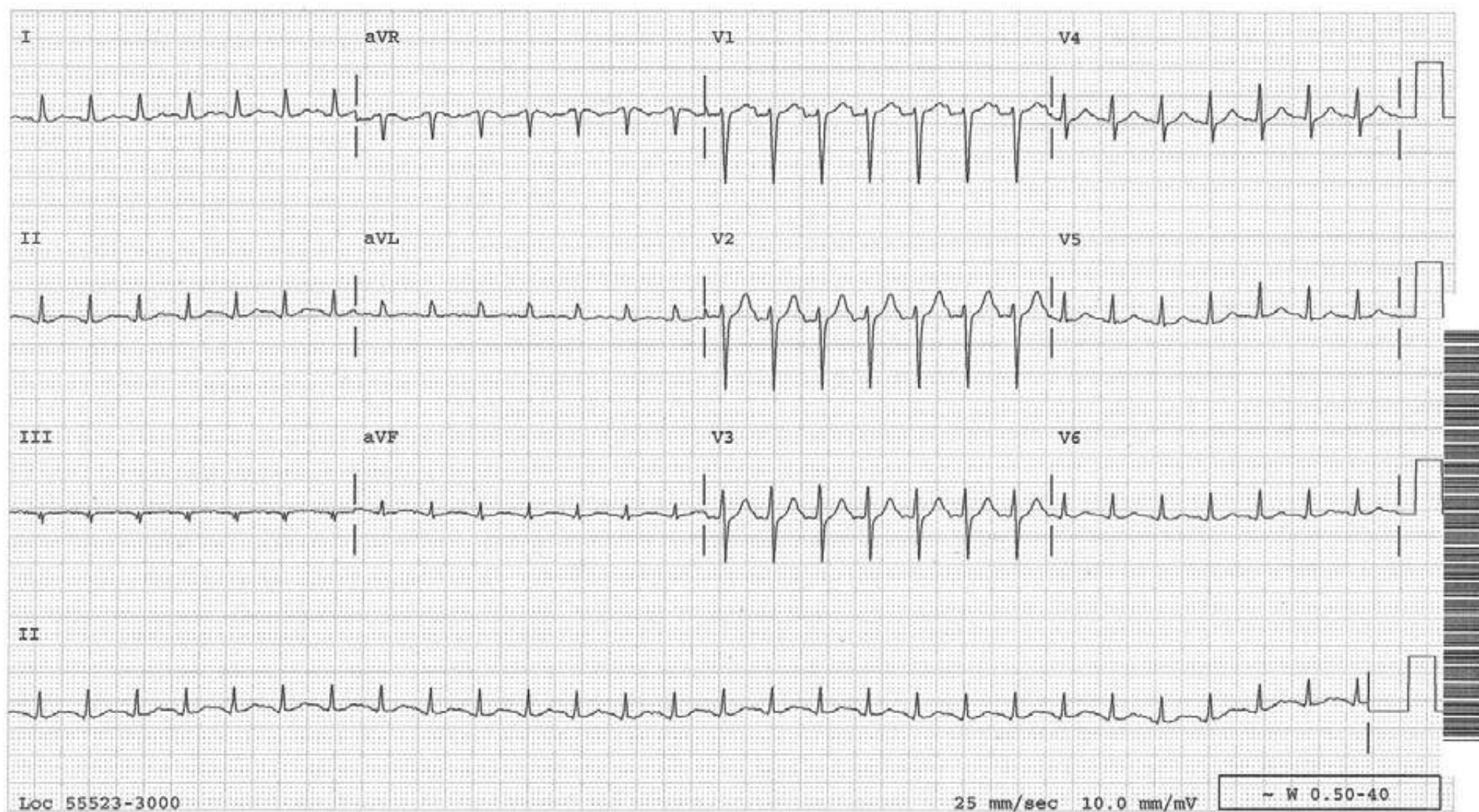




Answer: SVT

Discussion: One atrial activity is present in front of each QRS in many leads, especially in V1. This atrial activity is entirely negative in lead II and this rhythm could be either atrial tachycardia or AV junctional reentrant tachycardia but clearly not sinus tachycardia.

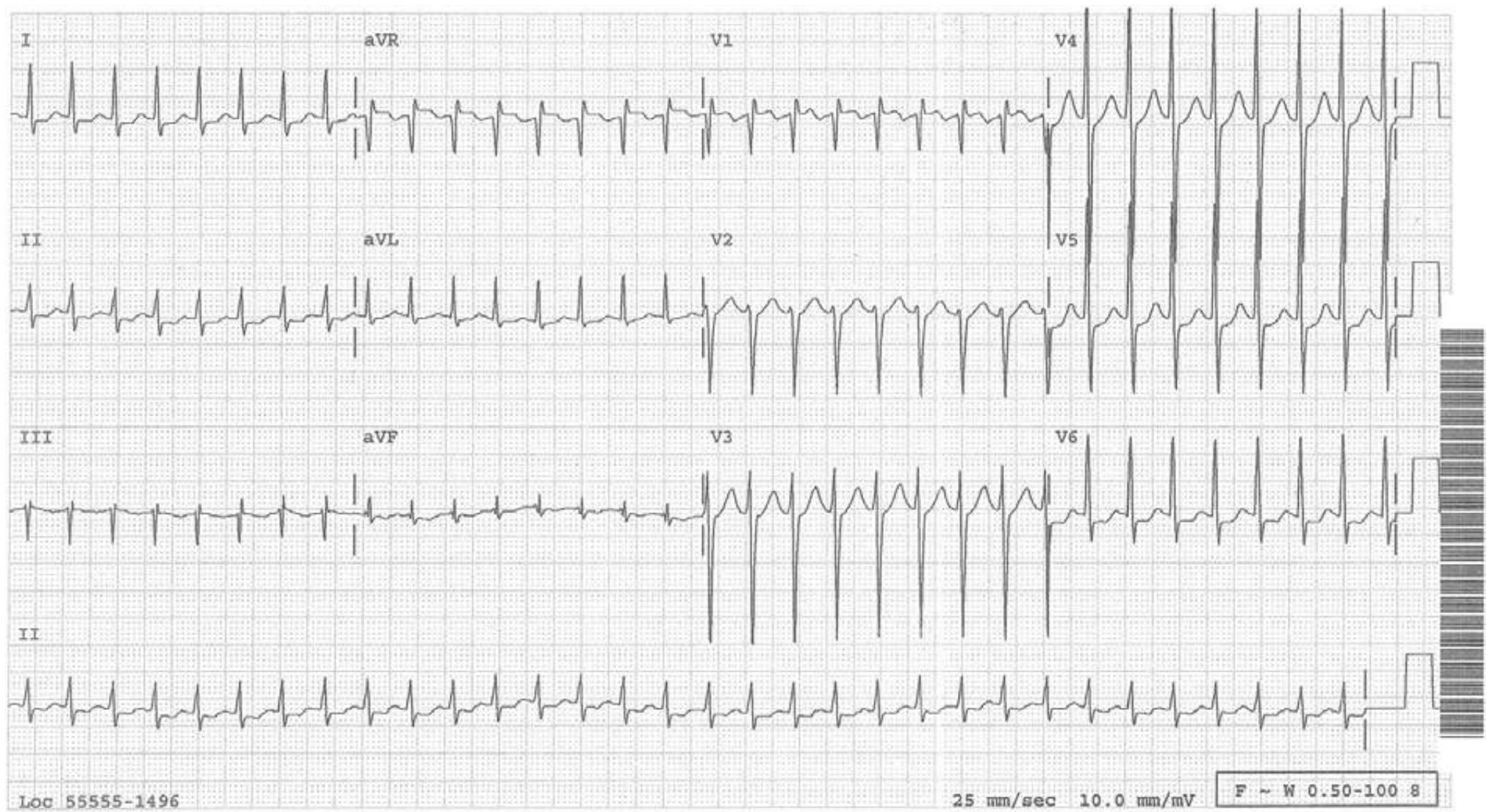




Answer: Sinus tachycardia

Discussion: Diphasic (positive, then negative) P wave is appreciable in V1. In lead II one can make out, with a stretch of imagination, a relatively flat but positive P wave.

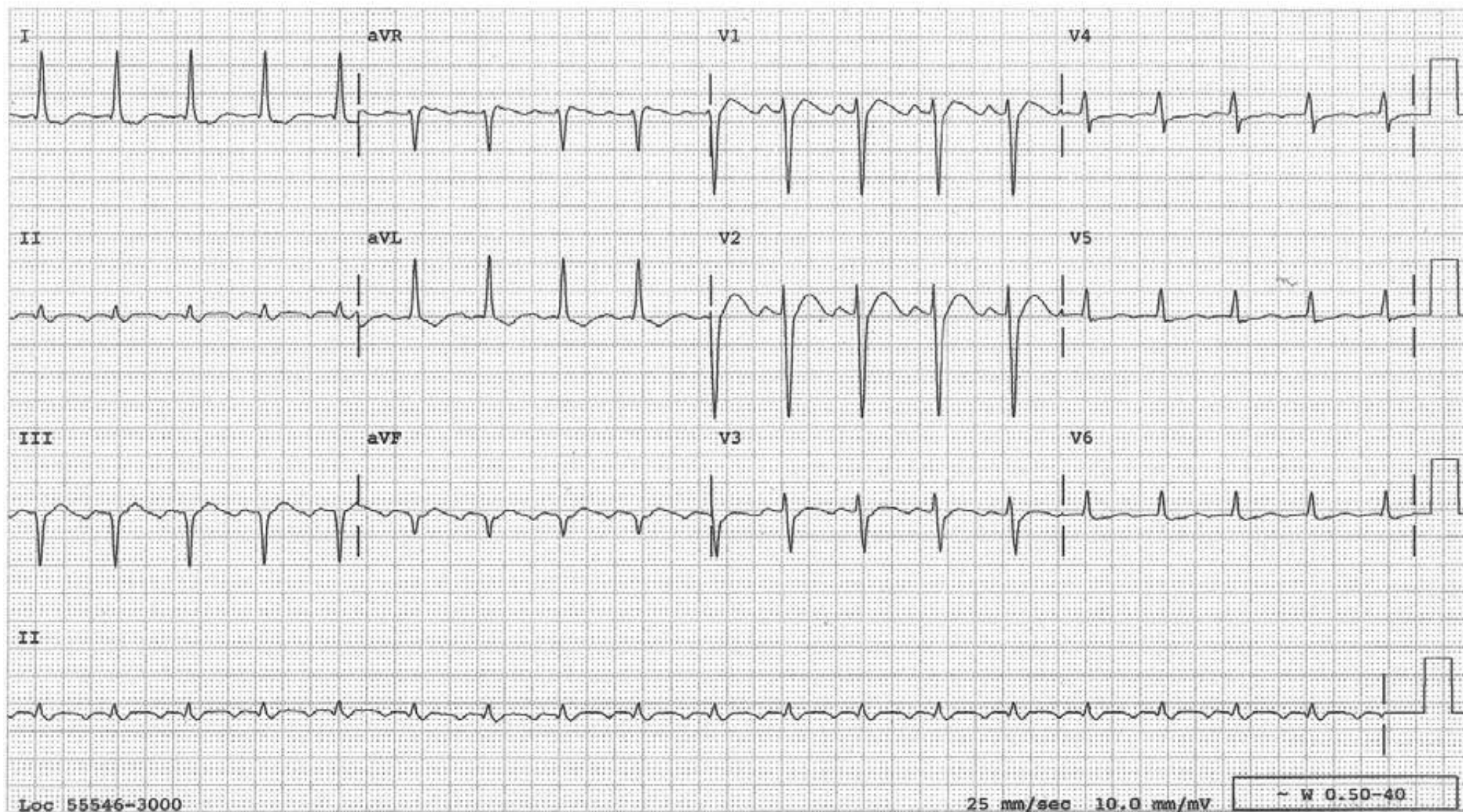




Answer: SVT

Discussion: No atrial activities, either positive or negative, can be identified. This is an example of SVT in which the P wave is hidden completely within the QRS.

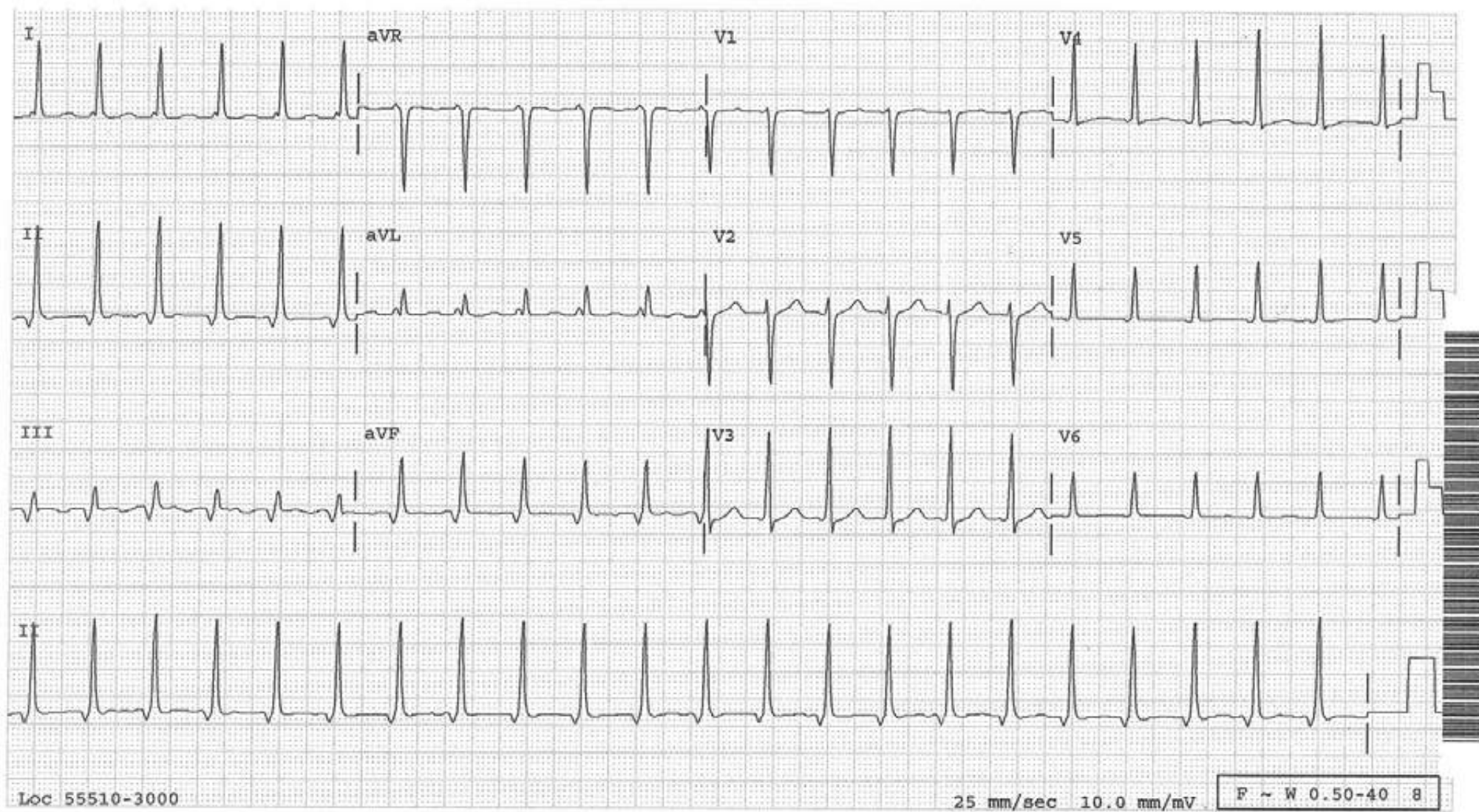




Answer: Atrial flutter with at 2:1 AV conduction

Discussion: Leads V1 and V2 suggest one P wave in front of each QRS raising the possibility of sinus tachycardia. However in the inferior leads, especially in lead II, there are “domes” of flutter waves.

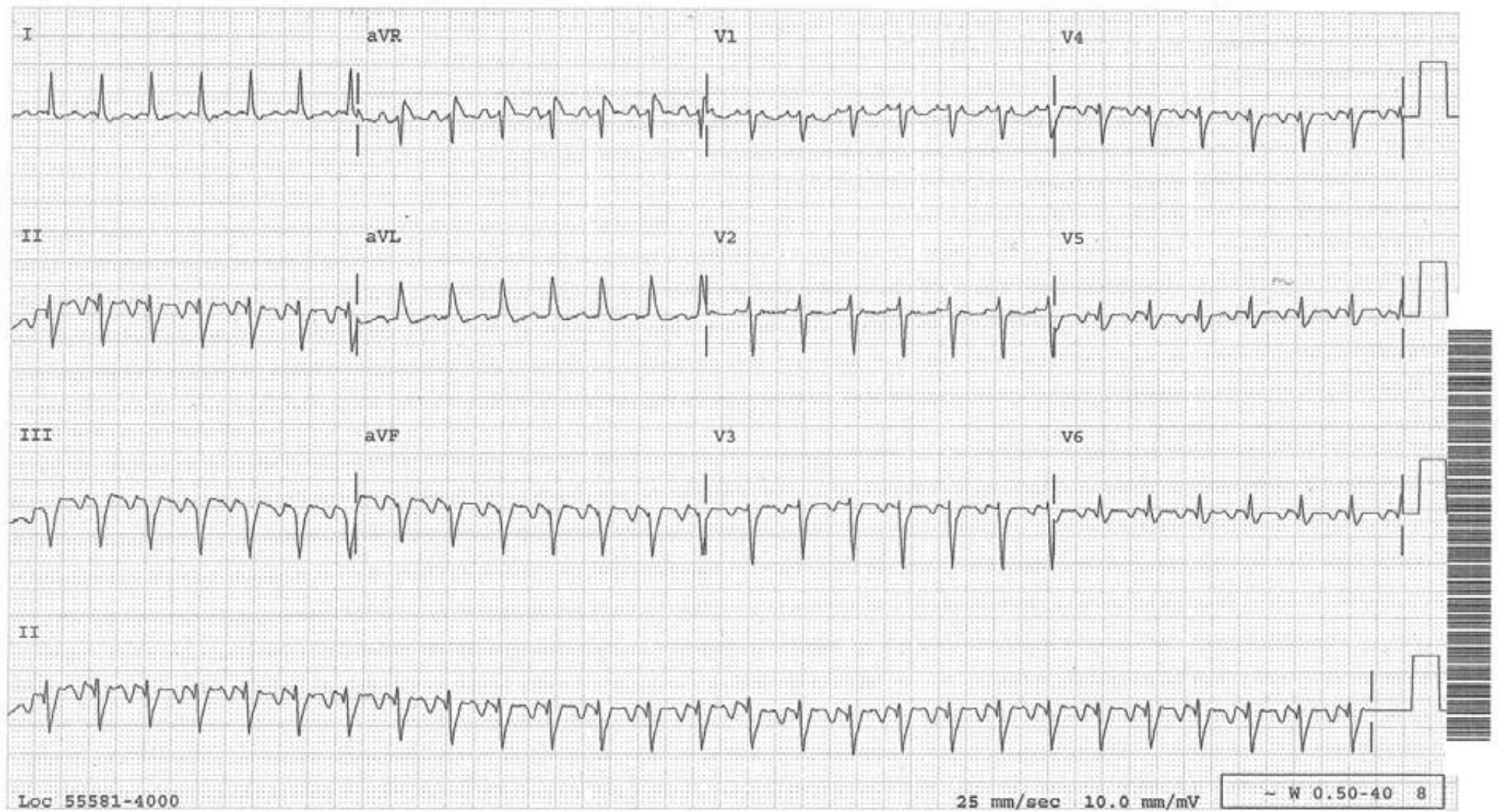




Answer: SVT

Discussion: The negative deflection in front of the QRS in inferior leads is actually a retrograde P wave. A good example of SVT with a retrograde P wave in front of the QRS.





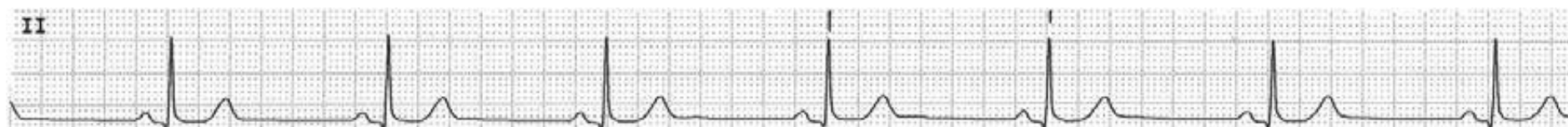Answer: Atrial flutter with 2:1 AV conduction

Discussion: Two atrial activities occurring regularly at a rate of 330 are evident in V1. Atrial rate close to 300/minute is hardly anything but atrial flutter. Armed with this information one can go to the inferior leads and make the sawtooth pattern of flutter waves whether one sees it or not.




## Differential Diagnosis of Regular Narrow QRS Bradycardia I

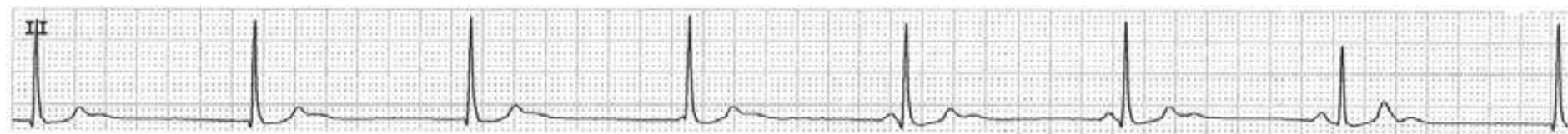
Sinus bradycardia



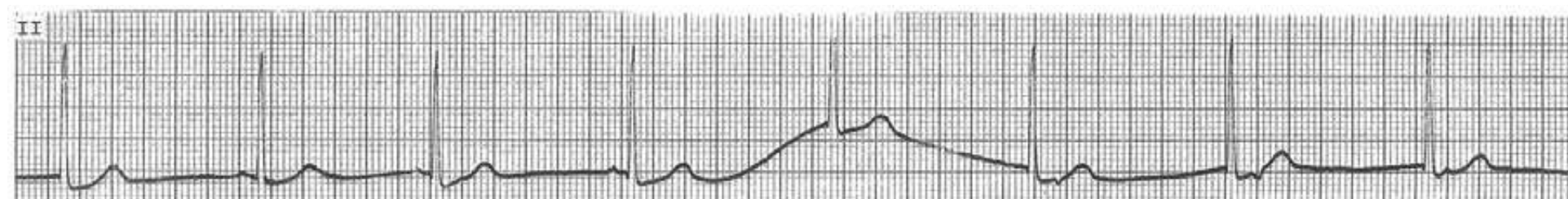
Junctional escape rhythm with 1:1 retrograde conduction



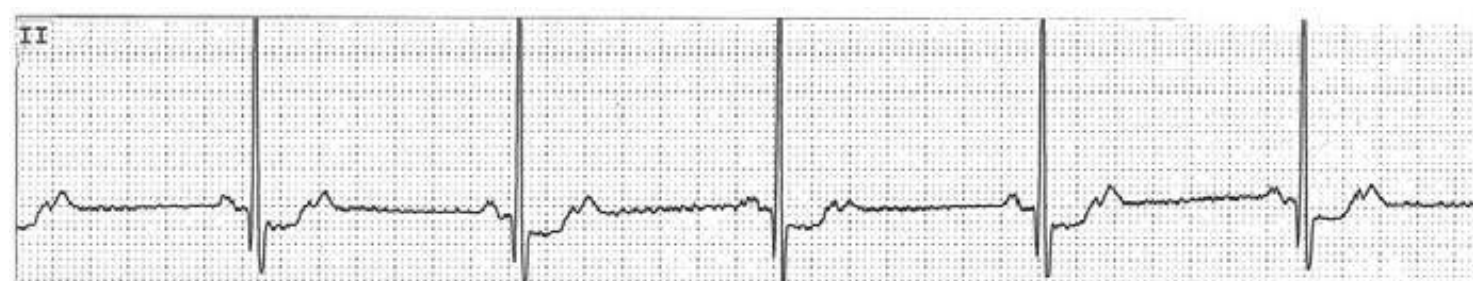Junctional escape rhythm with AV dissociation



Junctional escape rhythm with AV dissociation/retrograde conduction

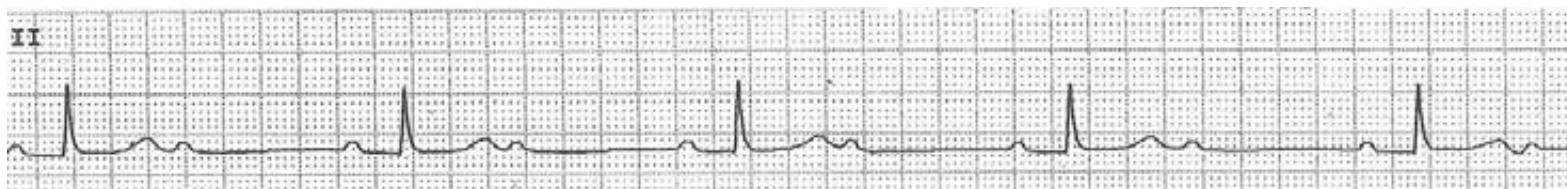


Non-conducted atrial bigeminy

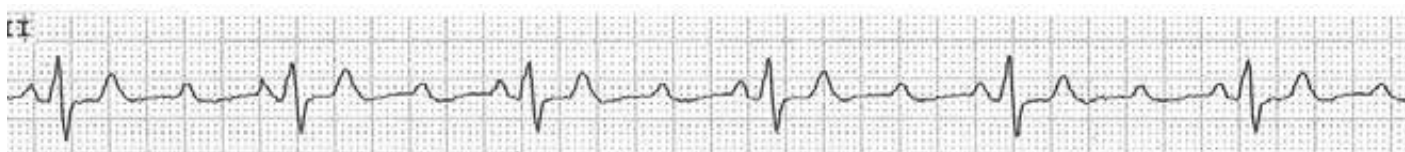

## Differential Diagnosis of Regular Narrow QRS Bradycardia II

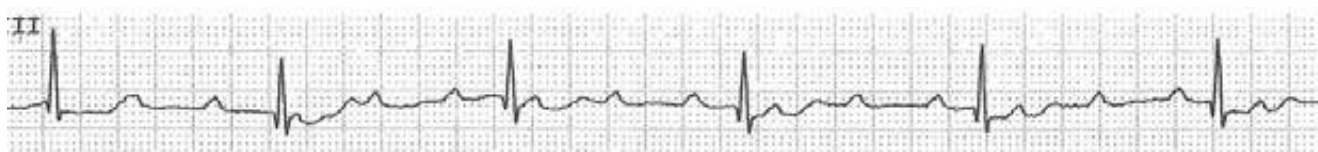2:1 AV block




3:1 AV block



Complete AV block during sinus rhythm



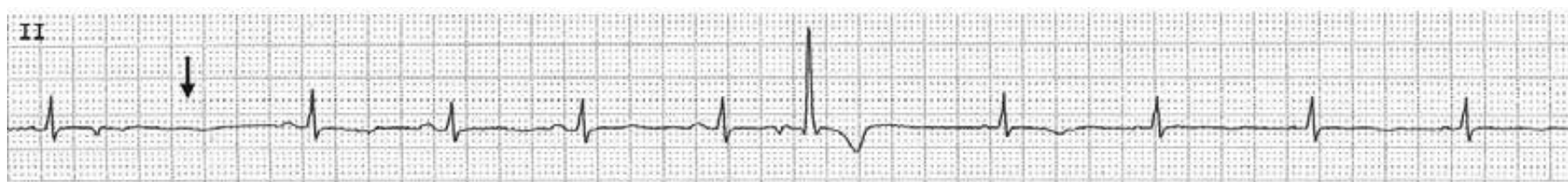Complete AV block during atrial fibrillation



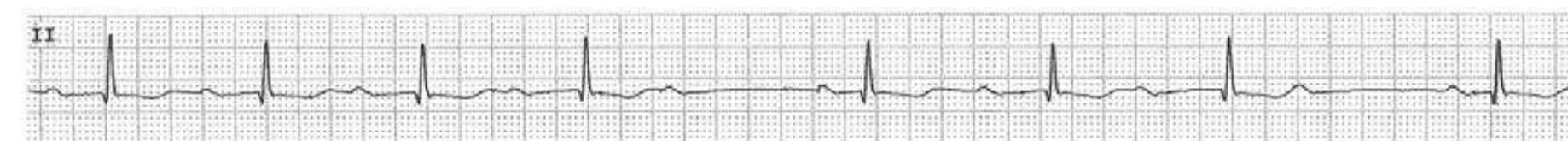


## Differential Diagnosis of Pauses

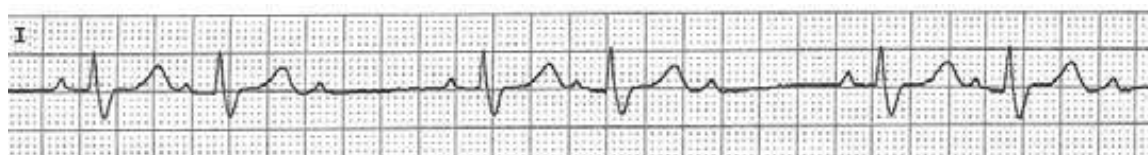
Non-conducted APB



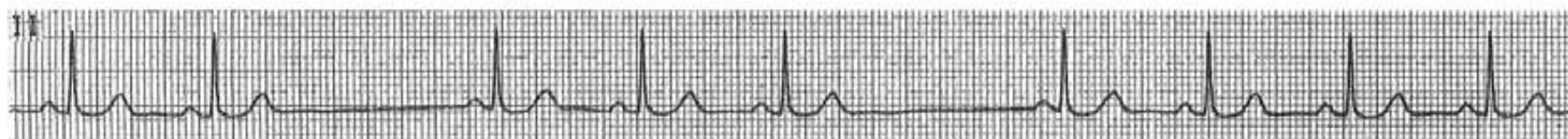AV Wenckebach phenomenon



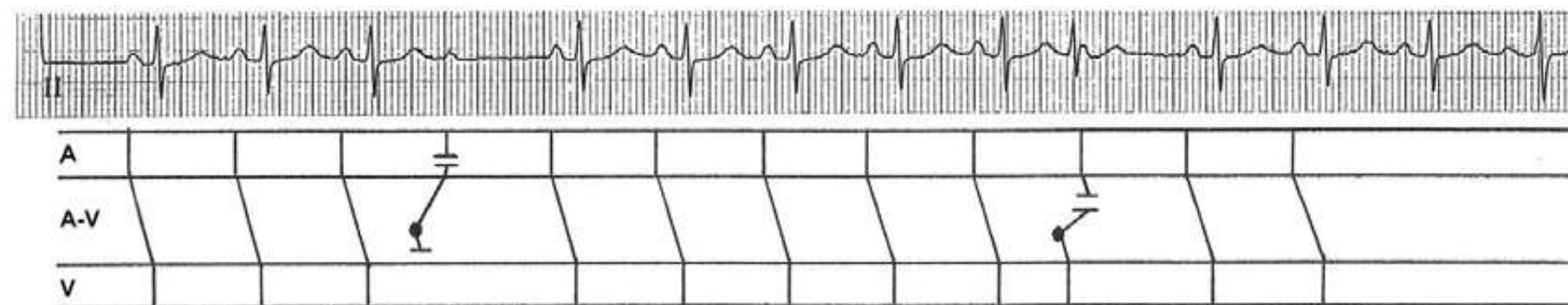
Type II 2° AV block



S-A block



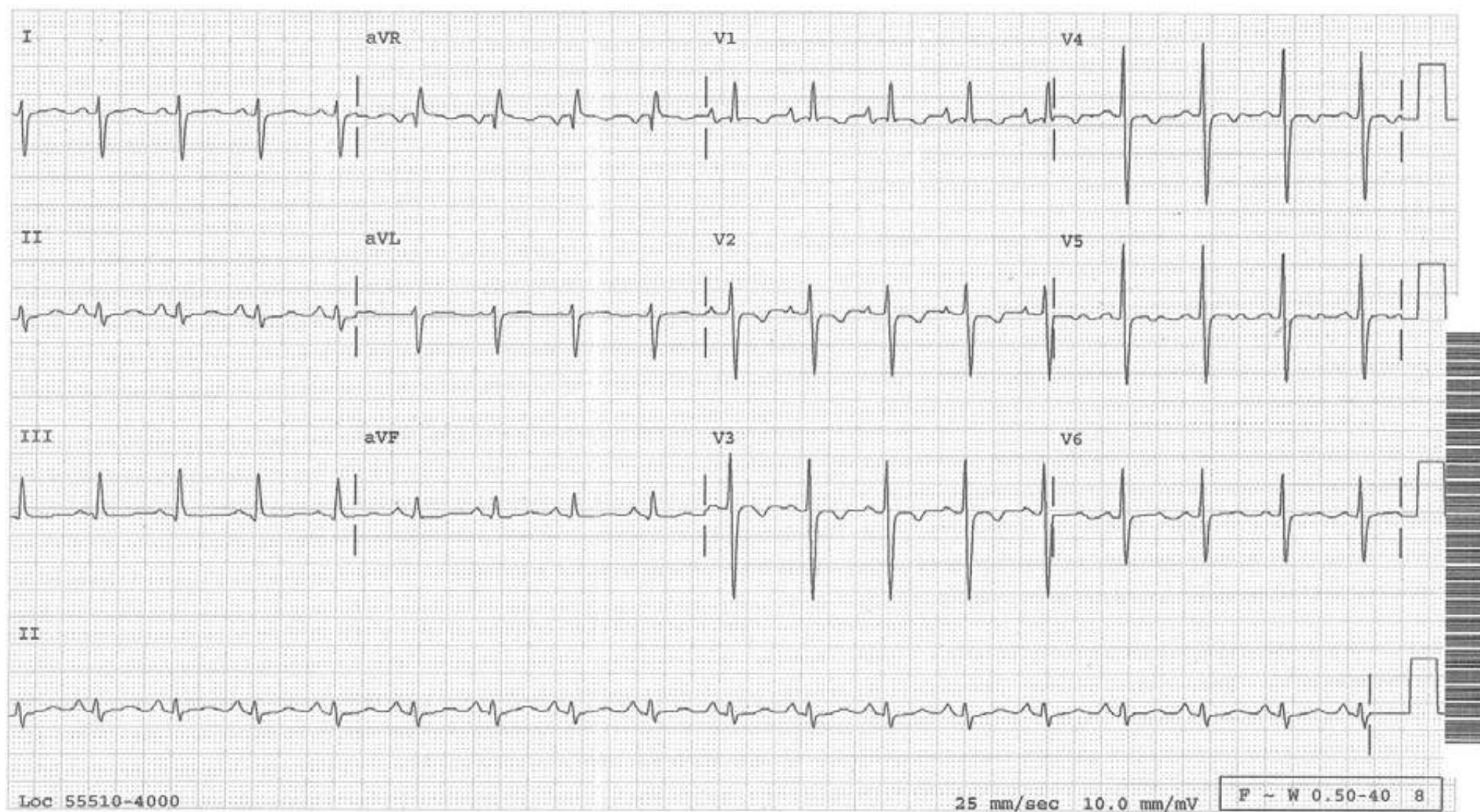
Concealed junctional premature impulse



## Differential Diagnosis of Tall R Waves in the Right Precordial Lead

- a. RVH
  - RAD and deep S waves in V6
- b. Posterior Infarction
  - Often supporting evidence is present in the inferior or lateral leads since it occurs often as infero-posterior or postero-lateral infarction.
  - Acute: ST depression in the right precordial leads which is ST elevation of posterior wall registered reciprocally
  - Old: No ST-T changes
- c. Some cases of WPW syndrome
  - Short PR interval and typical delta waves are present in some or all leads
- d. Reversed precordial leads
  - The lead with the most diphasic (initially positive, then negative) P waves is V1

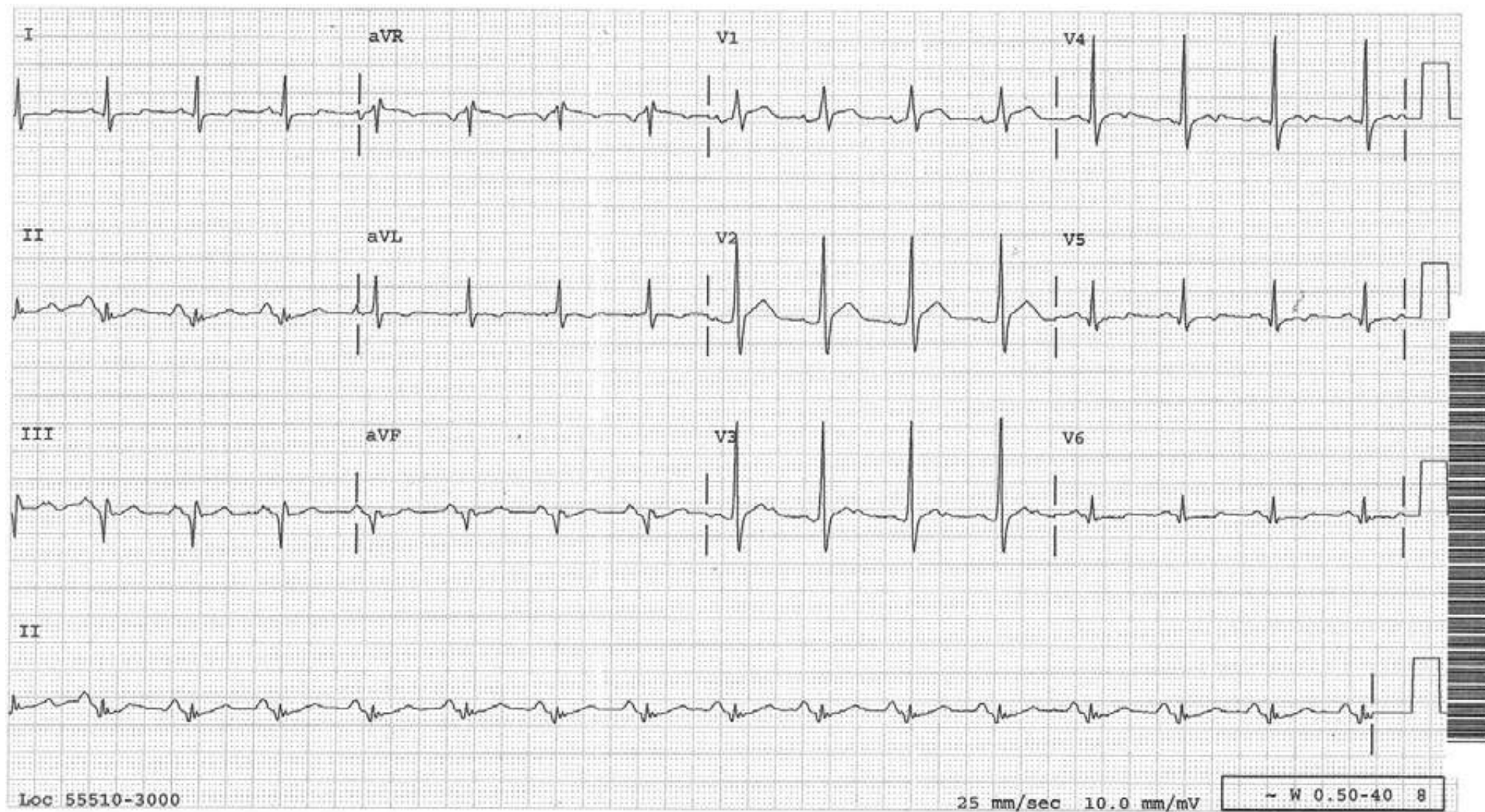




Diagnosis: RVH

Discussion: The QRS axis is deviated to the right. Right axis deviation (RAD) should make one think first of RVH. After RAD, all other diagnostic features of RVH are found in the precordial leads and include tall R waves in V1, deep S waves in V6 and ST-T changes in V1-3. All of these features are present in this tracing. This tracing is from a patient with severe RVH due to primary pulmonary hypertension.

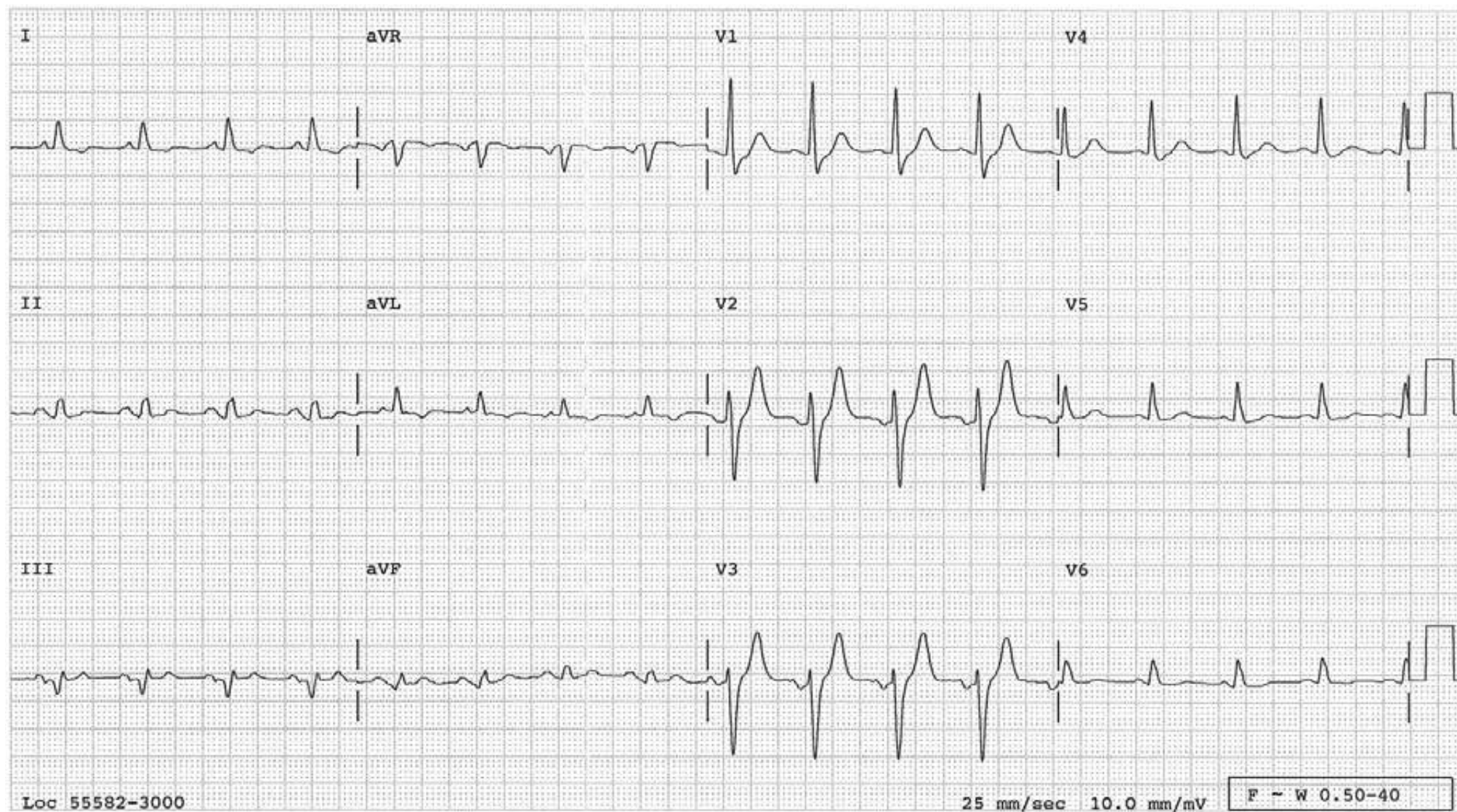




Diagnosis: Inferoposterior infarct

Discussion: Pathologic Q waves in leads II, III and a VF indicate inferior infarction. When the electrical force is lost in the posterior wall from an infarction, the QRS vector will be directed anteriorly, resulting in tall R waves in the right precordial leads as seen in this tracing.

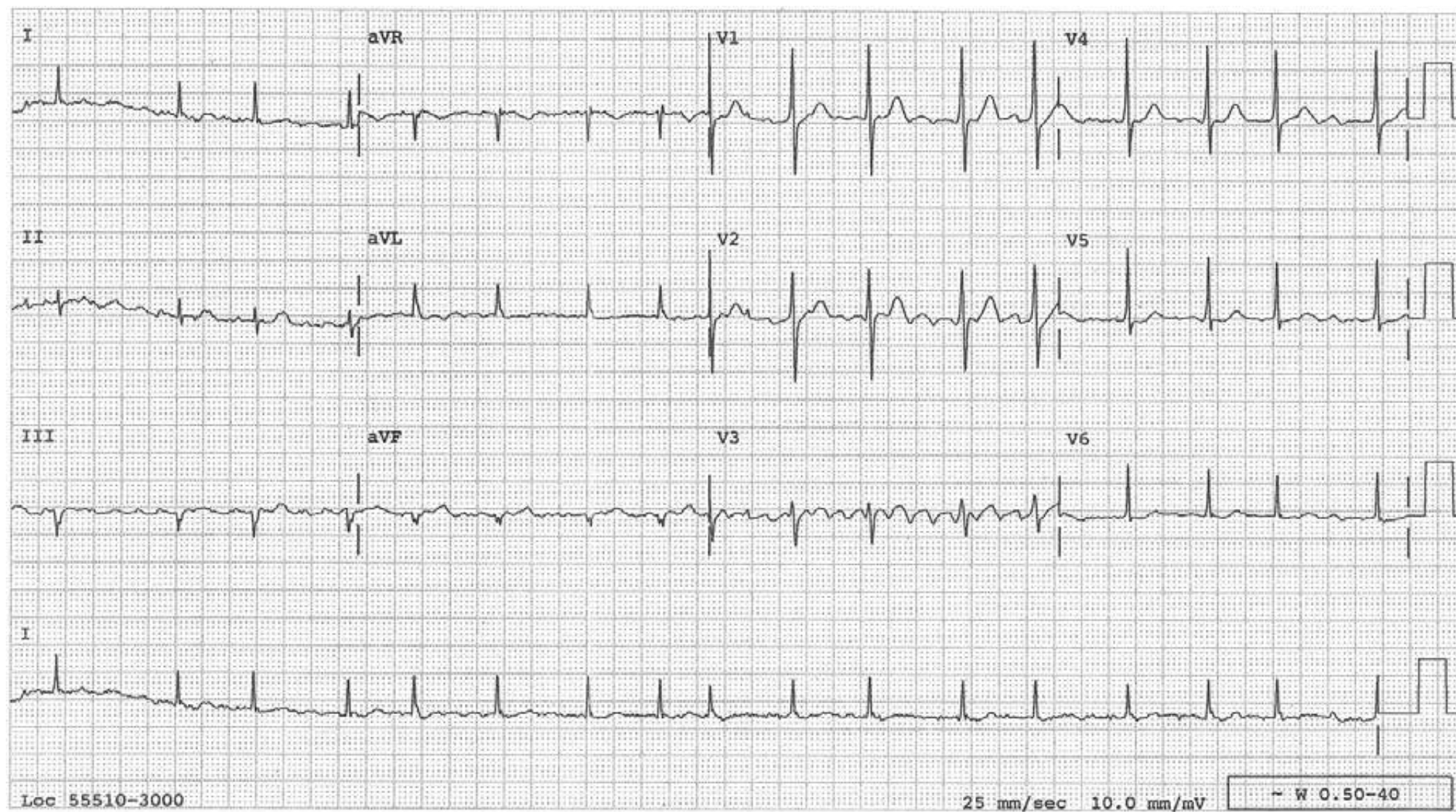




Diagnosis: Inferior infarct and reversed V1-V3 leads

Discussion: Inferior infarct is obvious. The P wave is diphasic in V3 and entirely positive in V1, proving that these leads are reversed.

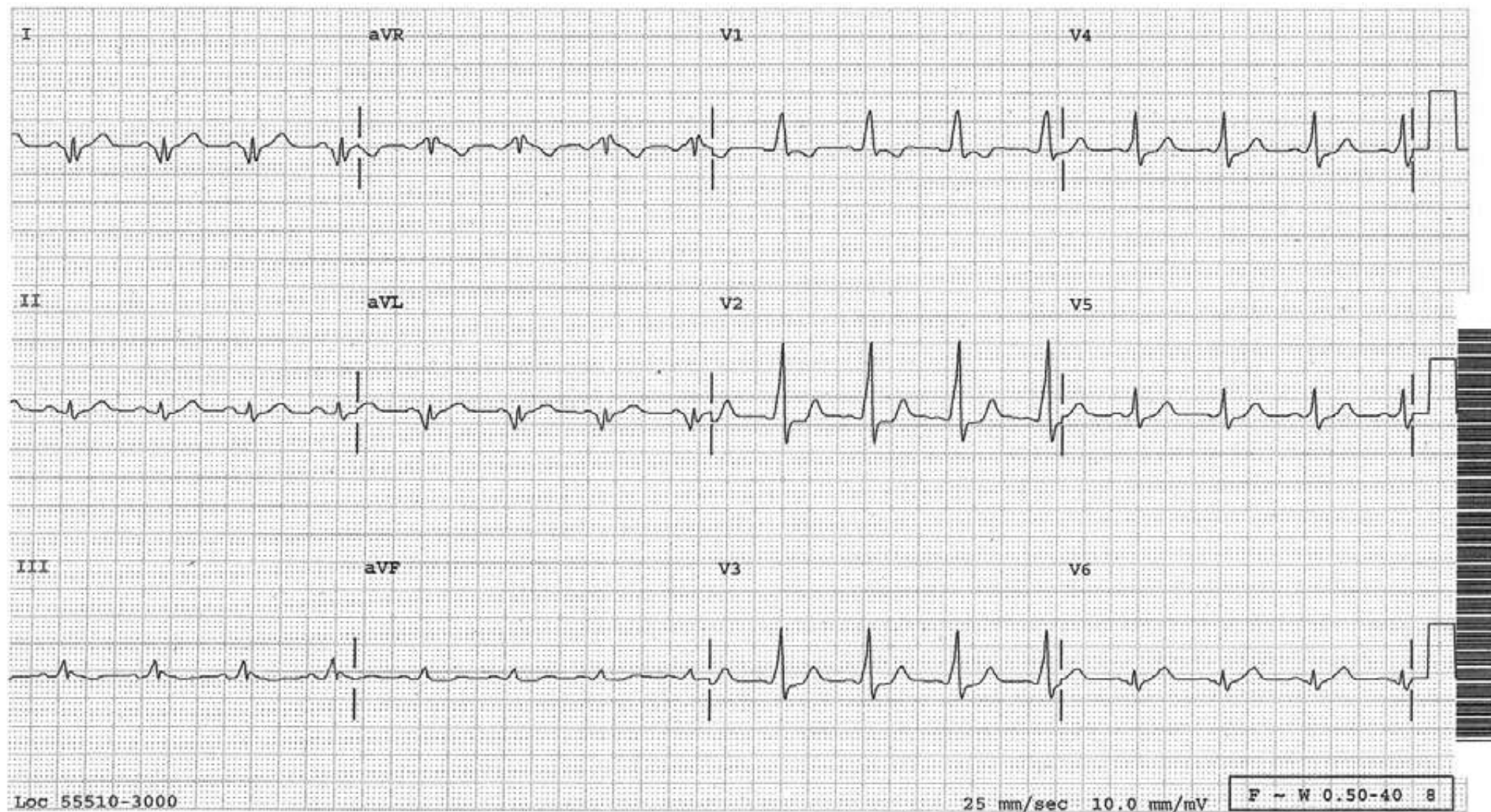




Diagnosis: Reversed V1-V3 leads

Discussion: The fibrillatory waves are most prominent in V3 and less so in V1, indicating that these leads are reversed.

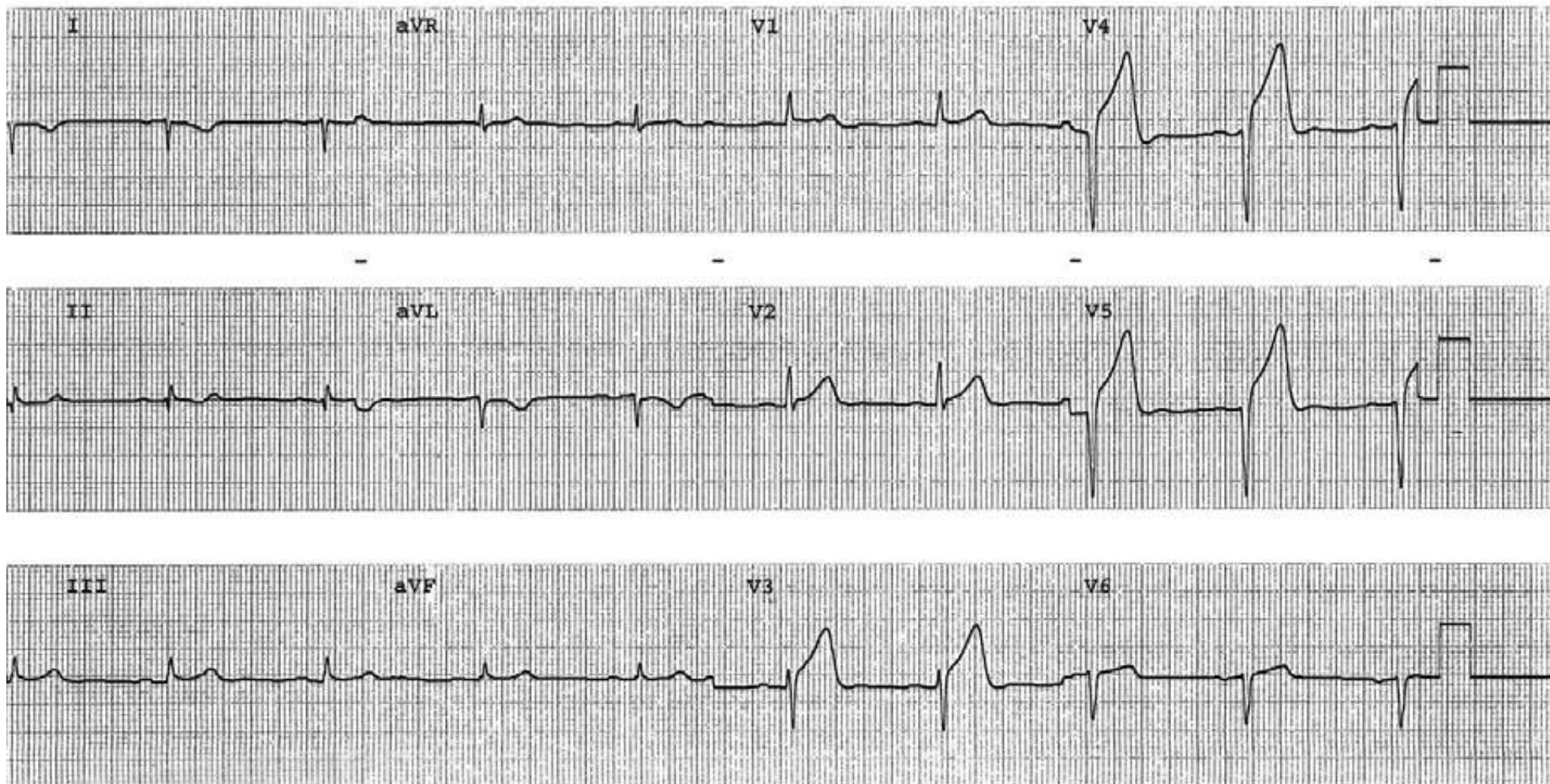




Diagnosis: WPW syndrome

Discussion: At first glance, the tracing appears to show posterolateral infarct with pathologic Q waves in I and aVL. However, these are not Q waves but negative delta waves. Note the PQ interval is short. In V2-4, the PR interval is short and the upstroke of the QRS is slurred. These are diagnostic of WPW syndrome.





Diagnosis: Reversed entire precordial leads and arm leads

Discussion: P waves are diphasic in V6 and entirely upright in V1, proving that these leads are reversed. In fact, judging from the R wave progression, all of the precordial leads are reversed. The upside-down P, QRS and T waves in lead I indicate reversed arm leads as well. This is not an example of dextrocardia. In dextrocardia, the R waves are not tall in the right precordial leads. Findings of acute anterior infarct are also present.

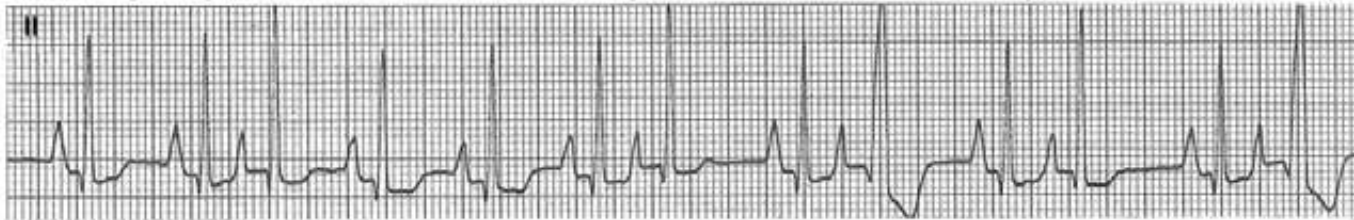

## Bigeminal Rhythm (I)

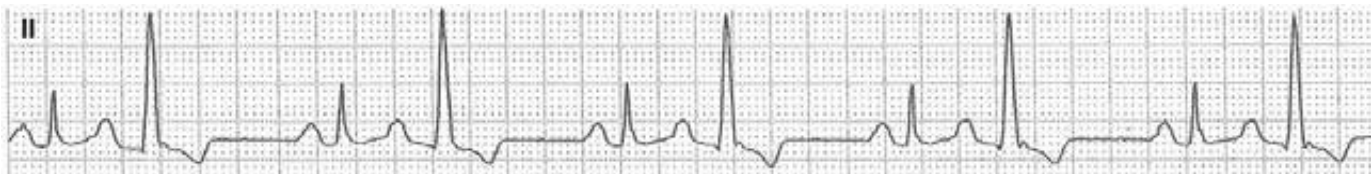Atrial bigeminy, i.e. every other beat is an atrial premature beat.



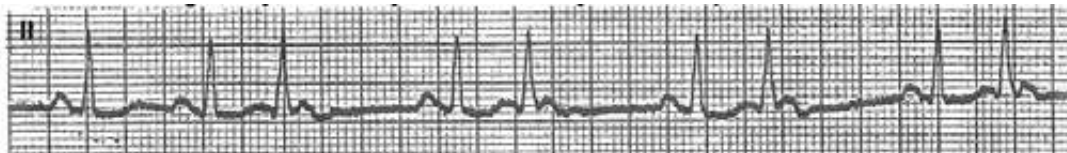
Atrial bigeminy. Some APBs are almost normally conducted, some are aberrantly conducted.



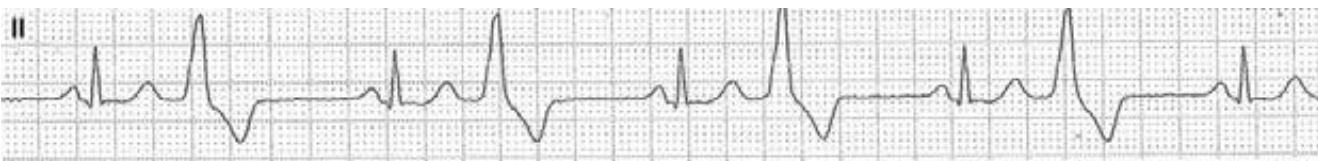Atrial bigeminy with aberrant conduction. The premature P wave is superimposed on the T wave.



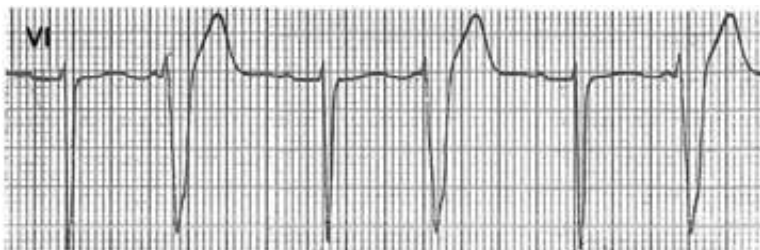Junctional bigeminy, i.e. every other beat is a junctional premature beat.



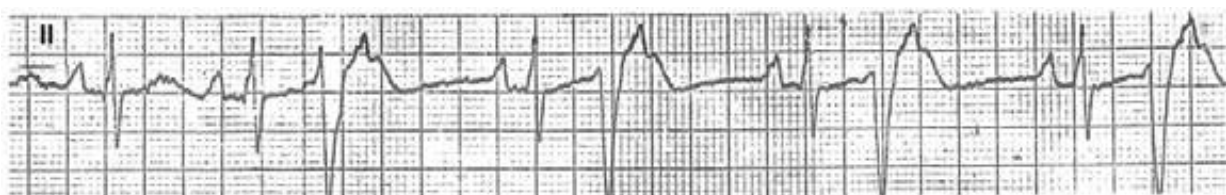
Ventricular bigeminy, i.e. every other beat is a ventricular premature beat.



Ventricular bigeminy with a sinus P wave in front of the QRS.

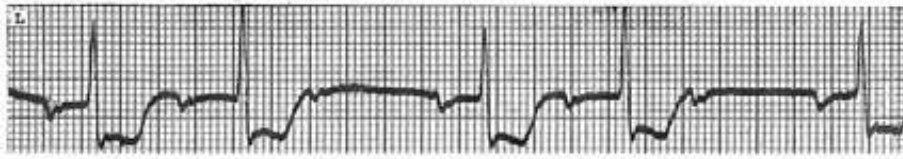


Ventricular bigeminy with a sinus P wave after the QRS.

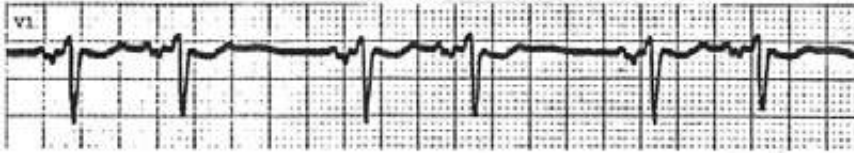

## Bigeminal Rhythm (II)

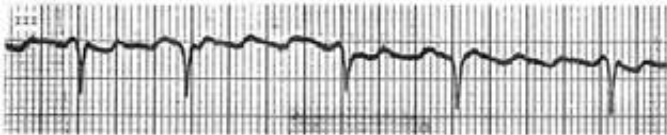
AV Wenckebach phenomenon with 3:2 conduction ratio



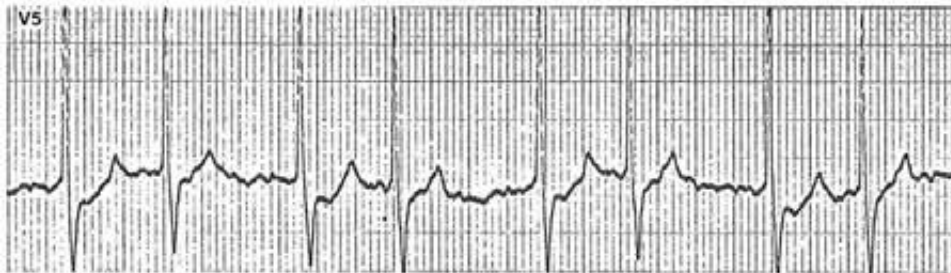
SA Wenckebach phenomenon with 3:2 conduction ratio



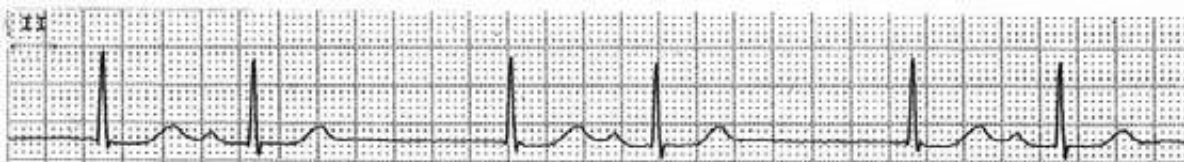Atrial flutter with alternating 3:1 and 4:1 AV conduction ratio



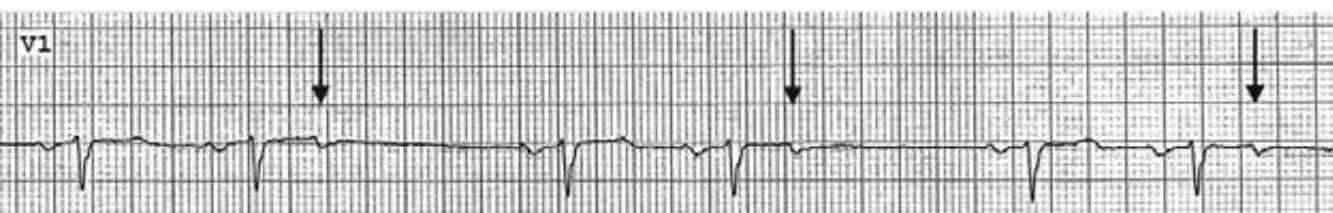Junctional tachycardia with 3:2 exit block during atrial fibrillation



Sinus bradycardia with junctional escape beats



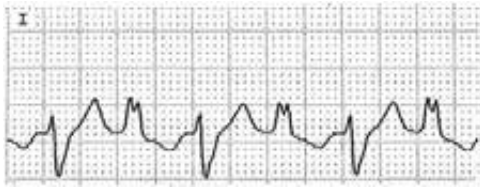
Non-conducted atrial trigeminy, i.e., every third impulse is an atrial premature impulse ( $\downarrow$ ), which occurs during refractory period and does not conduct to the ventricles.



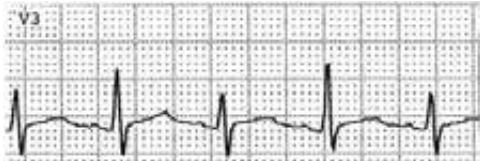

## Changing QRS Axis or Morphology (I)

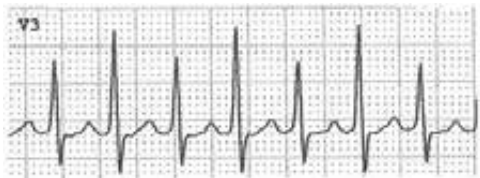Bidirectional tachycardia, highly specific for digitalis toxicity or aconite poisoning



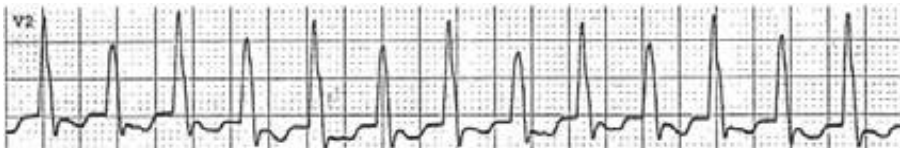Electrical alternans during sinus rhythm; specific for cardiac tamponade



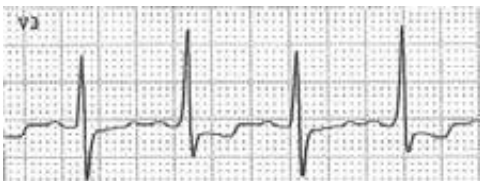Electrical alternans during SVT; does not reflect pericardial problems



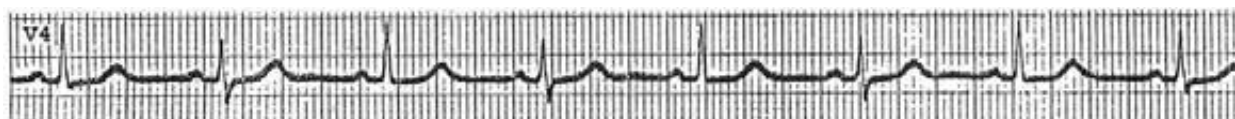
Electrical alternans during VT; does not reflect pericardial problems



Pre-excitation of alternate beats simulating electrical alternans.




Respiratory variation in QRS axis simulating electrical alternans when the respiratory rate is half of the cardiac rate

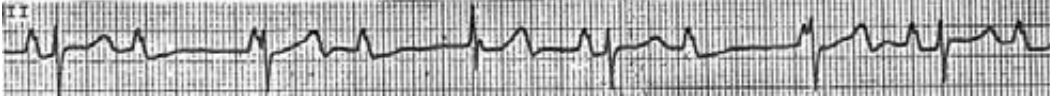

## Changing QRS Axis or Morphology (II)

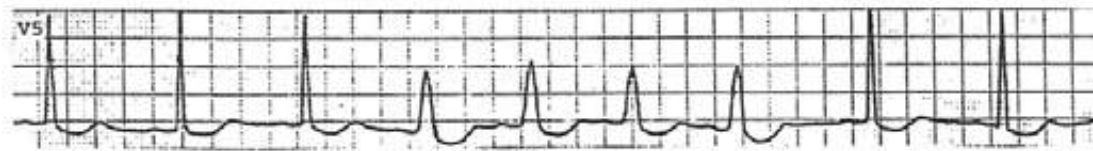
Changing QRS height is due to the timing of the QRS in relationship to the flutter waves. If a QRS occurs on top of the dome of a flutter wave, a taller QRS results. If it occurs in the valley of the flutter wave, the QRS height is reduced.



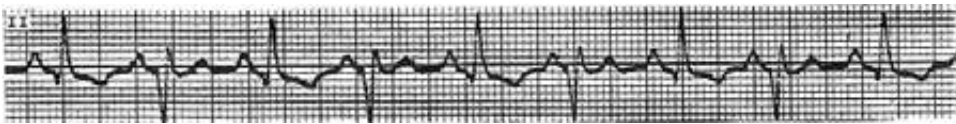
The third QRS has a taller R wave than other QRSs due to the summation of a positive P wave and the R wave



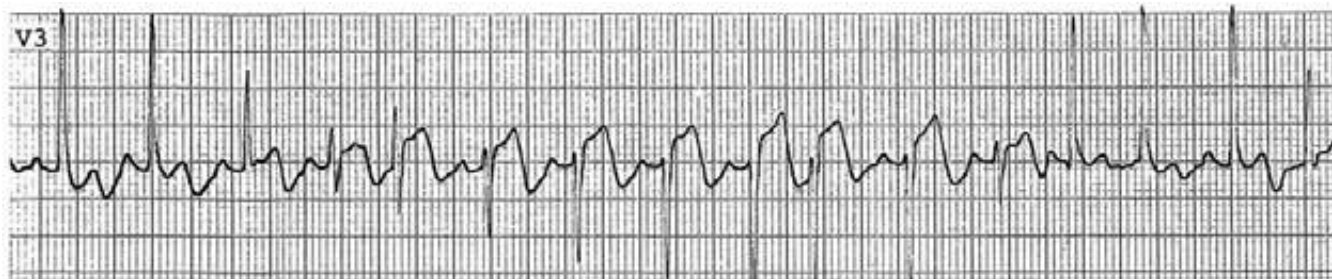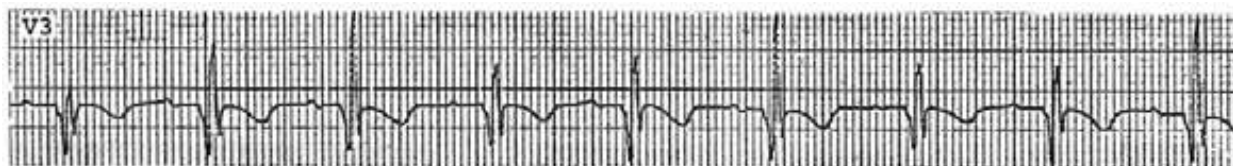
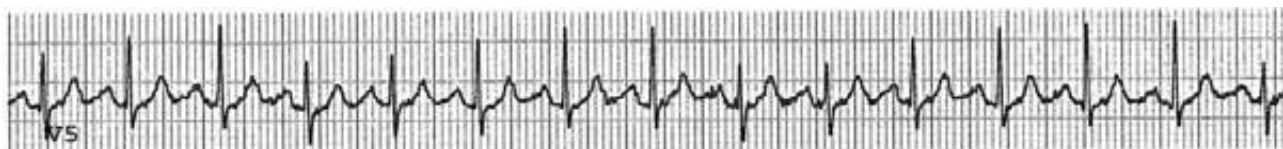
Rate dependent BBB



Ventricular bigeminy

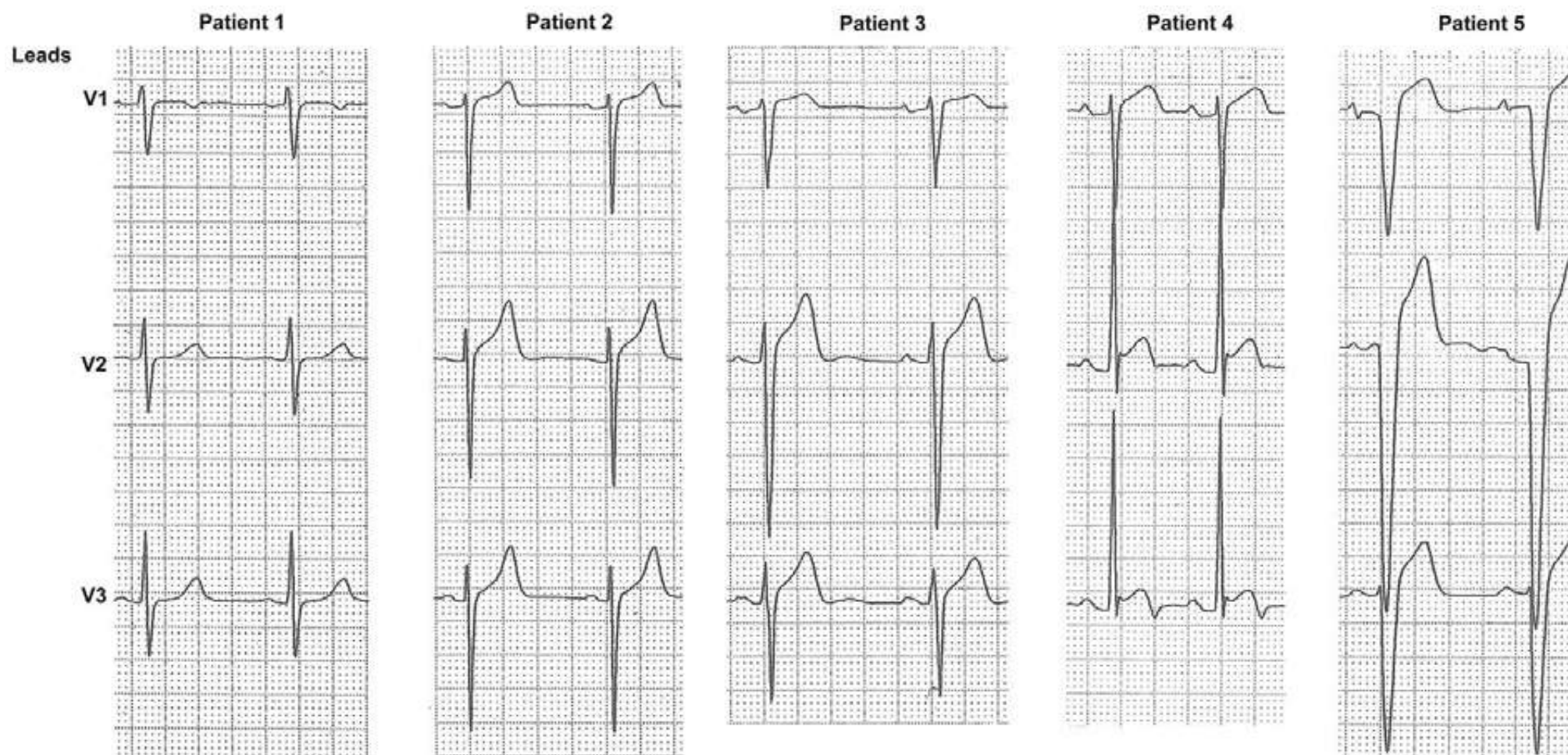


Respiratory variation in QRS axis and morphology



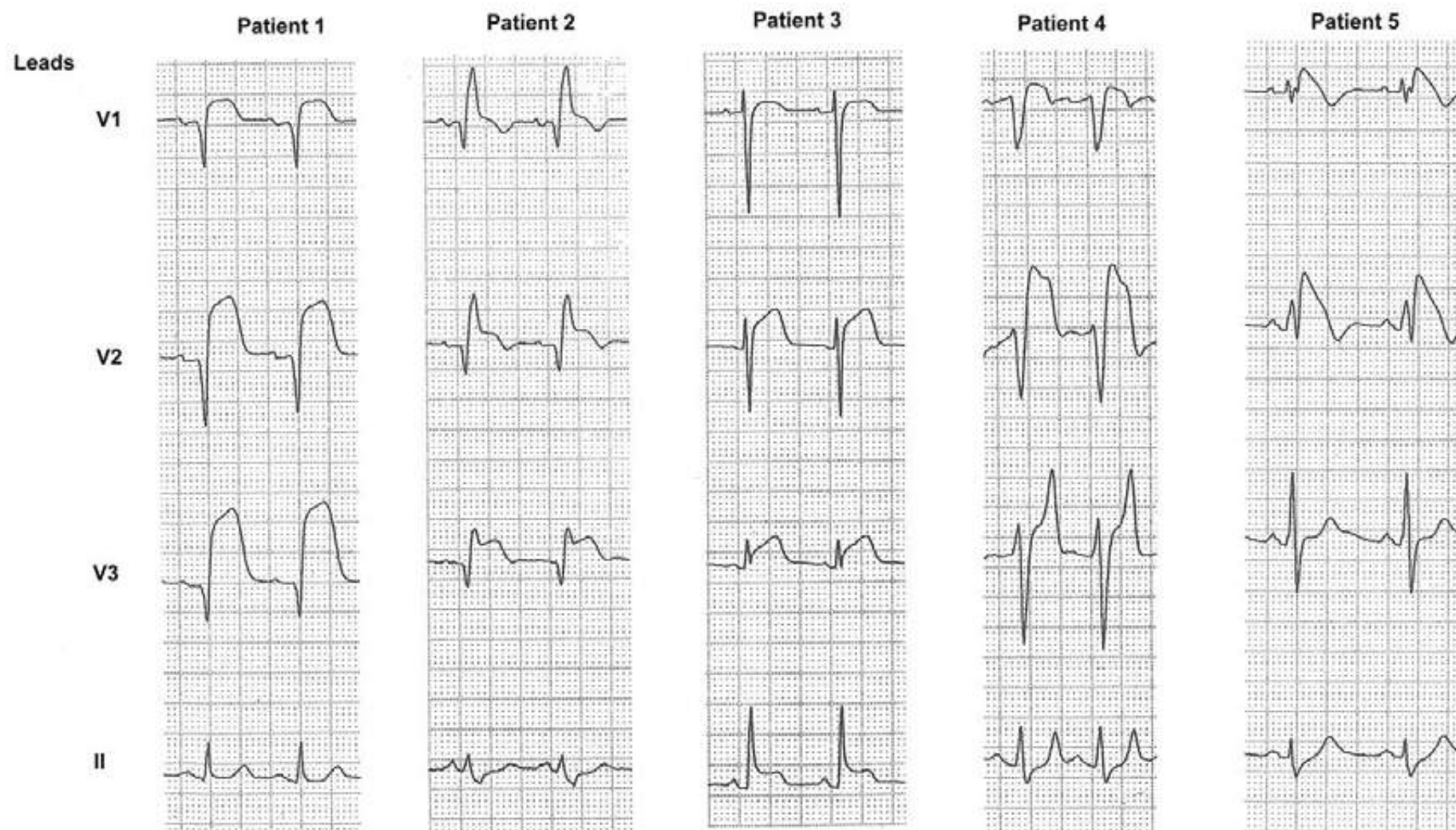


## ST-segment Elevation in V1-3 of No Primary Concern

*Patient*

- 1 No ST elevation for comparison
- 2-3 Normal ST elevation. 1-3 mmg ST elevation is present normally in 90% of the general population. Note the ST segment is concave upward.
- 4 ST elevation of normal variant. Note terminal T-wave inversion. The QT interval tends to be short.
- 5 ST elevation 2° to LBBB.

## Different Diagnosis of ST Elevation in the Right Precordial Leads



Patient	Clues
1 acute anteroseptal infarct without RBBB .....	no "rabbit ear" sticking out
2 acute anteroseptal infarct and RBBB .....	the second "rabbit ear" sticking out
3 acute pericarditis .....	only tracing with ST elevation also in lead II, indicating diffuse ST elevation and PR-segment depression
4 hyperkalemia with "pseudoinfarction" pattern .....	tall, pointed T waves in V3
5 Brugada syndrome .....	downsloping ST segment which begins from the top of the R' ending with a negative T wave. Unlike in patient 2, there is no distinct transition between the downstroke of the R' and the beginning of the ST segment



## Addendum

### How to make an Interpretation of Arrhythmia Easy, Correct, Convincing and Clinically Relevant?

At first glance, the tracing in the opposite page appears very complicated. When faced with such a tracing, our first instinct is to say “That is not for me. Give it to someone else to analyze” rather than “Give it to me. I will figure it out”. This tracing is not complicated after all!

Let’s tackle it. You quickly scan it and notice that QRSs are all narrow, many of them occur regularly, some occur with a shorter R-R interval. Let’s look for the P waves. Lead II is usually the best lead to look at not only because, among the 12 leads, P waves are most easily detectable there, but also it tells most distinctly whether the atria are conducted anterograde (upright P wave) or retrograde (inverted P wave). There are some upright P waves and inverted P waves. When it is inverted, the RP interval lengthens, indicating there is retrograde Wenckebach Phenomenon. At this point the tracing will make one say “this is turning out to be an interesting tracing”, instead of “this is a complicated tracing”.

In a regular rhythm, if there is a break in regularity, one should start the analysis from there, which will enhance the chance of arriving at the correct interpretation. There are several breaks in this tracing. Let’s start from one of them where an arrow (↓) is. The QRS 1 is narrow with no P wave in front, indicating it is an A-V junctional beat. A junctional beat has to have either an anterograde (upright) P wave in front, within or after the QRS, or retrograde (inverted) P wave in front, within or after the QRS. There is no P wave in front or after the QRS, indicating it must be within the QRS. Only thing we can’t determine yet is whether it is upright or inverted. We will come back to that later.

The beats 1-5 occur regularly at 125/min with no P wave preceding them. Thus the rhythm is accelerated junctional rhythm. The beat 2 has an upright (sinus) P wave following it. The beat 3 has an inverted (retrograde) P wave following it. This indicates that the retrograde P wave cannot occur sooner than that in this patient. Therefore the P wave that is within the QRS 1 is a sinus P wave. This also tells us that the sinus rate is 107/min. The sinus P wave falls further behind, allowing the impulse from the junction to conduct to the atria retrogradely (beat 3). This patient has retrograde conduction problem and the following two impulses (beats 4 and 5) have progressively longer RP intervals. With beat 5, the retrograde P wave occurs late enough so that, when the impulse turns around, it finds the junction and/or the ventricles recovered from refractory period and is able to conduct all the way to the ventricles, resulting in an echo beat (R6).

This echo beat resets the junctional pacemaker and the cycle repeats. An echo beat does not occur with beats 3 or 4 because the retrograde P waves occur too soon during the refractory period of the junction or ventricles. If this patient did not have retrograde conduction problem, the rhythm would have been regular accelerated junctional rhythm with 1:1 retrograde conduction to the atria with a fixed RP interval such as in beat 3.

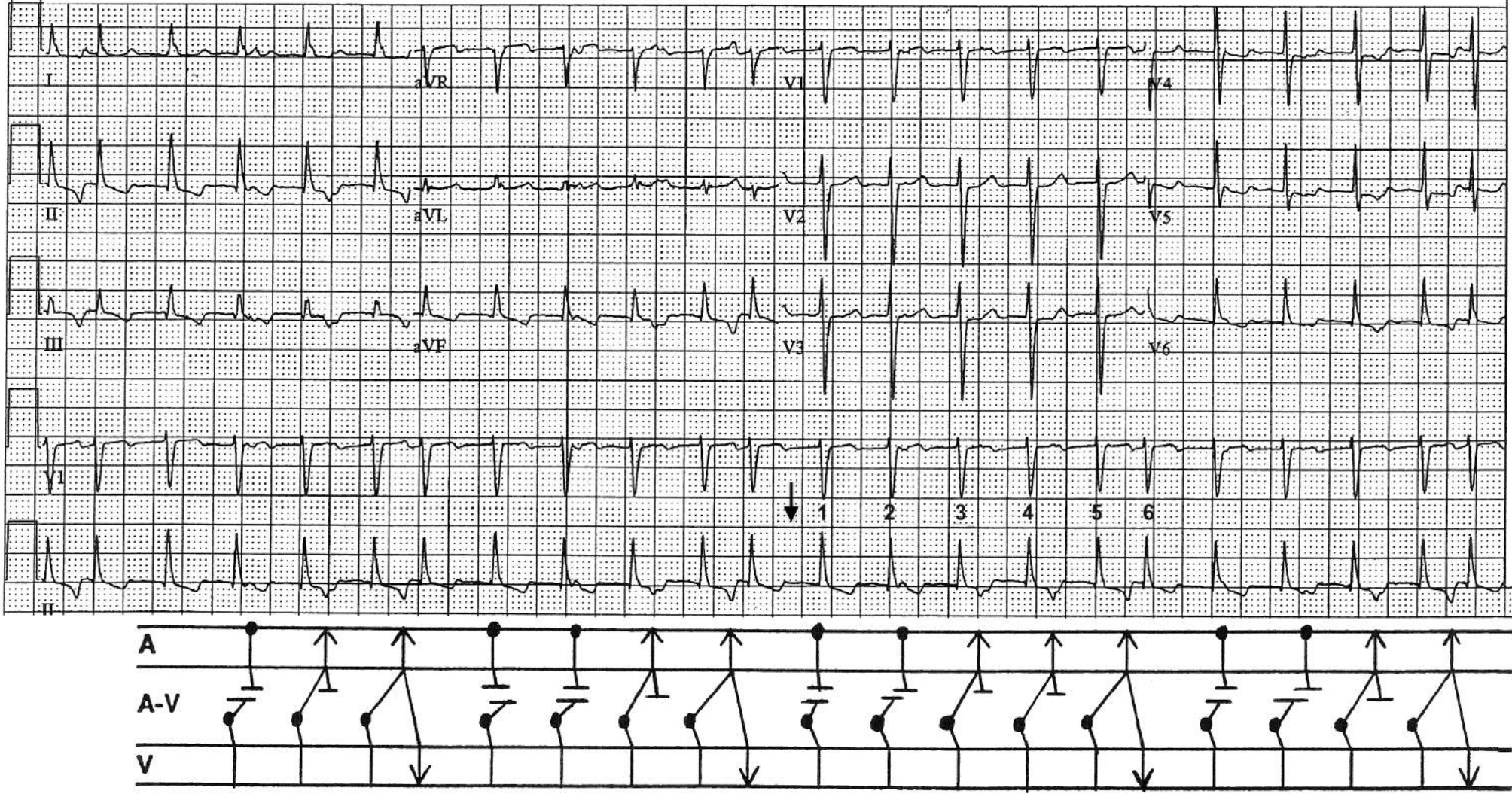
The primary ECG problem in this tracing is accelerated junctional rhythm. The rest of the phenomena (AV dissociation with beats 1 and 2, retrograde conduction, echo beats) are all secondary manifestations. What is the clinical significance of accelerated junctional rhythm? It occurs primarily in the following three settings:

1. Digitalis intoxication
2. Myocardial ischemia or infarction
3. Excess amount of catecholamines circulating, i.e., any stressful conditions

This patient is recovering from an aortic root surgery, a stressful condition. When the accelerated junctional rhythm subsided, he was left with sinus tachycardia at ~ 120/min.

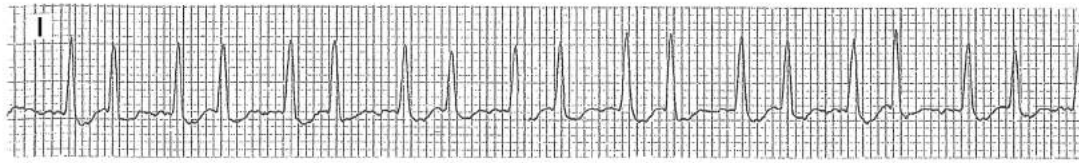
During a regular rhythm with AV dissociation, if there is a QRS that occurs with a shorter R-R interval, it is either a capture beat (the ventricles are “captured” by the sinus impulse) or an echo beat. If it is preceded by a positive P wave in lead II, it is a capture beat. If it is preceded by an inverted P wave, it is an echo beat.

A ladder diagram is useful in helping us visualize what is happening.





## A Little Rhythm Strip that Told the Whole Story

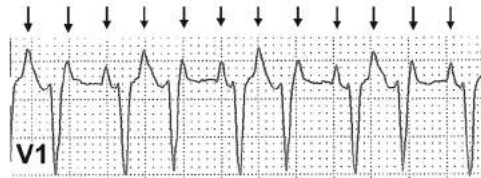


The little rhythm strip above told the whole story, i.e. what is happening and why it is happening. What is happening is atrial flutter with 3:2 AV Wenckebach phenomenon. Why it is happening is thyrotoxicosis. How could one tell that? Let's analyze the strip.

Important observations to make:

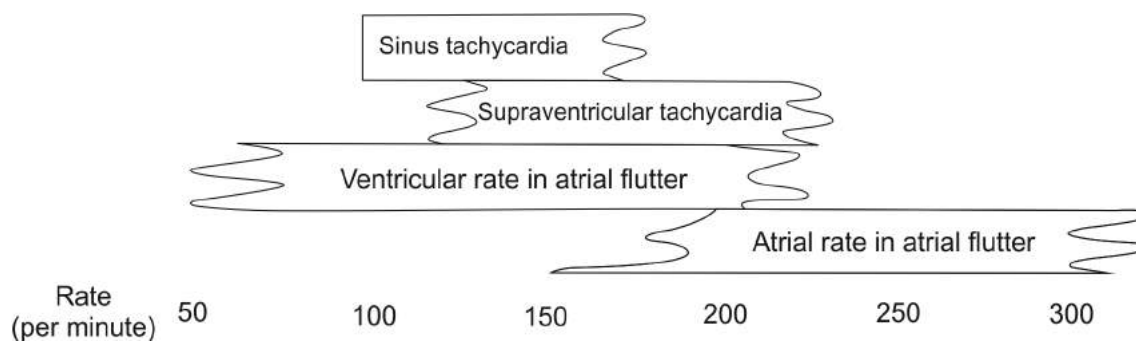
- QRS complexes are narrow
- Average heart rate is 200/min
- QRS complexes are paired
- The longer cycle is less than twice the shorter cycle

There are many causes of paired QRS complexes (see pages 292 and 293). At this heart rate, it has to be 3:2 AV conduction. The fact that the longer cycle is less than twice the shorter cycle indicates that it is type I (Wenckebach phenomenon) as demonstrated in V1 below.

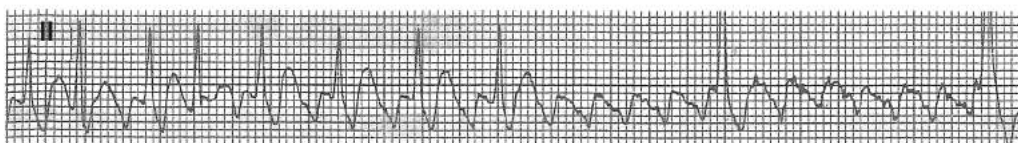


In 3:2 AV conduction, the ventricular rate of 200/min means the atrial rate is 300/min. Regular atrial rhythm at a rate close to 300/min occurs only in atrial flutter (see figure below).

Approximate Rate Range In Various regular narrow-QRS tachycardias



Indeed, adenosine proved that the underlying rhythm is atrial flutter as shown below.



Ordinarily, AV node can't conduct impulses 1:1 at 300/min, but may be able to conduct every other atrial impulse. That is why the ventricular rate in atrial flutter is ~150/min. The fact that the ventricular rate is 200/min means the AV conduction is facilitated by such things as thyroid hormone. Indeed, this patient had a visible and palpable thyromegaly and severe hyperthyroidism!

# INDEX

## A

- Aberrant conduction, 112, 113, 124, 161, 164
  - atrial flutter with 1:1 conduction and, 142, 143
  - Ashman's phenomenon, 161
  - genesis of, 112
  - varying degrees of, 162
- Accelerated
  - idioventricular rhythm, 14, 15, 111
  - junctional rhythm, 12, 13, 101, 111, 298, 299
- Accelerated AV conduction, 234
- Adenosine, effect of, 119, 138, 139, 300
- Aneurysm, ventricular, 85
- Antidromic AV reentrant tachycardia, 202
- Artifact mimicking
  - alternating bradycardia and tachycardia, 271
  - atrial flutter, 144, 145
  - ventricular tachycardia, 267–269
- Ashman's phenomenon, 124, 161
- Asystole, 114, 115, 170
- Atrial enlargement
  - left, 20
  - right, 20
- Atrial fibrillation, 10, 11, 123–128
  - AV conduction during, 126
  - aberrant conduction in, 124
  - in LBBB, 128
  - in preexcitation, 211
- Atrial flutter, 10, 11, 129–143, 275, 279, 281
  - adenosine effect in, 138, 139, 300
  - artifact simulating, 144, 145
  - slow, 140, 141
  - variable AV conduction ratio, 137
  - 1:1 AV conduction, 142, 143
  - 2:1 AV conduction, 131–135
  - 3:1 AV conduction, 136
  - 4:1 AV conduction, 130
  - with aberrant conduction, 142, 143
  - Wenckebach phenomenon, 300
- Atrial repolarization (Ta) wave, 197–199
- Atrial septal defect
  - primum, 237
  - secundum, 238
- Atrial tachycardia, 10, 11, 110, 116, 117, 155
  - Wenckebach phenomenon, 116, 117, 155
- Automaticity, 92
- AV block, 37–49
  - 1°, 38
  - 2°, 39–49
    - 2:1 AV block, 47, 283
    - 3:1 AV block, 283
    - type I (Wenckebach phenomenon), 39–44, 284
    - type II, 39, 45, 47, 284
    - high grade, 48, 49
      - adenosine causing, 139
      - during Swan–Ganz catheterization in LBBB, 261
      - in bifascicular block, 48, 49
  - 3°, 49
    - acute MI and, 64, 65
    - in atrial fibrillation, 49, 127, 283
    - junctional escape, 49, 283
    - ventricular escape, 49
  - pseudo AV block, 46
    - concealed junctional premature beats and, 214–221, 284
    - concealed retrograde conduction from PVCs and, 153
- AV dissociation, 93, 95, 97, 98, 100–108, 282
- AV junctional rhythm, 12, 13
  - AV dissociation in (See AV dissociation)
  - accelerated, 12, 13, 101–108, 111, 292
  - bigeminy, 292
  - escape, 12, 13, 95–98, 100, 282



premature beat, 16, 17, 292  
re-entrant (AVNRT), 12, 13  
Wenckebach phenomenon, 127  
tachycardia, 12, 13, 127  
1:1 retrograde conduction to atria, 13, 111, 282

AV node, the role in SVTs, 118

Axis, QRS, 7

left axis deviation, 7, 33  
right axis deviation, 7, 26–29, 34

## B

---

Bidirectional tachycardia, 239, 294

Bifascicular block

high grade AV block, 48  
RBBB and left anterior fascicular block, 35  
RBBB and left posterior fascicular block, 36

Bradycardia, sinus, 8, 9, 282

Brugada syndrome, 229, 297

acquired Brugada ECG pattern from hyperkalemia, 176–179, 297

Bundle branch block, 30

left, 30, 32  
rate dependent, 160, 295  
right, 30, 31

Bundle of Kent, 200

## C

---

Calibration, 1

Calibration mark, 1, 18

Capture beats,

atrial, 104, 105, 106  
ventricular, 95, 101, 106, 107

Cardiac arrest, 114, 115, 106, 170

Cardioinhibitory response, 240

Compensatory pause after PVC

full, 150–152  
less than full, 150–153

Concealed conduction, 153, 214–221, 284

pseudo AV block, 153, 215–221, 284

Conduction system, 92

Coronary artery spasm, 228

Cor pulmonale, acute, 235, 236

## D

---

Delta wave, 200, 213

true and pseudo, 212, 213

Dextrocardia, 241

Differential diagnosis of

bigeminal rhythm (paired QRS complexes), 292, 293  
changing QRS morphology or axis, 294, 295  
narrow QRS bradycardia, 282, 283  
narrow QRS tachycardia, 273–281  
pauses, 284  
ST elevation, 222–233, 296, 297  
tall R waves in the right precordial leads, 285–291

Digitalis effect on ST segment, 242

Digitalis intoxication, 110, 154, 155

Dual AV nodal pathway, 97, 99, 100

Duchenne muscular dystrophy, 243

## E

---

Early repolarization pattern as a normal variant, 225

Early transition, 244

Ebstein's anomaly, 245

Echo (reciprocal) beat

atrial, 97, 99, 100  
ventricular, 99, 100

Einthoven triangle, 3

Electrical alternans during

atrial flutter, 248  
sinus rhythm, 246, 294  
SVT, 247, 294  
VT, 249, 294

Electrocardiogram

intervals, 4  
leads  
orientation, 1, 3  
placement, 1, 3  
mechanics of recording, 1  
normal, 18  
segments, 4  
systematic approach to the interpretation of, 4  
waves, 4, 6

## Electronic pacemaker, 190–195

atrial pacing, 190

AV sequential pacing, 194

demand mode ventricular pacing

by inhibited response, 191

by triggered response, 192

failure to capture, 180, 193

failure to sense, 193

fixed mode ventricular pacing, 191

natural demand pacemaker, 92, 95–98

pacemaker induced ventricular arrhythmias, 194, 195

pacemaker mediated tachycardia (endless loop tachycardia), 195

pacemaker syndrome, 193

P triggered ventricular pacing, 190

1:1 VA conduction, 193

Entrance block, 126, 127

Escape rhythm or beats

junctional, 13, 49, 95–98, 282, 283, 293

ventricular, 15, 49

Exit block, 126, 127, 293

## F

Fascicular block

bifascicular, 35

causing high grade AV block, 48

RBBB and left anterior fascicular block, 35

RBBB and left posterior fascicular block, 36

left anterior, 33

left posterior, 34

Fibrillation

atrial, 11, 123–128

ventricular, 15, 170

Flutter

atrial: see atrial flutter

ventricular, 170

Fusion beats

atrial, 105, 220, 221, 284

ventricular, 101

## G

Glossary of cardiac rhythms, 8–17

## H

Heart rate estimation, 5

How to make interpretation of arrhythmia easy, 298, 299

Hypercalcemia, 183

Hyperkalemia, 171–181

acquired Brugada ECG pattern, 176–179

pacemaker failure to capture, 180

pseudoinfarction pattern, 177–179

sign waves, 181

sinoventricular rhythm in, 178

Hyperkalemia and hypocalcemia, 185

Hypertrophic cardiomyopathy, 250

Hypocalcemia, 184

Hypokalemia, 182

Hypothermia, 251, 252

## I

Interference AV dissociation, 93, 95, 97, 98, 101–108, 182

Intervals, 4

Isorhythmic AV dissociation, 107

## J

J (Osborn) wave in hypothermia, 251, 252

## L

Late transition, 253

Leads

orientation, 1, 3

placement, 1, 3

Low atrial rhythm, 10, 11

Low QRS voltage, 255

## M

Mechanics of recording ECG, 1

“Memory” T wave, 256

“Metabolic” ST elevation, 233

Mitral stenosis, 257

Multifocal atrial tachycardia, 10, 11, 125, 146–149

intraatrial electrogram, 147

simulating atrial fibrillation, 149



## Myocardial infarction (MI), 50–90

- anterior, 52, 297
  - old, 68
  - with and without RBBB, 72, 73, 297
- anterior and inferior, old, 68
- apical, 51, 61
- complete (3°) AV block in, 64, 65
- evolution of ST-T changes, 50
- high lateral, 51, 57, 58, 69
- inferior, 51, 53, 56, 59, 60, 62
  - old, 59, 60, 68
  - with RBBB, 74
- Infero-posterior, 67, 287
- Infero-postero-lateral, 54, 55, 64
- left anterior fascicular block masking inferior MI, 71
- left axis deviation with or without inferior MI, 70
- LBBB and
  - anterior, 75
  - anterolateral, 78
  - anteroseptal, 81
  - inferior, 76, 77, 80
  - posterior, 79
- non-ST elevation (subendocardial) MI, 50, 86
- posterior, 66, 287, 290
  - old, 67
- prediction of culprit vessel, 51
- revealed by QRSs of
  - accelerated idioventricular rhythm, 89
  - paced beats, 90
  - PVCs, 87
  - ventricular tachycardia, 88
- RBBB and, 72–74
- RV, 51, 62, 64, 65
- ST segment axis shift in MI, 51
- Subendocardial (non-ST elevation) MI, 50, 86

## N

---

- Natural demand pacemaker, 92, 96
- Neurogenic T wave changes, 260
- Nonspecific ST-T changes, 258
- Normal tracing, 18, 19

## O

---

- Orthodromic AV reentrant tachycardia, 202
- Osborn (J) wave in hypothermia, 251, 252

## P

---

- P wave abnormalities, 20
- Parasystole, ventricular, 191
- Pericarditis, 227
- Poor R wave progression, 259
- P-QRS relationships in
  - junctional beats or rhythm, 93, 95, 97–108
  - ventricular beats or rhythm, 93, 99, 101, 103, 150
- Pre-excitation, ventricular, 200–213
  - atrial fibrillation, 211
  - intermittent, 208–210, 213
  - simulating
    - anteroseptal and inferior MI, 204
    - electrical alternans, 210, 294
    - inferior MI, 205
    - LBBB and inferior MI, 207
    - postero-lateral MI, 206, 290
  - true and pseudo delta waves, 212, 213
  - typical example of, 203
  - various arrhythmias in, 202
- Premature beats
  - atrial, 16, 17, 112–115, 292
    - aberrant conduction, 112–114, 292
    - non-conducted, 112–115, 282, 284, 293
  - junctional, 16, 17, 214–221, 292
  - ventricular, 16, 17, 150–160
    - AV dissociation, 150, 151
    - bigeminy, 170, 292
    - causing cardiac arrest, 170
    - causing pseudo Wenckebach phenomenon, 153
    - compensatory pause, 150–152
    - interpolated, 109, 150
    - P-QRS relationships in, 150
    - retrograde conduction to atria, 150–152
    - usefulness of PVCs by revealing
      - atrial flutter waves, 158
      - intermittent LBBB, 160

myocardial infarction, 87

P wave, 155–157, 159

VA conduction, 150–152, 166

Prinzmetal's angina, 228

Pseudo AV block, 46, 153, 215–221, 284

Pulmonary embolism, 230, 235, 236

P wave abnormalities, 20

atrial fusion, 105, 220, 221

biatrial enlargement, 20

left atrial enlargement, 20

low atrial rhythm, 20

retrograde P wave, 11–13, 20, 93, 95, 97, 99, 100, 103, 105, 106, 111, 166

right atrial enlargement, 20

## Q

QRS

axis, 7

changing axis or morphology from

bidirectional tachycardia, 239, 294

electrical alternans, 246–249, 294

preexcitation of alternate beats, 209, 210, 294

respiration, 270, 294, 295

summation with

p waves, 98, 295

flutter waves, 295

left axis deviation, 7, 33

right axis deviation, 7, 26–29, 34

proper labeling of the component waves, 6

vectorial concept of, 2

Q-T interval

long, 169, 184, 185, 254, 260

short, 183

Q waves, normal septal, 18, 19, 91

## R

Rate

estimation, 5

ranges in various rhythms, 300

Reciprocal (echo) beat

atrial, 97, 99, 100

ventricular, 99, 100

Reentrant tachycardia

AV, 202

AV nodal, 12, 13

sinus, 9

Refractory period, 92–95, 97

Respiratory variation in QRS height or axis, 270, 294, 295

Retrograde conduction to atria

during junctional rhythm, 13, 20, 93, 95, 99, 100, 105, 106, 111

during paced rhythm, 111

during ventricular rhythm, 93, 99, 111, 150–152, 166

Reversed arm leads, 291

Reversed precordial leads, 288, 289, 291

Rhythm, glossary of, 8–17

Rhythmstrip that told the whole story, 300

Right-sided precordial leads, 62, 63, 65

## S

SA block

type I, 186, 293

type II, 187, 284

S<sub>1</sub>Q<sub>3</sub>T<sub>3</sub> pattern, 235

ST elevation,

following D.C. shock, 232

hyperkalemia, 176–179, 297

in conditions other than acute MI, 222–233, 296, 297

LBBB, 32, 75–79, 81, 296

LVH, 22–25

metabolic, 233

MI, 50–90, 297

normal, 222–224, 296

normal variant, 225, 226, 296

pericarditis, 227, 297

pulmonary emboli, 230

Segments, 4

Sick sinus syndrome (see also sinus nodal dysfunction), 188, 189

Signal on, signal off, 272

Sinoventricular rhythm in hyperkalemia, 178

Sinus arrhythmia, 8, 9

Sinus bradycardia, 8, 9, 282

Sinus node dysfunction

alternating bradycardia-tachycardia, 189

SA block, type I, 186, 293

SA block, type II, 187, 284

Sinus node reentrant tachycardia, 8, 9

Sinus tachycardia, 8, 9, 273, 274, 277

ST elevation or depression mimicking widened QRS, 82–84

ST elevation with inverted T waves as “the other” normal variant, 226

Stress cardiomyopathy, 231, 260



Stress electrocardiography, 196–199  
ST segment changes of digitalis effect, 242  
ST-T changes, nonspecific, 258  
Supraventricular tachycardia, 12, 13, 120–122, 278, 280  
    electrical alternans in, 247  
    ST depression in, 122

## T

---

T wave alternans, 262  
T wave, tall  
    hyperacute ischemia, 171  
    hyperkalemia, 171–180  
    normal variant, 171  
Ta wave, 197, 198  
    and ST depression, 199  
    and ST elevation, 197  
Tachycardia  
    atrial  
        1:1 conduction, 10, 11, 116  
        2:1 conduction, 116  
        Wenckebach phenomenon, 116, 117  
    AV junctional, 12, 13, 273  
    sinus, 8, 9, 273, 274, 277  
    supraventricular, see Supraventricular tachycardia  
    ventricular, see Ventricular tachycardia  
Threshold potential, 92  
Torsade de pointes, 14, 15, 169  
Transplanted heart, 263  
Tricyclic overdose, 264

## U

---

U wave  
    mimicking 1° AV block, 266  
    prominent, 265, 266

## V

---

Vectorial concept of the QRS, 2  
Vector loop, genesis of, 2  
Ventricular aneurysm, 85  
Ventricular arrhythmias  
    escape, 14, 15, 49  
    fibrillation, 14, 15, 170

flutter, 14, 15, 170  
premature beat, 16, 17, 150–160, 170  
    (see also premature beats, ventricular)  
tachycardia, 15, 163–170  
    A-V dissociation in, 166  
    A-V relationship during, 166  
    bidirectional, 239, 294  
    capture beat, 101  
    concordant  
        Positively, 167  
        Negatively, 168  
    fusion beat, 101  
    monomorphic, 163–168  
    polymorphic, 165  
    torsade de pointes, 14, 15, 169  
    V-A conduction in  
        1:1, 166  
        2:1, 166  
        retrograde Wenckebach phenomenon, 166

Ventricular hypertrophy  
    biventricular, 29  
    left, 21–25  
        with and without anteroseptal MI, 24, 25  
    right, 26  
        due to COPD, 26, 28  
        not due to COPD, 26, 27, 286

Ventriculophasic sinus arrhythmia, 109, 110

## W

---

Wandering atrial pacemaker, 10, 11  
Waves, 4, 6  
Wenckebach phenomenon, 39–44, 284, 293  
    in atrial flutter, 300  
    in atrial tachycardia, 116, 117, 155  
    in junctional tachycardia, 127  
    pseudo from  
        concealed junctional premature beats, 218, 219  
        concealed retrograde conduction from PVCs, 153  
    retrograde from junctional beats, 298, 299  
    retrograde V-A, 166  
    SA, 186, 293  
Wolf-Parkinson-White syndrome, 200–213  
    (see also pre-excitation, ventricular)